



**PATIENT**

Puppy Kahlua Graham

**SPECIES**

Canine

**BREED**

Labrador Mix

**SEX**

Spayed Female

**AGE**

7 years

**WEIGHT**

**INTERPRETED BY**

Eric Lindquist, DMV  
DABVP, Cert. IVUSS

**IMAGING  
PERFORMED BY**

Shari Reffi, CVT

**HOSPITAL NAME**

Rockaway AH

**REFERRING VET**

Dr. Maniar

**INVOICE**

98109

**DATE**

4/6/22

**PRESENTING CLINICAL SIGNS**

History: Vomiting-post splenic torsion (splenectomy) 3/19/2022

**ULTRASONOGRAPHIC EXAMINATION OF THE ABDOMEN**

**Urinary System**

The **urinary bladder**, trigone, and pelvic urethra presented normal thicknesses and normal tone. The ureters were not visible which is normal. No uroliths or sediment were visualized and anechoic urine was present. No evidence of inflammatory or neoplastic changes was noted. Ureteral papillae were normal.

The **kidneys** revealed normal size and structure, corticomedullary definition and ratio for this age. The cortices presented largely uniform texture with normal echogenic relationship to liver and spleen. Medullary structure differed distinctly from the cortex and no evidence of pelvic dilation was present. The capsules were acceptably uniform without significant irregularities. The left kidney measured 6.6 cm. The right kidney measured 6.83 cm.

**Adrenal Glands**

Both **adrenal glands** were visualized and recognized as having normal shape, size, position and echogenicity for this breed. The phrenic vasculature, glandular echogenicity and detail were unremarkable. Capsule, cortex, and medullary definition were normal for this age patient. The right adrenal gland measured 2.25 x 1.1 cm at the cranial pole and 0.81 cm at the caudal pole. The left adrenal gland measured 2.15 x 0.45 cm at the cranial pole and 0.45 cm at the caudal pole.

**Spleen**

The **spleen** was not visualized as it was previously removed. The region of the splenic fossa revealed approximately 5.0 cm of mixed, hypoechoic and hyperechoic parenchymal and mesenteric changes. This is slightly excessive for 3 weeks post surgery. This should be monitored. If the hypoechoic changes remain then FNA of that region is recommended to ensure an underlying neoplasia is not present.

**Liver**

The **liver** images submitted revealed subjectively normal liver size, contour, and structure. Parenchymal echogenicity was naturally coarse and hypoechoic to the spleen. Vascular and biliary tracts were of normal volume with no evidence of congestion. The gallbladder presented acceptably thin walls with primarily anechoic content. The cystic and common bile ducts were normal. No pathological hepatic lymphadenopathy was evident. No overt structural evidence of inflammatory, infiltrative or regenerative pathology was evident.

**Gastrointestinal**

Examination of the **gastrointestinal tract** revealed a stomach and intestine free of stasis, of normal wall thickness, acceptable curvilinear mural detail, and peristaltic activity. Small and large intestine



**PATIENT**

Puppy Kahlua Graham

demonstrated normal luminal chyme and stool consistency respectively. No obstructive or overt infiltrative disease was noted. No associated abnormal lymphatic activity was noted.

**SPECIES**

Canine

**Pancreas**

The base and limbs of the **pancreas** were observed to be largely isoechoic to surrounding omental fat. Pancreatic duct and capsular contour were acceptably normal and parenchyma respected normal curvilinear patterns. No overt evidence of active inflammatory or neoplastic disease was noted.

**BREED**

Labrador Mix

**ULTRASONOGRAPHIC FINDINGS**

**SEX**

Spayed Female

Stable abdomen with heterogenous tissue and mesenteric changes in the splenic fossa.

**INTERPRETATION OF THE FINDINGS & FURTHER RECOMMENDATIONS**

**AGE**

7 years

The changes in the splenic fossa should be monitored. Palpation of the region of the region of the splenic fossa is recommended to assess for any discomfort in that region. A recheck sonogram is recommended in 2 weeks. Broad spectrum antibiotics are recommended until then.

**WEIGHT**

**INTERPRETED BY**

Eric Lindquist, DMV  
DABVP, Cert. IVUSS

**IMAGING PERFORMED BY**

Shari Reffi, CVT

**HOSPITAL NAME**

Rockaway AH

**REFERRING VET**

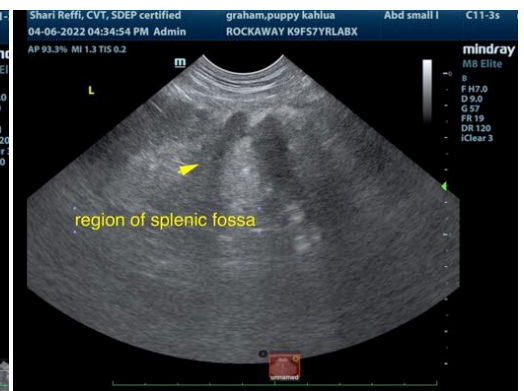
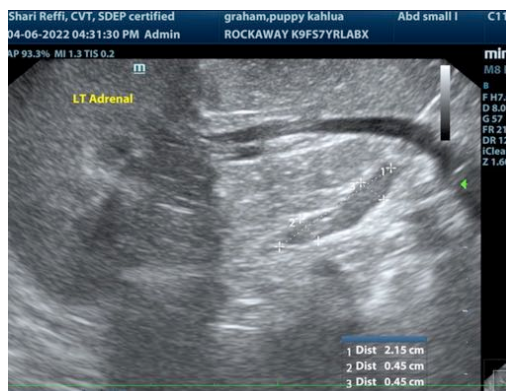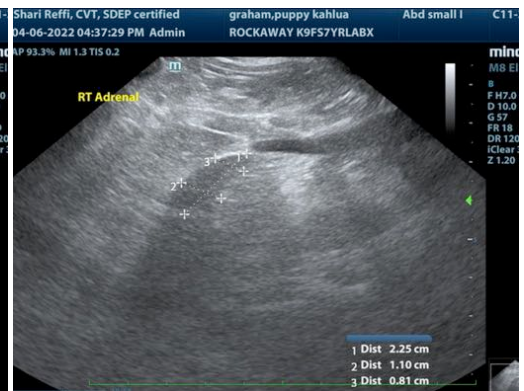
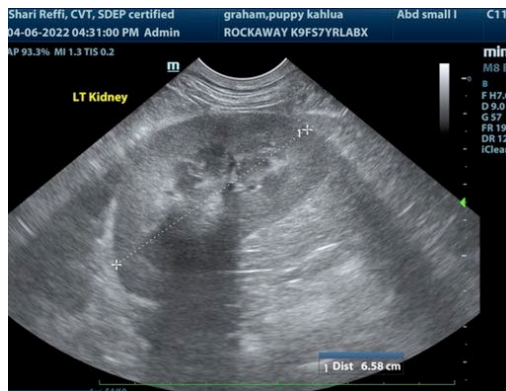
Dr. Maniar

**INVOICE**

98109

**DATE**

4/6/22





**PATIENT**

Puppy Kahlua Graham

**SPECIES**

Canine

**BREED**

Labrador Mix

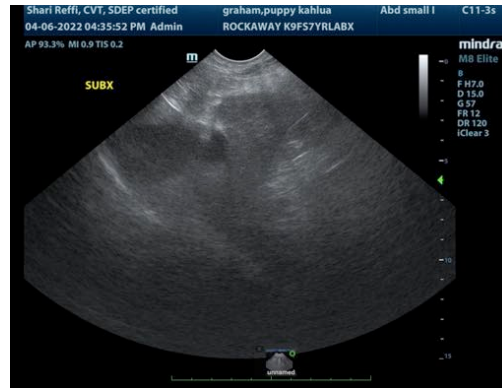
**SEX**

Spayed Female

**AGE**

7 years

**WEIGHT**



The information and recommendations provided are based on the images presented by the referring veterinarian/sonographer. No evaluation can be communicated regarding pathology that was not visible in the image/video clips provided.

Thank you for this referral. If the clinical or image interpretation does not parallel your findings or if I can be of any further assistance please contact me.

**Eric Lindquist**, DMV, DABVP, Cert. IVUSS, CEO of SonoPath.com  
Info@SonoPath.com

**INTERPRETED BY**

Eric Lindquist, DMV  
DABVP, Cert. IVUSS

**IMAGING PERFORMED BY**

Shari Reffi, CVT

**HOSPITAL NAME**

Rockaway AH

**REFERRING VET**

Dr. Maniar

**INVOICE**

98109

**DATE**

4/6/22