



PATIENT

Linda Zaldana

SPECIES

Feline

BREED

Domestic Shorthair

SEX

Spayed Female

AGE

11 years

WEIGHT

7.6 lbs

INTERPRETED BY

Eric Lindquist, DMV,
DABVP, Cert. IVUSS,
CEO of SonoPath.com

**IMAGING
PERFORMED BY**

Kelly Vazquez, CVT

HOSPITAL NAME

Animal General on
Hudson

REFERRING VET

Dr. Freedman

INVOICE

98092

DATE

4/6/22

PRESENTING CLINICAL SIGNS

History: Patient with previous history of IBD/GI pattern on ultrasound performed in 2019, presents for vomiting and losing weight.
Abnormal PE/Chem/CBC/UA Results: 12/21 - EOS 4095, monos 975, neuts 11310.

ULTRASONOGRAPHIC EXAMINATION OF THE ABDOMEN

Urinary System

The **urinary bladder**, trigone, and pelvic urethra presented normal thicknesses and normal tone. The ureters were not visible which is normal. No uroliths or sediment were visualized and anechoic urine was present. No evidence of inflammatory or neoplastic changes was noted. Ureteral papillae were normal.

The **kidneys** revealed normal size and structure, corticomedullary definition and ratio for this age. The cortices presented largely uniform texture with normal echogenic relationship to liver and spleen. Medullary structure differed distinctly from the cortex and no evidence of pelvic dilation was present. The capsules were acceptably uniform without significant irregularities. The left kidney measured 3.56 cm. The right kidney measured 4.11 cm.

Adrenal Glands

Both **adrenal glands** were visualized and recognized as having normal shape, size, position and echogenicity for this breed. The phrenic vasculature, glandular echogenicity and detail were unremarkable. Capsule, cortex, and medullary definition were normal for this age patient. The left adrenal gland measured 0.61 cm. The right adrenal gland measured 0.4 cm.

Spleen

The **spleen** presented a smooth homogeneous parenchyma hyperechoic to liver and renal cortical parenchyma. The capsule was smooth without noticeable expansion or deviation from within the spleen or adjacent pathology. The splenic vasculature demonstrated normal volume without signs of congestion or thrombosis. No sonographic evidence of acute or chronic inflammatory, neoplastic, or infarctual changes was noted. The spleen measured 0.8 cm.

Liver

The **liver** images submitted revealed subjectively normal liver size, contour, and structure. Parenchymal echogenicity was naturally coarse and hypoechoic to the spleen. Vascular and biliary tracts were of normal volume with no evidence of congestion. The gallbladder presented acceptably thin walls with primarily anechoic content. The cystic and common bile ducts were normal. No pathological hepatic lymphadenopathy was evident. No overt structural evidence of inflammatory, infiltrative or regenerative pathology was evident.



PATIENT

Gastrointestinal

Linda Zaldana

Retention of ingesta or more likely hairball accumulation was noted in the **stomach**. Variable intestinal thickening was noted in this patient with areas of hypertrophied muscularis. This is similar to the previous sonogram. The mesenteric lymph node was reactive and measured 0.35 cm.

SPECIES

Feline

Pancreas

BREED

Domestic Shorthair

The base and limbs of the **pancreas** were observed to be largely isoechoic to surrounding omental fat. Some parenchymal remodeling, however, with mild deviation from curvilinear normalcy was observed. Pancreatic duct and capsular irregularities were present consistent with age related changes. If pain upon imaging (+ Murphy sign) was present or if the patient is focally painful in subxiphoid palpation then low-grade smoldering chronic pancreatitis should be suspected.

SEX

Spayed Female

ULTRASONOGRAPHIC FINDINGS

AGE

11 years

Variable intestinal thickening with hairball density in the stomach, likely inflammatory bowel.

History of pancreatitis is likely.

WEIGHT

7.6 lbs

INTERPRETATION OF THE FINDINGS & FURTHER RECOMMENDATIONS

Full thickness intestinal biopsies would be necessary for further definition. However, neoplastic criteria is not met. Hairball treatment, diet change to a hydrolyzed diet if not already being utilized would all be indicated. Anti-parasitic protocol is also warranted.

INTERPRETED BY

Eric Lindquist, DMV,
DABVP, Cert. IVUSS,
CEO of SonoPath.com

IMAGING PERFORMED BY

Kelly Vazquez, CVT

HOSPITAL NAME

Animal General on Hudson

REFERRING VET

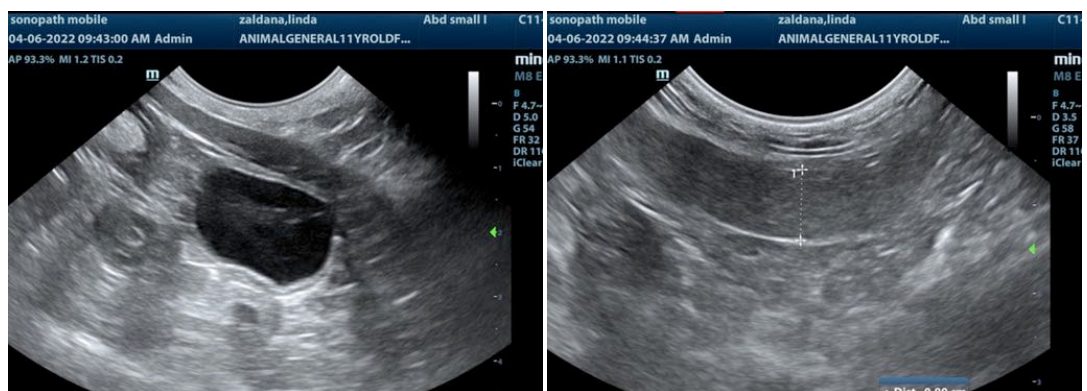
Dr. Freedman

INVOICE

98092

DATE

4/6/22





PATIENT

Linda Zaldana

SPECIES

Feline

BREED

Domestic Shorthair

SEX

Spayed Female

AGE

11 years

WEIGHT

7.6 lbs

INTERPRETED BY

Eric Lindquist, DMV,
DABVP, Cert. IVUSS,
CEO of SonoPath.com

IMAGING PERFORMED BY

Kelly Vazquez, CVT

HOSPITAL NAME

Animal General on
Hudson

REFERRING VET

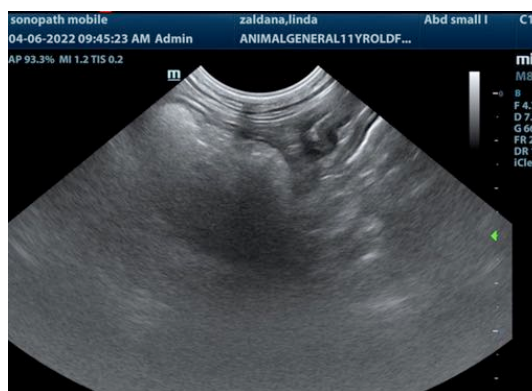
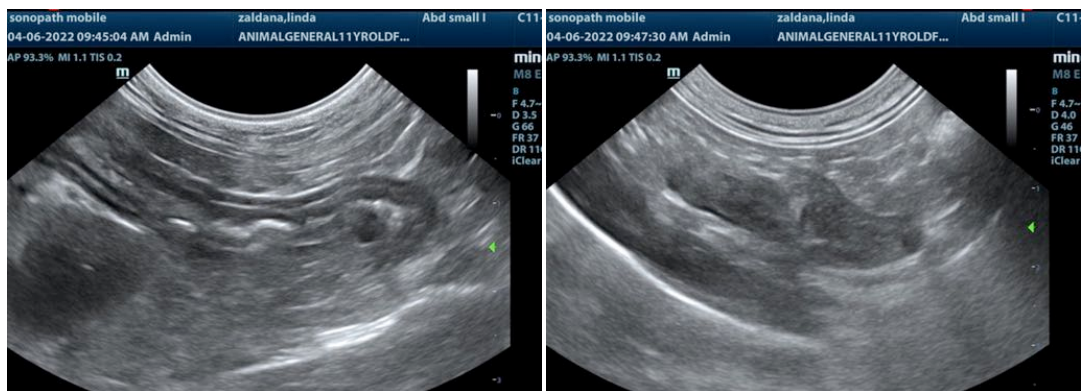
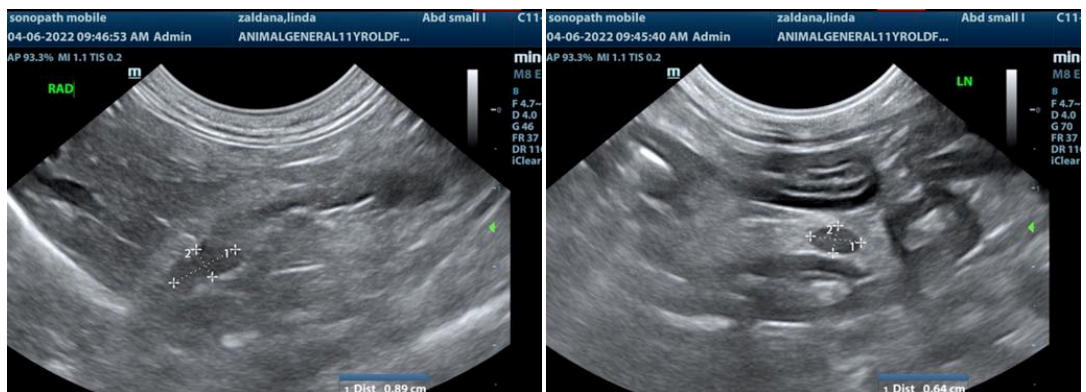
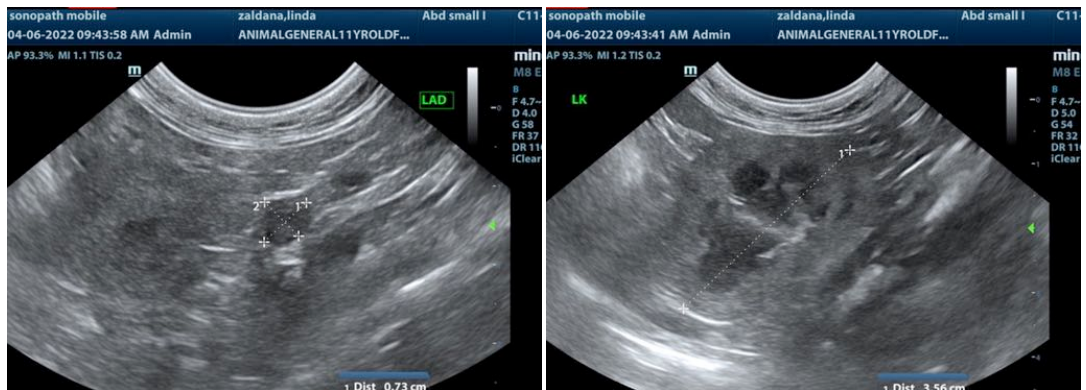
Dr. Freedman

INVOICE

98092

DATE

4/6/22





PATIENT

Linda Zaldana

The information and recommendations provided are based on the images presented by the referring veterinarian/sonographer. No evaluation can be communicated regarding pathology that was not visible in the image/video clips provided.

SPECIES

Feline

Thank you for this referral. If the clinical or image interpretation does not parallel your findings or if I can be of any further assistance please contact me.

BREED

Domestic Shorthair

Eric Lindquist, DMV, DABVP, Cert. IVUSS, CEO of SonoPath.com

Info@SonoPath.com

SEX

Spayed Female

AGE

11 years

WEIGHT

7.6 lbs

INTERPRETED BY

**Eric Lindquist, DMV,
DABVP, Cert. IVUSS,
CEO of SonoPath.com**

**IMAGING
PERFORMED BY**

Kelly Vazquez, CVT

HOSPITAL NAME

Animal General on
Hudson

REFERRING VET

Dr. Freedman

INVOICE

98092

DATE

4/6/22