



PATIENT

Pudding Xiong

SPECIES

Canine

BREED

Pomeranian

SEX

Neutered Male

AGE

6 Years

WEIGHT

6

INTERPRETED BY

Eric Lindquist, DMV,
DABVP (CFM), Cert.
IVUSS

IMAGING PERFORMED BY

Dr. Shen Li

HOSPITAL NAME

Dr. Shen Li Veterinary
Service

REFERRING VET

Dr. Shen Li

INVOICE

74218

DATE

4/5/26

PRESENTING CLINICAL SIGNS

Healthy routine check.

Abnormal PE/Chem/CBC/UA Results: PE normal Historical slight progressively low sodium The rest comprehensive panel including t4 parasite screening cancer screening normal

ULTRASONOGRAPHIC EXAMINATION OF THE ABDOMEN

Urinary System

The **urinary bladder**, trigone, and pelvic urethra presented normal thicknesses and normal tone. The ureters were not visible which is normal. No uroliths or sediment were visualized and anechoic urine was present. No evidence of inflammatory or neoplastic changes were noted. Ureteral papillae were normal.

The residual prostate measured 1.1 cm.

The **kidneys** revealed normal size and structure, corticomedullary definition and ratio for this age. The cortices presented largely uniform texture with normal echogenic relationship to liver and spleen. Medullary structure differed distinctly from the cortex and no evidence of pelvic dilation was present. The capsules were acceptably uniform without significant irregularities. Right kidney measured 3.5 cm. Left kidney measured 3.3 cm.

Adrenal Glands

The **left adrenal gland** was visualized and recognized as having normal shape, size, position and echogenicity for this breed. The phrenic vasculature, glandular echogenicity and detail were unremarkable. Capsule, cortex, and medullary definition were normal for this age patient. Left adrenal gland measured 0.40 cm.

The region of the **right adrenal gland** was imaged, no evident pathology.

Spleen

The **spleen** presented a smooth homogeneous parenchyma hyperechoic to liver and renal cortical parenchyma. The capsule was smooth without noticeable expansion or deviation from within the spleen or adjacent pathology. The splenic vasculature demonstrated normal volume without signs of congestion or thrombosis. No sonographic evidence of acute or chronic inflammatory, neoplastic, or infarctual changes were noted.

Liver

The **liver** images submitted revealed subjectively normal liver size, contour, and structure. Parenchymal echogenicity was naturally coarse and hypoechoic to the spleen. Vascular and biliary tracts were of normal volume with no evidence of congestion. The gallbladder presented acceptably thin walls with primarily anechoic content. The cystic and common bile ducts were normal. No pathological hepatic lymphadenopathy was evident. No overt structural evidence of inflammatory, infiltrative or regenerative pathology was evident.

Gastrointestinal

The **stomach** revealed progressively shadowing luminal material and chyme. The shadowing structure measured 1.8 cm. The small intestine and colon were unremarkable.



PATIENT

Pudding Xiong

SPECIES

Canine

BREED

Pomeranian

SEX

Neutered Male

AGE

6 Years

WEIGHT

6

INTERPRETED BY

Eric Lindquist, DMV,
DABVP (CFM), Cert.
IVUSS

IMAGING PERFORMED BY

Dr. Shen Li

HOSPITAL NAME

Dr. Shen Li Veterinary
Service

REFERRING VET

Dr. Shen Li

INVOICE

74218

DATE

4/5/26

Pancreas

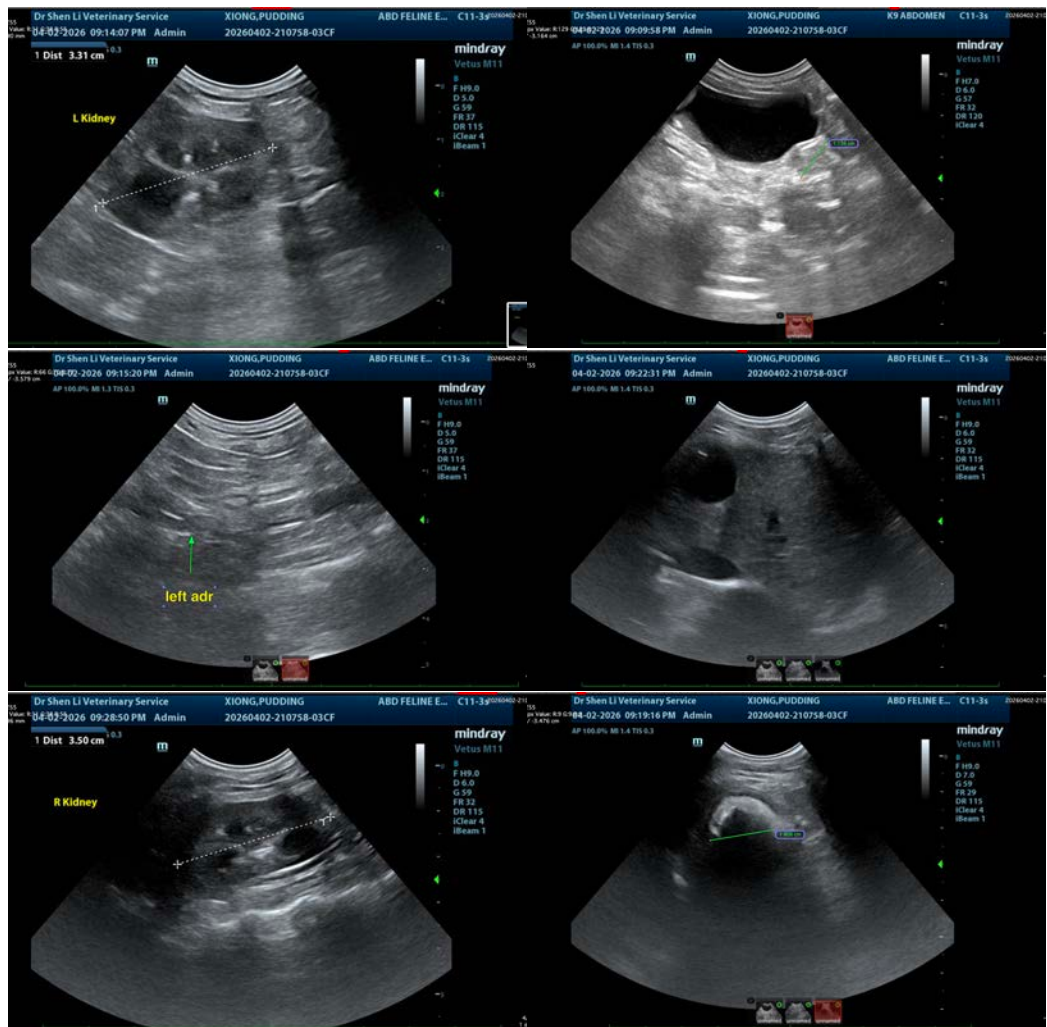
The base and limbs of the **pancreas** were observed to be largely isoechoic to surrounding omental fat. Pancreatic duct and capsular contour were acceptably normal and parenchyma respected normal curvilinear patterns. No overt evidence of active inflammatory or neoplastic disease was noted.

ULTRASONOGRAPHIC FINDINGS

- Shadowing structure in the stomach.
- Unremarkable abdomen otherwise.

INTERPRETATION OF THE FINDINGS & FURTHER RECOMMENDATIONS

If the patient was NPO at the time of the sonogram, suspect gastric foreign matter. Recheck sonogram at complete NPO status would be ideal.





PATIENT

Pudding Xiong

SPECIES

Canine

BREED

Pomeranian

SEX

Neutered Male

AGE

6 Years

WEIGHT

6

INTERPRETED BY

Eric Lindquist, DMV,
DABVP (CFM), Cert.
IVUSS

IMAGING PERFORMED BY

Dr. Shen Li

HOSPITAL NAME

Dr. Shen Li Veterinary
Service

REFERRING VET

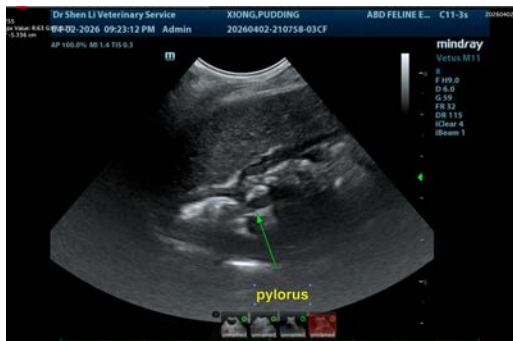
Dr. Shen Li

INVOICE

74218

DATE

4/5/26



The information and recommendations provided are based on the images presented by the referring veterinarian/sonographer. No evaluation can be communicated regarding pathology that was not visible in the image/video clips provided.

Thank you for this referral. If the clinical or image interpretation does not parallel your findings or if I can be of any further assistance please contact me.

Eric Lindquist, DMV, DABVP(CFM), Cert. IVUSS,
CEO, Owner, Founder -- SonoPath.com
info@SonoPath.com