


**PATIENT**

Neo Radue

**SPECIES**

Canine

**BREED**

Husky Mix

**SEX**

Neutered Male

**AGE**

4 Years

**WEIGHT**

60 Pounds

**PRESENTING CLINICAL SIGNS**

History: Inappetence and distended abdomen noted roughly 1-2 wks ago; xrays performed today revealed elevated VHS and pericardial effusion

**ULTRASONOGRAPHIC EXAMINATION OF THE HEART**

CANINE CARDIAC PARAMETERS	MR VMAX (m/s)	TR VMAX (m/s)	LA/AO (Boon method)	LA/AO (Heart Base; Swe)	FS (%)	EF (%)	EPSS (cm)
NORMAL PARAMETER	4.5-5.5	<2.7	1.3	<1.3	28-40	40-100	<0.6
PATIENT	--	--	1.15	--	30		NM
CANINE CARDIAC PARAMETERS	HR (BPM)	AV VMAX (m/s)	PV MAX (m/s)	BODY WEIGHT (kg)	LA 2D short axis Base view (cm)	LVIDd Avg; 2D and m-mode short axis (cm)	LVIDs Avg; 2D and m-mode short axis (cm)
NORMAL PARAMETER	50-100	0.7-1.7	0.7-1.6				
PATIENT	--	--	.90	--	2.7	3.34	--

**INTERPRETED BY**

 Eric Lindquist, DMV  
 DABVP, Cert. IVUSS

**IMAGING PERFORMED BY**

Jill Rumachik

**HOSPITAL NAME**

Clarity Imaging, LLC

**REFERRING VET**

Mark Baenen

**INVOICE**

21874

**DATE**

4/5/23

**Cardiac Presentation**

The cardiac presentation presented a large amount of pericardial effusion with tamponade effect and collapse of the right auricle. Approximately 3.0 cm of pericardial effusion was noted from the pericardium to the epicardium. No overt masses were noted, other than minor irregularity to the right auricle.

**ULTRASONOGRAPHIC FINDINGS**

- Large amount of pericardial effusion with tamponade effect and collapse of the right auricle

**INTERPRETATION OF THE FINDINGS & FURTHER RECOMMENDATIONS**

Ultrasound guided pericardial centesis, cytospin and cytology and culture are all indicated. Abdominal sonogram is warranted to assess for comorbidities that may be related to the pericardial effusion, such as hemangiosarcoma type lesions in the spleen or elsewhere. Chest radiographs are warranted to assess for concurrent pulmonary disease. Idiopathic pericardial effusion, pericarditis, occult neoplasia are all possible.



**PATIENT**

Neo Radue

**SPECIES**

Canine

**BREED**

Husky Mix

**SEX**

Neutered Male

**AGE**

4 Years

**WEIGHT**

60 Pounds

**INTERPRETED BY**

Eric Lindquist, DMV  
DABVP, Cert. IVUSS

**IMAGING PERFORMED BY**

Jill Rumachik

**HOSPITAL NAME**

Clarity Imaging, LLC

**REFERRING VET**

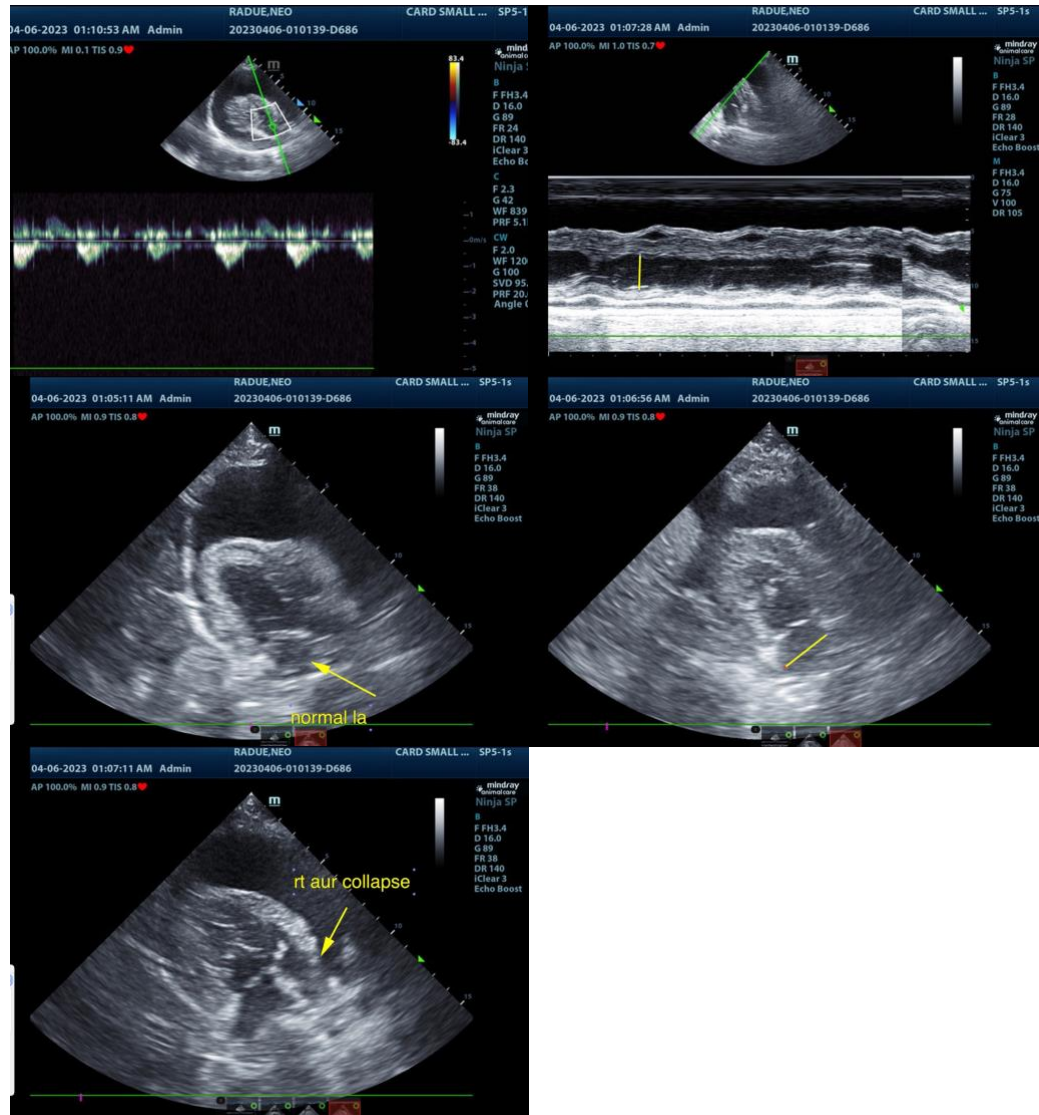
Mark Baenen

**INVOICE**

21874

**DATE**

4/5/23



The information and recommendations provided are based on the images presented by the referring veterinarian. No evaluation can be communicated regarding pathology that was not visible in the image/video clips provided.

Thank you for this referral. If the clinical or image interpretation does not parallel your findings or if I can be of any further assistance please contact me.

**Eric Lindquist**, DMV, DABVP, Cert. IVUSS, CEO of SonoPath.com  
info@SonoPath.com