



**PATIENT**

Meko Prince

**PRESENTING CLINICAL SIGNS**

History: Chronic weight loss despite decent appetite. No source revealed on bloodwork

**SPECIES**

Feline

**ULTRASONOGRAPHIC EXAMINATION OF THE ABDOMEN**

**Urinary System**

The **urinary bladder**, trigone, and pelvic urethra presented normal thicknesses and normal tone. The ureters were not visible which is normal. No uroliths or sediment were visualized and anechoic urine was present. No evidence of inflammatory or neoplastic changes were noted. Ureteral papillae were normal.

**BREED**

DSH

The **kidneys** revealed largely normal size and structure, corticomedullary definition and ratio (cortex 1/3 of medulla) were essentially maintained with some mild age-related loss of curvilinear patterns regarding the capsule and C/M junction. The cortices presented largely uniform texture with some increased echogenicity expected for his age patient. Medullary structure differed distinctly from that of the cortex and no evidence of pelvic dilation was present. Slight mineralization was present in the kidneys. The right kidney measured 3.86 cm. The left kidney measured 3.81 cm. A cortical infarct was noted at the dorsal cortex of the left kidney, stable.

**SEX**

Spayed Female

**AGE**

17

**Adrenal Glands**

The **left adrenal gland** was visualized and recognized as having normal shape, size, position and echogenicity for this breed. The phrenic vasculature, glandular echogenicity and detail were unremarkable. Capsule, cortex, and medullary definition were normal for this age patient. The left adrenal gland measured 0.3 cm.

**WEIGHT**

10.18

The region of the **right adrenal gland** revealed no evident pathology.

**INTERPRETED BY**

Eric Lindquist, DMV  
DABVP, Cert. IVUSS

**Spleen**

The **spleen** presented a smooth homogeneous parenchyma hyperechoic to liver and renal cortical parenchyma. The capsule was smooth without noticeable expansion or deviation from within the spleen or adjacent pathology. The splenic vasculature demonstrated normal volume without signs of congestion or thrombosis. No sonographic evidence of acute or chronic inflammatory, neoplastic, or infarctual changes were noted.

**IMAGING PERFORMED BY**

Dr. Winifred Krogman

**Liver**

The **liver** images from right and left intercostal as well as subcostal views revealed subjectively normal liver size, contour, and structure. Some age-related parenchymal remodeling was noted but likely not clinically significant at this time. Vascular tracts were of normal volume. The hepatic lymph nodes were unremarkable. A grouping of biliary calculi and sand were noted, measuring 1.0 cm.

**HOSPITAL NAME**

RB Northside AH

**REFERRING VET**

Dr. Winifred Krogman

**Gastrointestinal**

Examination of the **gastrointestinal tract** revealed a stomach and intestine free of stasis, of normal wall thickness, acceptable curvilinear mural detail, and peristaltic activity. Small and large intestine demonstrated normal luminal chyme and stool consistency respectively. No obstructive or overt infiltrative disease was noted. No associated abnormal lymphatic activity was noted.

**INVOICE**

21876

**DATE**

4/5/23

**Pancreas**



## PATIENT

Meko Prince

## SPECIES

Feline

## BREED

DSH

## SEX

Spayed Female

## AGE

17

## WEIGHT

10.18

## INTERPRETED BY

Eric Lindquist, DMV  
DABVP, Cert. IVUSS

## IMAGING PERFORMED BY

Dr. Winifred Krogman

## HOSPITAL NAME

RB Northside AH

## REFERRING VET

Dr. Winifred Krogman

## INVOICE

21876

## DATE

4/5/23

The base and limbs of the **pancreas** were observed to be largely isoechoic to surrounding omental fat. Some moderate parenchymal remodeling, however, with mild deviation from curvilinear normalcy was observed. Pancreatic duct and capsular irregularities were present consistent with age related changes. If pain upon imaging (+ Murphy sign) was present or if the patient is focally painful in subxyphoid palpation then low-grade smoldering chronic pancreatitis should be suspected.

### Free Abdomen

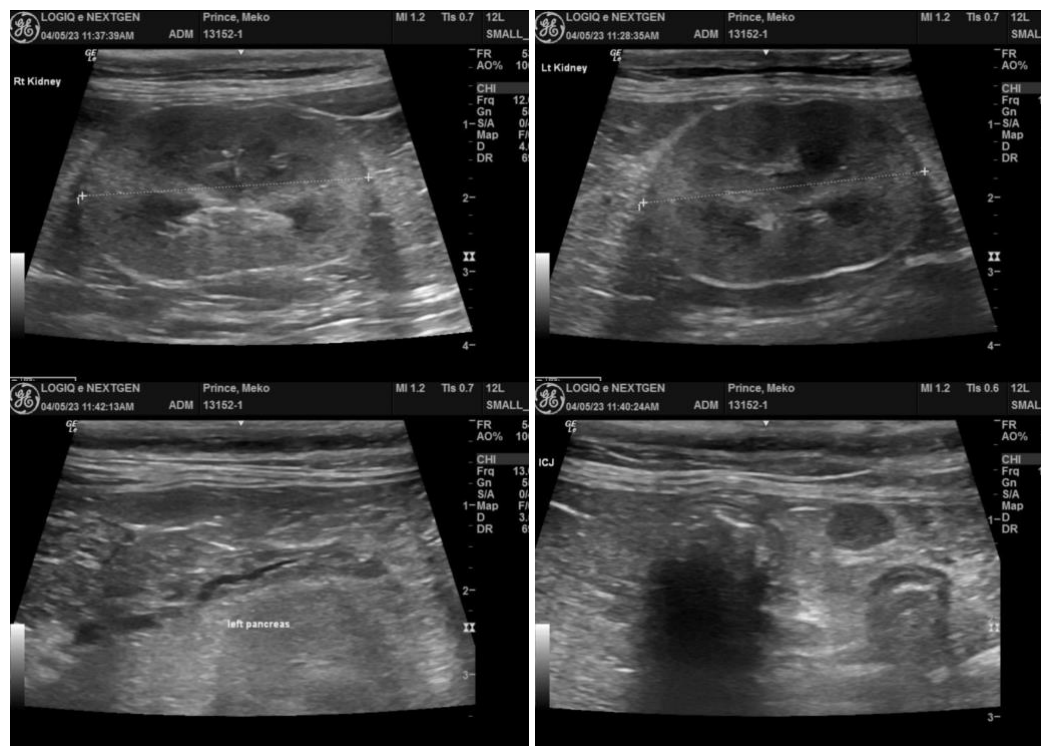
A mesenteric **lymph node** was rounded and hypoechoic, measuring 5.0 mm.

### ULTRASONOGRAPHIC FINDINGS

- Geriatric abdomen
- Chronic pancreatic changes
- Chronic renal changes with cortical infarct
- Gallbladder sand
- Minor mesenteric lymphadenopathy

### INTERPRETATION OF THE FINDINGS & FURTHER RECOMMENDATIONS

Ursodiol therapy could be considered for management. No evidence of neoplasia. Maldigestion panel, three view chest radiographs and full CNS examination is recommended to examine for occult disease that could be responsible for the weight loss. Evaluation for competitive eating environments should also be considered.





**PATIENT**

Meko Prince

**SPECIES**

Feline

**BREED**

DSH

**SEX**

Spayed Female

**AGE**

17

**WEIGHT**

10.18

**INTERPRETED BY**

Eric Lindquist, DMV  
DABVP, Cert. IVUSS

**IMAGING  
PERFORMED BY**

Dr. Winifred Krogman

**HOSPITAL NAME**

RB Northside AH

**REFERRING VET**

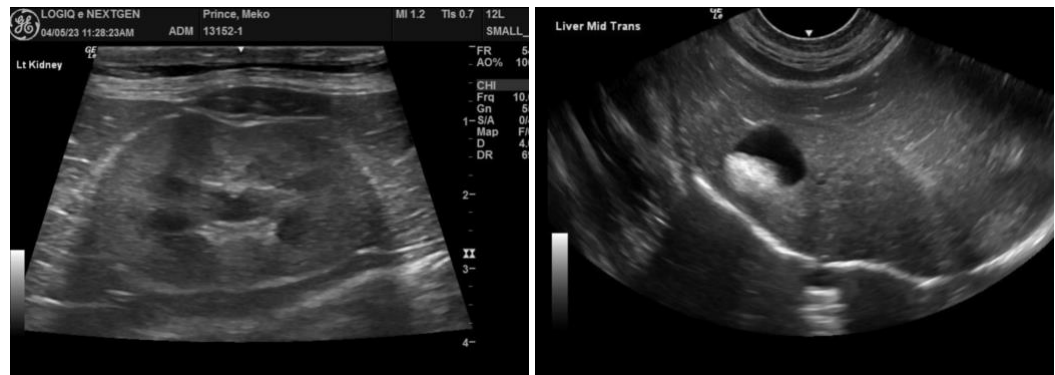
Dr. Winifred Krogman

**INVOICE**

21876

**DATE**

4/5/23



The information and recommendations provided are based on the images presented by the referring veterinarian. No evaluation can be communicated regarding pathology that was not visible in the image/video clips provided.

Thank you for this referral. If the clinical or image interpretation does not parallel your findings or if I can be of any further assistance please contact me.

**Eric Lindquist**, DMV, DABVP, Cert. IVUSS, CEO of SonoPath.com  
info@SonoPath.com