



PATIENT PRESENTING CLINICAL SIGNS

Bella Kane History: 3/4/23 admitted to OAH lethargy, anorexia/ vomiting/ pu/pd with inappropriate urination/weight loss. Hx of chronic cystic calculi (multiple cystotomies. CXR met clear

SPECIES Abnormal PE/Chem/CBC/UA Results: Increased calcium. Nonregenerative anemia Mass on liver vit
Canine d/PTTHrP panel supportive of primary parathyroidism

LIMITED ULTRASONOGRAPHIC EXAMINATION

BREED The thyroid region was imaged in this patient. The trachea and esophagus were unremarkable. The
Yorkie side of the adenoma was not indicated during the exam; therefore, the sonographer should elaborate upon which side the abdomen was localized. One thyroid lobe was normal with normal parathyroids. The opposite thyroid revealed a 0.6 cm hypoechoic nodule consistent with thyroid adenoma.

SEX **ULTRASONOGRAPHIC FINDINGS**

Spayed Female

- Hypoechoic nodule consistent with thyroid adenoma

AGE **INTERPRETATION OF THE FINDINGS & FURTHER RECOMMENDATIONS**

13 Surgical intervention is recommended; however, the sonographer should indicate which side the lesion is localized. This is adjacent to the esophagus, presumed to be left side, but should be confirmed by the sonographer.

WEIGHT

7.54

INTERPRETED BY

Eric Lindquist, DMV
DABVP, Cert. IVUSS

IMAGING PERFORMED BY

Elania Petrone

HOSPITAL NAME

Long Branch AH

REFERRING VET

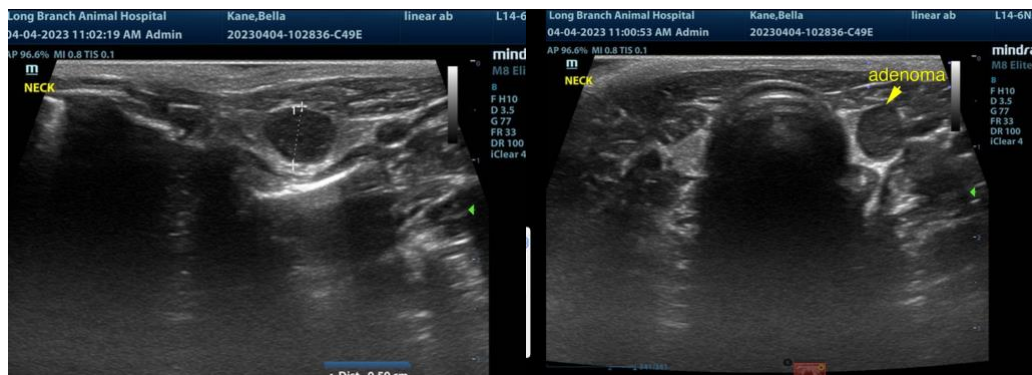
Neal Beeber

INVOICE

21881

DATE

4/5/23



The information and recommendations provided are based on the images presented by the referring veterinarian. No evaluation can be communicated regarding pathology that was not visible in the image/video clips provided.

Thank you for this referral. If the clinical or image interpretation does not parallel your findings or if I can be of any further assistance please contact me.

Eric Lindquist, DMV, DABVP, Cert. IVUSS, CEO of SonoPath.com
info@SonoPath.com