

**DATE**

4/5/22

**PRESENTING CLINICAL SIGNS**

Presenting complaint- uncomfortable, pacing pancreatitis. History- chronic pancreatitis, gall bladder issue. PE- abdomen tense on palpation.

**PATIENT**

Summer Gorman

Current Medications: Metronidazole 50mg SID, Famotidine 10mg BID, Ursodiol 125mg SID, Gabapentin 100mg BID, Cerenia 16mg SID PRN, Galliprant 20mg SID.

Date of Previous IntraPet Ultrasound: 7/27/17 and 9/19/17. See attached.

**SPECIES**

Canine

Sedation: Not required to complete full diagnostic ultrasound.

Stat Report: Not requested.

**BREED**

Miniature Schnauzer

**ULTRASONOGRAPHIC EXAMINATION OF THE ABDOMEN****Urinary System**

The **urinary bladder**, trigone, and pelvic urethra presented normal thicknesses and normal tone. The ureters were not visible which is normal. No uroliths or sediment were visualized and anechoic urine was present. No evidence of inflammatory or neoplastic changes were noted. Ureteral papillae were normal.

**SEX**

Spayed Female

The **kidneys** revealed largely normal size and structure, corticomedullary definition and ratio (cortex 1/3 of medulla) were essentially maintained with some age-related loss of curvilinear patterns regarding the capsule and C/M junction. The cortices presented largely uniform texture with some increased echogenicity expected for his age patient. Medullary structure differed distinctly from that of the cortex. The left kidney measured 4.48 cm with slight pyelectasia. The right kidney measured 3.91 cm.

**AGE**

5/14/05

**WEIGHT**

16.8 Pounds

**INTERPRETED BY**

Eric Lindquist, DMV  
DABVP, Cert. IVUSS

**Adrenal Glands**

Both **adrenal glands** were visualized and recognized as having normal shape, size, position and echogenicity for this breed. The phrenic vasculature, glandular echogenicity and detail were unremarkable. Capsule, cortex, and medullary definition were normal for this age patient. The left adrenal gland measured 1.87 cm x 0.49 cm at the caudal pole and 0.41 cm at the cranial pole. The right adrenal gland measured 2.25 cm x 0.42 cm at the caudal pole and 0.49 cm at the cranial pole.

**IMAGING PERFORMED BY**

Stephanie Pearce  
RDMS, RVT

**Spleen**

The **spleen** revealed persistent hypoechoic nodules. A large nodule measured 1.47 cm x 1.12 cm at the cranial pole. This is a progressive development. FNA or direct removal recommended. Capsular deviation noted with the splenic nodule at the cranial pole. It still may be benign. However, the capsular deviation is concerning.

**HOSPITAL NAME**

Honeygo AH

**Liver**

The **liver** was uniformly swollen and presented coarse architecture with mildly increased portal markings and subtle, mixed echogenic changes. This is consistent with vacuolar hepatopathy and some level of remodeling and history of inflammatory component. There was no overt suspicion of neoplasia. The gallbladder was unremarkable. No further mucocele formation.

**REFERRING VET**

Dr. Wright

**Gastrointestinal**

The **stomach** itself was unremarkable. Minor excessive intestinal wall thickness noted in portions of the small intestine, yet no loss of mural detail.

**INVOICE**

36738

**Pancreas**

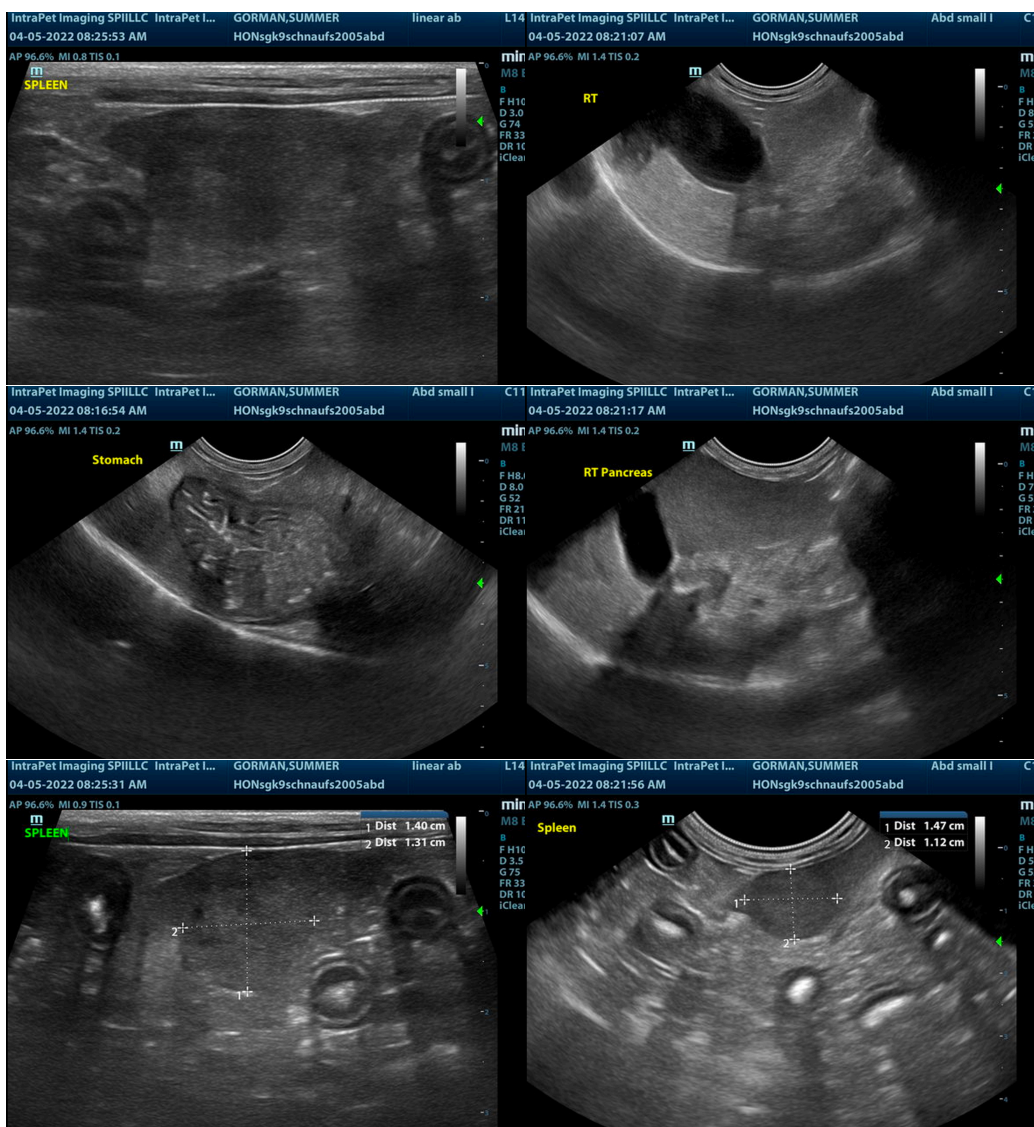
The base and limbs of the **pancreas** were observed to be largely isoechoic to surrounding omental fat. Some parenchymal remodeling, however, with mild deviation from curvilinear normalcy was observed. Pancreatic duct and capsular irregularities were present consistent with age related changes. If pain upon imaging (+ Murphy sign) was present or if the patient is focally painful in subxyphoid palpation then low-grade smoldering chronic pancreatitis should be suspected. The left limb measured 1.17 cm.

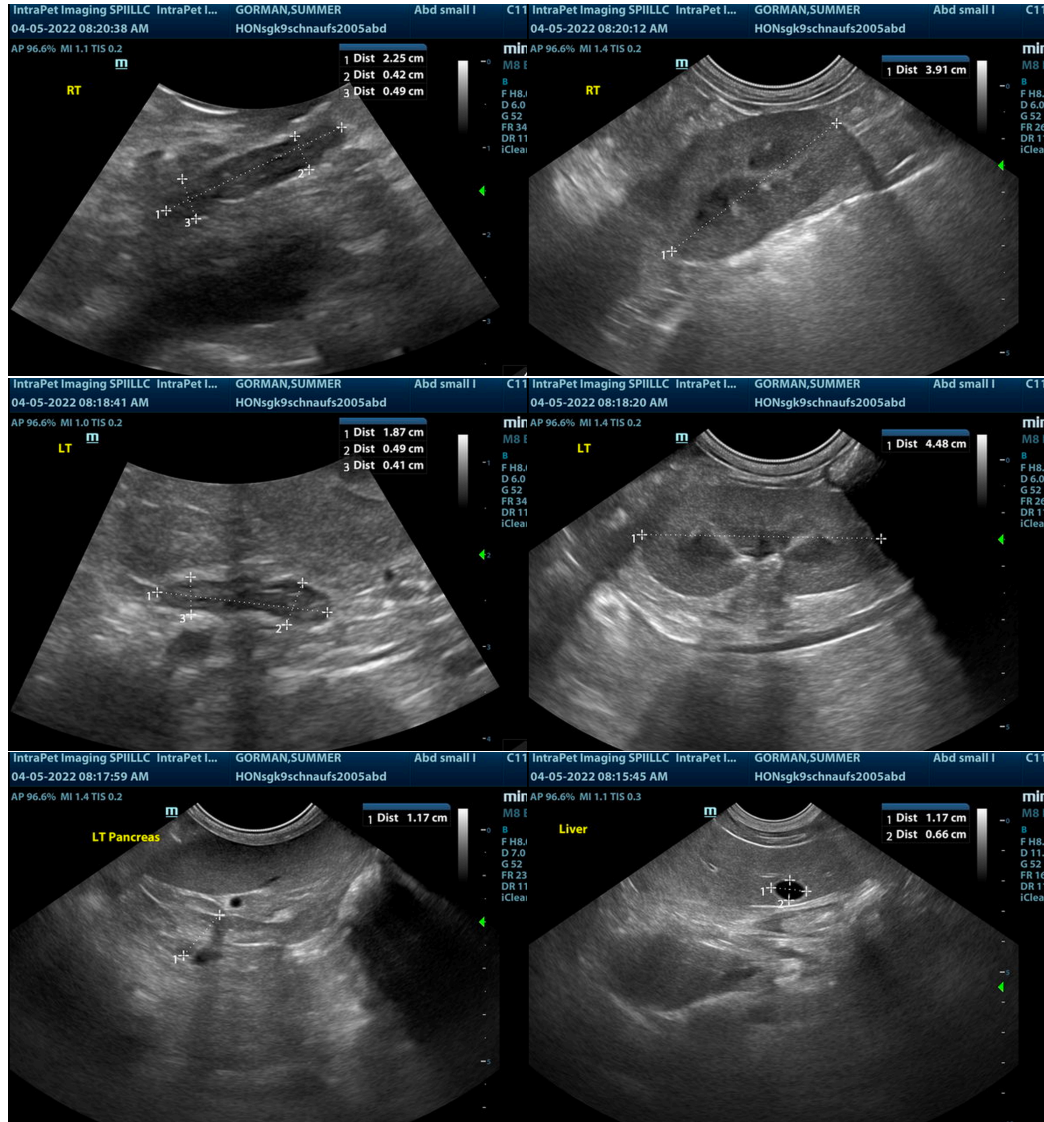
## ULTRASONOGRAPHIC FINDINGS

- Concerning splenic nodules – largest merits FNA.
- Minor intestinal thickening and pancreatic remodeling
- Stable abdomen otherwise

## INTERPRETATION OF THE FINDINGS & FURTHER RECOMMENDATIONS

Direct splenectomy could be justified. FNA could also be considered if direct splenectomy is not desired.





The information and recommendations provided are based on the images presented by the referring veterinarian/sonographer. No evaluation can be communicated regarding pathology that was not visible in the image/video clips provided.

Thank you for this referral. If the clinical or image interpretation does not parallel your findings or if I can be of any further assistance please contact me.

**Eric Lindquist, DMV, DABVP, Cert. IVUSS, CEO of SonoPath.com**  
[info@SonoPath.com](mailto:info@SonoPath.com)