



PATIENT	PRESENTING CLINICAL SIGNS
Sprite Walters	History: ate garbage has vomited aluminum foil, plastic, paper plates
SPECIES	ULTRASONOGRAPHIC EXAMINATION OF THE ABDOMEN
Canine	Urinary System
BREED	The urinary bladder , trigone, and pelvic urethra presented normal thicknesses and normal tone. The ureters were not visible which is normal. No uroliths or sediment were visualized and anechoic urine was present. No evidence of inflammatory or neoplastic changes was noted. Ureteral papillae were normal.
Great Pyrenees Mix	
SEX	The kidneys revealed normal size and structure, corticomedullary definition and ratio for this age. The cortices presented largely uniform texture with normal echogenic relationship to liver and spleen. Medullary structure differed distinctly from the cortex and no evidence of pelvic dilation was present. The capsules were acceptably uniform without significant irregularities. The right kidney measured 6.83 cm. The left kidney measured 6.39 cm.
Neutered male	
AGE	
2 years	
WEIGHT	Adrenal Glands
57 lbs	Both adrenal glands were visualized and recognized as having normal shape, size, position and echogenicity for this breed. The phrenic vasculature, glandular echogenicity and detail were unremarkable. Capsule, cortex, and medullary definition were normal for this age patient. The left adrenal gland measured 2.5 x 0.58 cm at the caudal pole and 0.66 cm at the cranial pole. The right adrenal gland measured 2.63 x 1.27 cm at the cranial pole and 0.77 cm at the caudal pole.
INTERPRETED BY	
Eric Lindquist, DMV DABVP, Cert. IVUSS	Spleen
IMAGING PERFORMED BY	The spleen was folded upon itself and was mildly enlarged.
Jenn	
HOSPITAL NAME	Liver
Rockaway AH	The liver revealed dilated hepatic veins with a trace amount of ascites. Chest assessment through radiographs and echocardiogram are warranted to assess for cause of passive congestion. The gallbladder presented acceptably thin walls with primarily anechoic content. The cystic and common bile ducts were normal. No pathological hepatic lymphadenopathy was evident.
REFERRING VET	
Dr. Maniar	Gastrointestinal
INVOICE	Examination of the gastrointestinal tract revealed a stomach and intestine free of stasis, of normal wall thickness, acceptable curvilinear mural detail, and peristaltic activity. Small and large intestine demonstrated normal luminal chyme and stool consistency respectively. No obstructive or overt infiltrative disease was noted. No associated abnormal lymphatic activity was noted.
98041	
DATE	
4/5/22	



PATIENT

Pancreas

Sprite Walters

The base and limbs of the **pancreas** were observed to be largely isoechoic to surrounding omental fat. Pancreatic duct and capsular contour were acceptably normal and parenchyma respected normal curvilinear patterns. No overt evidence of active inflammatory or neoplastic disease was noted.

SPECIES

Canine

ULTRASONOGRAPHIC FINDINGS

BREED

Minor ascites and passive congestion liver pattern.

Great Pyrenees Mix

Otherwise, unremarkable abdomen.

SEX

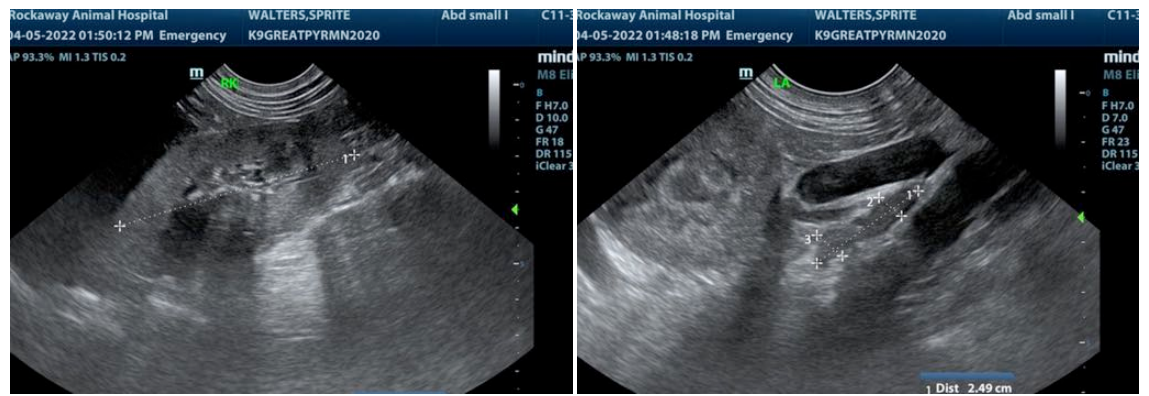
INTERPRETATION OF THE FINDINGS & FURTHER RECOMMENDATIONS

Neutered male

Thoracic work-up is recommended.

AGE

2 years



WEIGHT

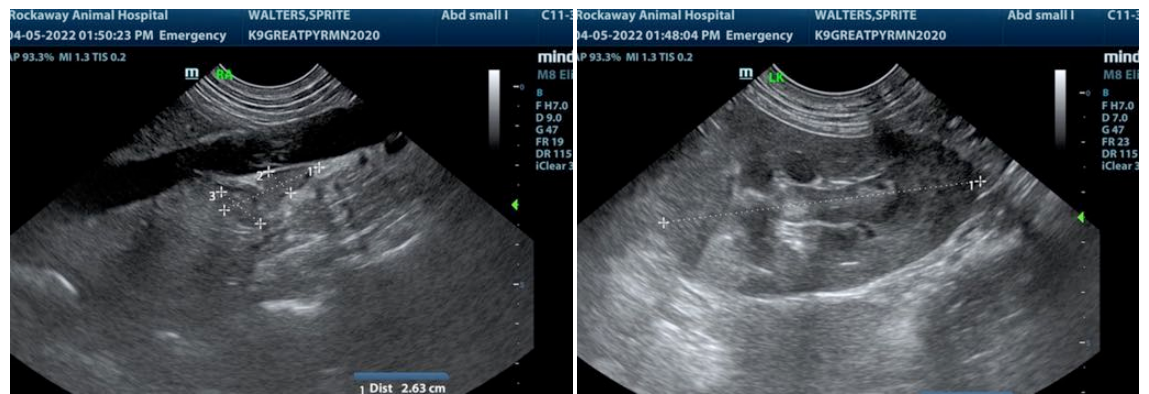
57 lbs

INTERPRETED BY

Eric Lindquist, DMV
DABVP, Cert. IVUSS

IMAGING PERFORMED BY

Jenn



HOSPITAL NAME

Rockaway AH

REFERRING VET

Dr. Maniar

INVOICE

98041

DATE

4/5/22



PATIENT

Sprite Walters

SPECIES

Canine

BREED

Great Pyrenees Mix

SEX

Neutered male

AGE

2 years

WEIGHT

57 lbs

INTERPRETED BY

Eric Lindquist, DMV
DABVP, Cert. IVUSS

IMAGING PERFORMED BY

Jenn

HOSPITAL NAME

Rockaway AH

REFERRING VET

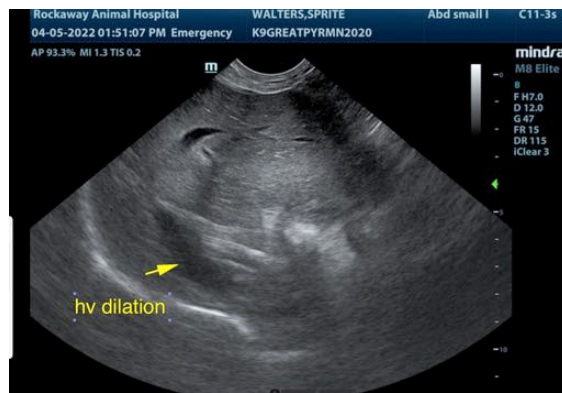
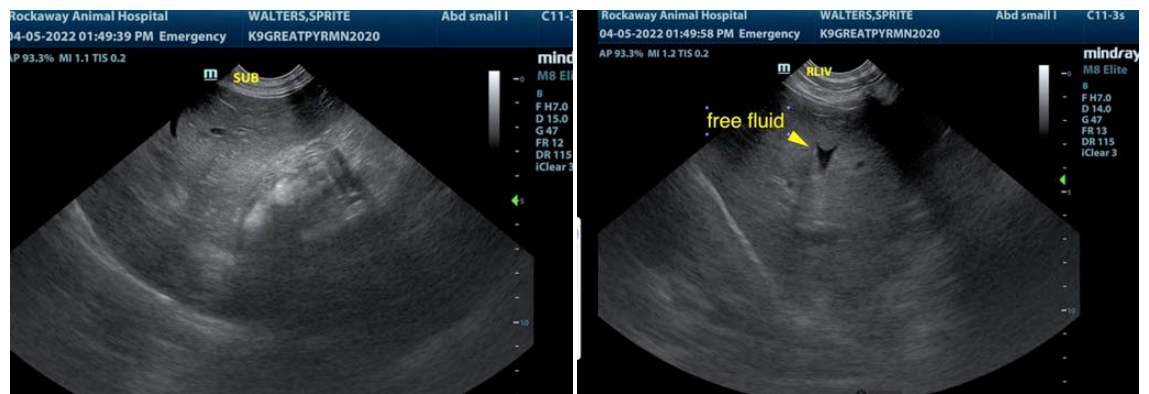
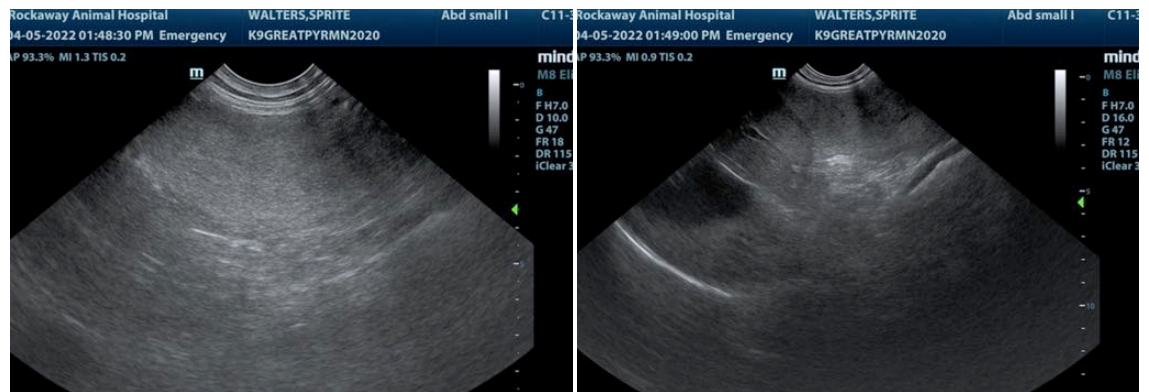
Dr. Maniar

INVOICE

98041

DATE

4/5/22



The information and recommendations provided are based on the images presented by the referring veterinarian/sonographer. No evaluation can be communicated regarding pathology that was not visible in the image/video clips provided.

Thank you for this referral. If the clinical or image interpretation does not parallel your findings or if I can be of any further assistance please contact me.

Eric Lindquist, DMV, DABVP, Cert. IVUSS, CEO of SonoPath.com



PATIENT

info@SonoPath.com

Sprite Walters

SPECIES

Canine

BREED

Great Pyrenees Mix

SEX

Neutered male

AGE

2 years

WEIGHT

57 lbs

INTERPRETED BY

Eric Lindquist, DMV
DABVP, Cert. IVUSS

**IMAGING
PERFORMED BY**

Jenn

HOSPITAL NAME

Rockaway AH

REFERRING VET

Dr. Maniar

INVOICE

98041

DATE

4/5/22