

PATIENT PRESENTING CLINICAL SIGNS

Reina Krunic Intact female, previous heat underwent a false pregnancy. This heat was intentionally bred about 30-35 days ago. Wanting to confirm if pregnant as seems a bit more tired lately.

SPECIES LIMITED ULTRASONOGRAPHIC EXAMINATION

Canine The caudal pole of the spleen revealed a concerning nodule measuring 1.5 cm. Capsular expansion noted.

BREED
Doberman The uterus revealed a 2.0 cm x 1.5 cm density within the mid uterine body, consistent with resorbing fetus, incidental finding. Other densities were also present.

SEX

Intact Female

- Multiple uterine densities – consistent with resorbing fetuses.
- Concurrent splenic nodule

INTERPRETATION OF THE FINDINGS & FURTHER RECOMMENDATIONS

AGE

3.5 Years

Intrauterine fetal death suspected. If no further breeding is to occur in this patient, then ovariohysterectomy/splenectomy warranted, given the splenic nodular change. FNA of the splenic nodule warranted for further definition. Nodular hyperplasia, round cell neoplasia, hemangiosarcoma all possible. If breeding is to continue in this patient, then medical evacuation of the uterus with broad-spectrum antibiotics to treat for potential underlying metritis would be indicated.

WEIGHT

76 Pounds

There are no live fetuses in this patient, and the fetal structure is significantly disrupted. Fetal death likely occurred in the last 7-10 days judging by the uterine presentation. If medical management is to occur, then recheck sonogram recommended 5-7 days post-treatment.

INTERPRETED BY

Eric Lindquist, DMV
DABVP, Cert. IVUSS

IMAGING PERFORMED BY

Crystal Hill

HOSPITAL NAME

Barton Grays

REFERRING VET

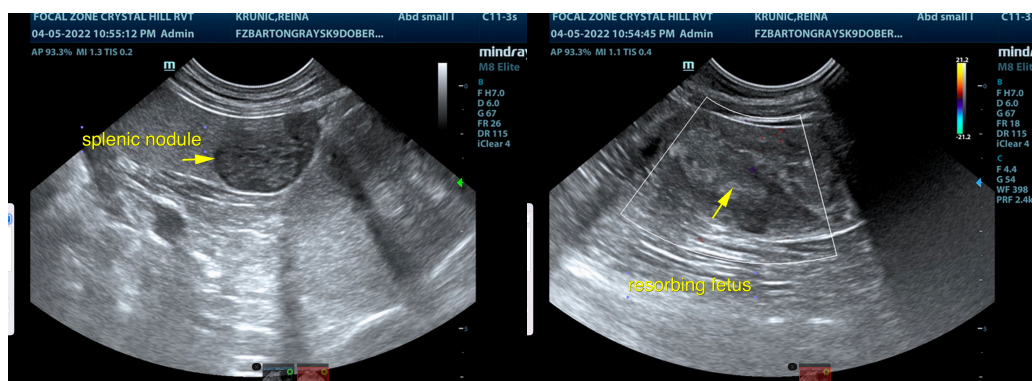
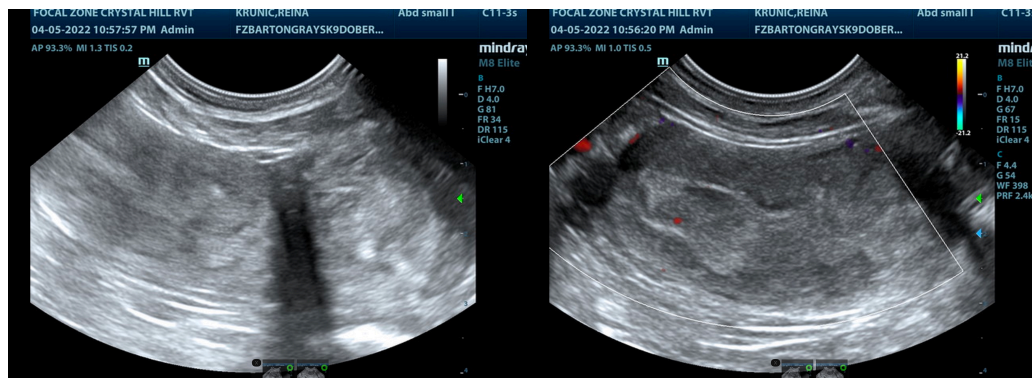
Dr. Virdi

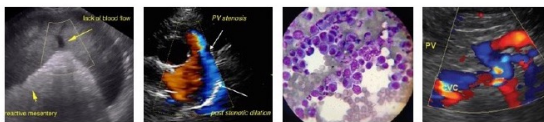
INVOICE

36731

DATE

4/5/22





PATIENT

Reina Krunic

The information and recommendations provided are based on the images presented by the referring veterinarian/sonographer. No evaluation can be communicated regarding pathology that was not visible in the image/video clips provided.

SPECIES

Canine

Thank you for this referral. If the clinical or image interpretation does not parallel your findings or if I can be of any further assistance please contact me.

Eric Lindquist, DMV, DABVP, Cert. IVUSS, CEO of SonoPath.com

info@SonoPath.com

BREED

Doberman

SEX

Intact Female

AGE

3.5 Years

WEIGHT

76 Pounds

INTERPRETED BY

Eric Lindquist, DMV

DABVP, Cert. IVUSS

IMAGING PERFORMED BY

Crystal Hill

HOSPITAL NAME

Barton Grays

REFERRING VET

Dr. Virdi

INVOICE

36731

DATE

4/5/22