



PATIENT PRESENTING CLINICAL SIGNS

Harry Schuld Hx of stage B2 valvular disease and increasing UPC (was .7) now .9 after doxy tx. Current meds: Vetmedin 2.5mg - 1C BID
Abnormal PE/Chem/CBC/UA Results: 1/13/22: AST 13, Platelet Count 491 UA: pH 5.0 SG: 1.030

SPECIES

Canine

ULTRASONOGRAPHIC EXAMINATION OF THE HEART & ABDOMEN

BREED

Rat Terrier

SEX

Neutered Male

AGE

14 Years

WEIGHT

15 Pounds

CANINE CARDIAC PARAMETERS	MR VMAX (m/s)	TR VMAX (m/s)	LA/AO (Boon method)	LA/AO (Heart Base; Swe)	FS (%)	EF (%)	EPSS (cm)
NORMAL PARAMETER	4.5-5.5	<2.7	1.3	<1.6	28-40	40-100	<0.6
PATIENT	5.05		NM	1.35	48	81	0.1
CANINE CARDIAC PARAMETERS	HR (BPM)	AV VMAX (m/s)	PV MAX (m/s)	BODY WEIGHT (kg)	LA 2D short axis Base view (cm)	LVIDd Avg; 2D and m-mode short axis (cm)	LVIDs Avg; 2D and m-mode short axis (cm)
NORMAL PARAMETER	50-100	0.7-1.7	0.7-1.6	BELOW	BELOW	BELOW	BELOW
PATIENT	148	1.5	1.1		2.41	2.51	

INTERPRETED BY

Eric Lindquist, DMV
DABVP, Cert. IVUSS

IMAGING PERFORMED BY

Jessica Miller

HOSPITAL NAME

ACC Flanders

REFERRING VET

Dr. Hallihan

INVOICE

36722

DATE

4/5/22

Cardiac Presentation

The cardiac presentation revealed improved left atrial volumes. Mitral insufficiency noted. Mitral valve prolapse present, yet compensated at this time. Moderate filling of the left atrium noted. Contractility and volumes of all four chambers were normalized. Trivial aortic insufficiency noted. No pericardial or pleural effusion noted.

Urinary System

The urinary bladder, trigone, and pelvic urethra presented normal thicknesses and normal tone. The ureters were not visible which is normal. No uroliths or sediment were visualized and anechoic urine was present. No evidence of inflammatory or neoplastic changes were noted. Ureteral papillae were normal.

The residual prostate was similar to the prior sonogram at 1.0 cm, mildly heterogeneous yet uniform.

The kidneys revealed largely normal size and structure, corticomedullary definition and ratio (cortex 1/3 of medulla) were essentially maintained with some age-related loss of curvilinear patterns regarding the capsule and C/M junction. The cortices presented largely uniform texture with some increased echogenicity expected for his age patient. Medullary structure differed distinctly from that of the cortex and no evidence of pelvic dilation was present. The left kidney measured 4.3 cm. The right kidney measured 4.54 cm.

Adrenal Glands

Both adrenal glands were visualized and recognized as having normal shape, size, position and echogenicity for this breed. The phrenic vasculature, glandular echogenicity and detail were unremarkable. Capsule, cortex, and medullary definition were normal for this age patient. The left



PATIENT

Harry Schuld

adrenal gland measured 2.06 cm x 0.62 cm at the caudal pole and 0.59 cm at the cranial pole. The right adrenal gland measured 1.61 cm x 0.49 cm at the caudal pole and 0.46 cm at the cranial pole.

Spleen

SPECIES

Canine

The **spleen** presented a smooth homogeneous parenchyma hyperechoic to liver and renal cortical parenchyma. The capsule was smooth without noticeable expansion or deviation from within the spleen or adjacent pathology. The splenic vasculature demonstrated normal volume without signs of congestion or thrombosis. No sonographic evidence of acute or chronic inflammatory, neoplastic, or infarctual changes were noted.

BREED

Rat Terrier

Liver

SEX

Neutered Male

The **liver** images submitted revealed subjectively normal liver size, contour, and structure. Parenchymal echogenicity was naturally coarse and hypoechoic to the spleen. Vascular and biliary tracts were of normal volume with no evidence of congestion. The gallbladder presented acceptably thin walls with primarily anechoic content. The cystic and common bile ducts were normal. No pathological hepatic lymphadenopathy was evident. No overt structural evidence of inflammatory, infiltrative or regenerative pathology was evident.

AGE

14 Years

Gastrointestinal

WEIGHT

15 Pounds

Examination of the **gastrointestinal tract** revealed a stomach and intestine free of stasis, of normal wall thickness, acceptable curvilinear mural detail, and peristaltic activity. Small and large intestine demonstrated normal luminal chyme and stool consistency respectively. No obstructive or overt infiltrative disease was noted. No associated abnormal lymphatic activity was noted.

Pancreas

INTERPRETED BY

Eric Lindquist, DMV

The base and limbs of the **pancreas** were observed to be largely isoechoic to surrounding omental fat. Pancreatic duct and capsular contour were acceptably normal and parenchyma respected normal curvilinear patterns. No overt evidence of active inflammatory or neoplastic disease was noted.

DABVP, Cert. IVUSS

ULTRASONOGRAPHIC FINDINGS

IMAGING PERFORMED BY

Jessica Miller

- Stable valvular disease
- Geriatric abdomen

INTERPRETATION OF THE FINDINGS & FURTHER RECOMMENDATIONS

HOSPITAL NAME

ACC Flanders

Recommend continuation of the current protocol and recheck echo in 6 months.

REFERRING VET

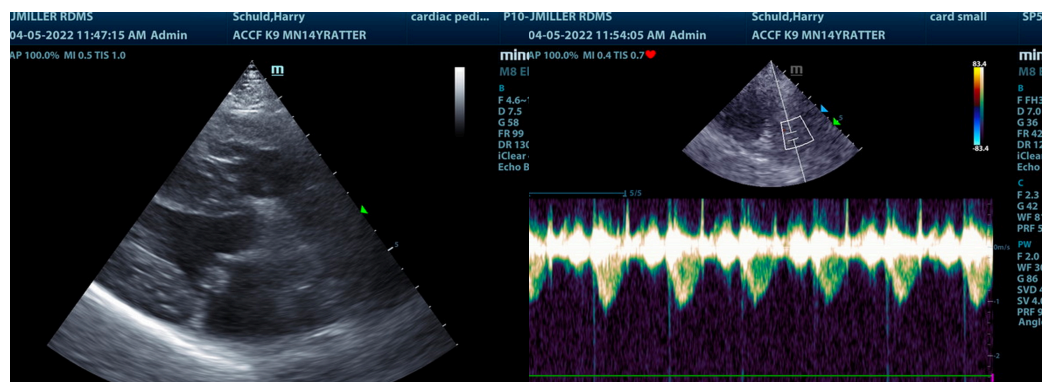
Dr. Hallihan

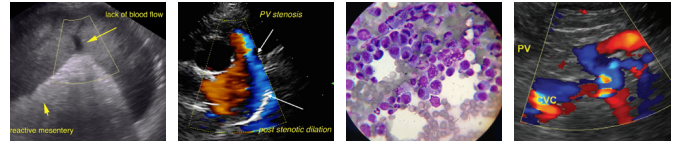
INVOICE

36722

DATE

4/5/22





PATIENT

Harry Schuld

SPECIES

Canine

BREED

Rat Terrier

SEX

Neutered Male

AGE

14 Years

WEIGHT

15 Pounds

INTERPRETED BY

Eric Lindquist, DMV
DABVP, Cert. IVUSS

IMAGING PERFORMED BY

Jessica Miller

HOSPITAL NAME

ACC Flanders

REFERRING VET

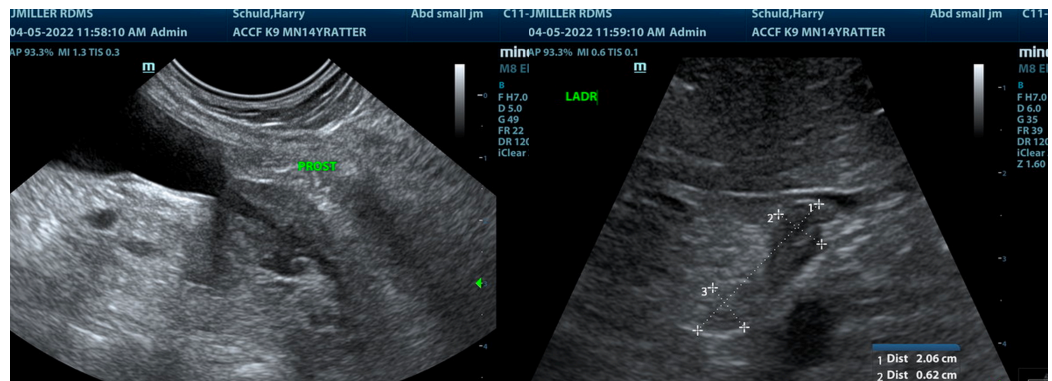
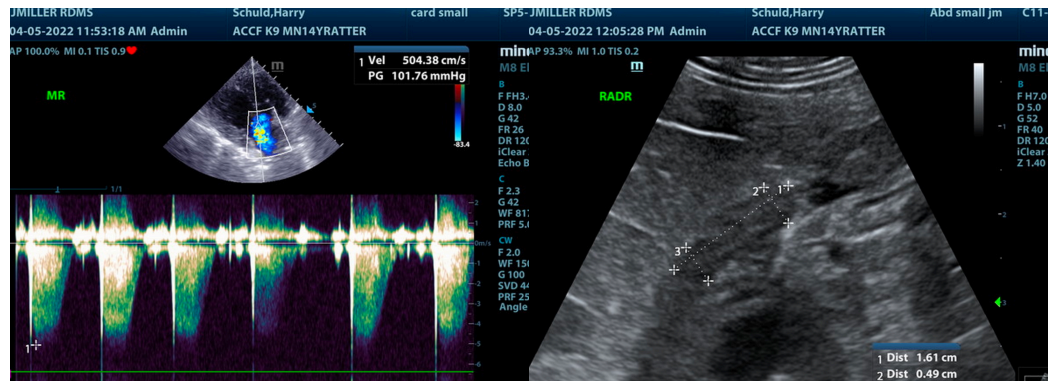
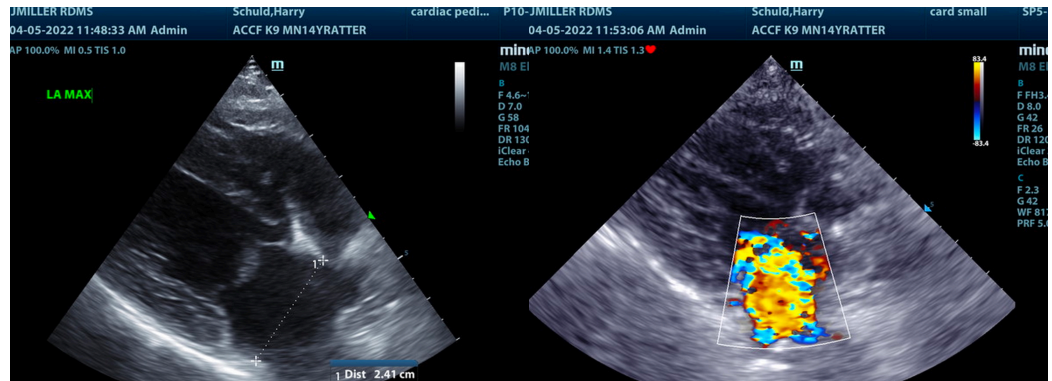
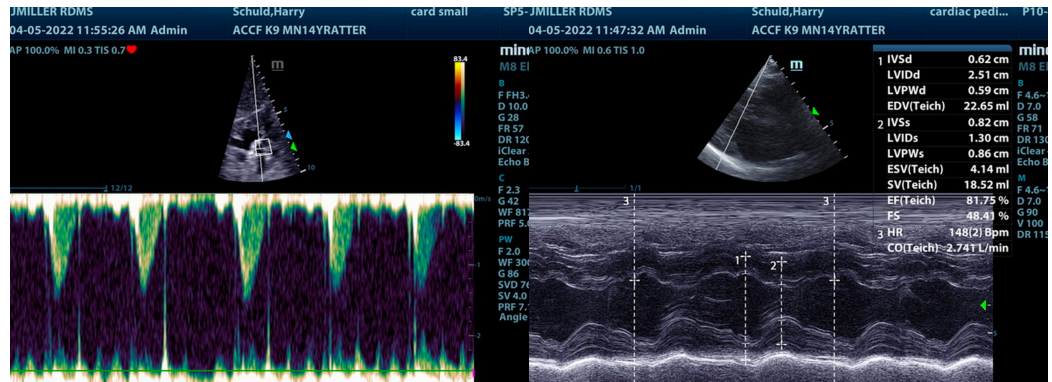
Dr. Hallihan

INVOICE

36722

DATE

4/5/22





PATIENT

Harry Schuld

SPECIES

Canine

BREED

Rat Terrier

SEX

Neutered Male

AGE

14 Years

WEIGHT

15 Pounds

INTERPRETED BY

Eric Lindquist, DMV

DABVP, Cert. IVUSS

IMAGING PERFORMED BY

Jessica Miller

HOSPITAL NAME

ACC Flanders

REFERRING VET

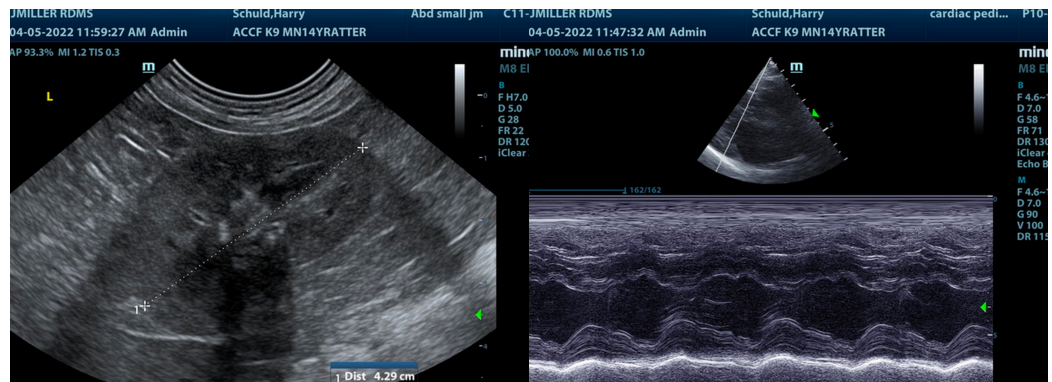
Dr. Hallihan

INVOICE

36722

DATE

4/5/22



The information and recommendations provided are based on the images presented by the referring veterinarian/sonographer. No evaluation can be communicated regarding pathology that was not visible in the image/video clips provided.

Thank you for this referral. If the clinical or image interpretation does not parallel your findings or if I can be of any further assistance please contact me.

Eric Lindquist, DMV, DABVP, Cert. IVUSS, CEO of SonoPath.com

info@SonoPath.com