



PATIENT

Gabe Worthy Tails
Rescue

SPECIES

Canine

BREED

Mastiff X

SEX

Male

AGE

4 Months

WEIGHT

30 Pounds

INTERPRETED BY

Eric Lindquist, DMV

DABVP, Cert. IVUSS

IMAGING PERFORMED BY

Dr. Jennifer Todd

HOSPITAL NAME

Lambs Gap AH

REFERRING VET

Dr. Cynthia Kinney

INVOICE

36725

DATE

4/5/22

PRESENTING CLINICAL SIGNS

Gabe is currently in a foster to adopt home. He is a happy and lovable pup. Gabe is an intact 18 week-old intact mastiff mix who initially presented for increased urination, litter mate was also having issues including a UTI so both were treated for UTI and posthitis since significant abnormal prepuccial discharge, clavamox was initially given then cefodoxime, complete resolution of urinary accidents never occurred, there were some concerns about inconsistency with training, there were intermittent reports of improvement of urinary accidents and licking penis, Dr. Todd dispensed topical dermalone for inflamed tip of penis, Gabe had periods of infrequent or no urinary accidents including when crated, urinary accidents in Gabe's case have been urinating inside after just being outside, multiple areas of urination, dribbling while walking (but only inside/not outside), this past week the urinary accidents/issues have amplified, foster reports he does drink a lot of water, his USG for 5 UA's have been 1.037 (first), 1.050, 1.030, 1.047, and 1.028 (most recent), AUS has been recommended to assess urinary system and in particular assess for ectopic ureters and evaluate renal structure

ULTRASONOGRAPHIC EXAMINATION OF THE ABDOMEN

Urinary System

The **urinary bladder**, trigone, and pelvic urethra presented normal thicknesses and normal tone. The ureters were not visible which is normal. No uroliths or sediment were visualized and anechoic urine was present. No evidence of inflammatory or neoplastic changes were noted. Ureteral papillae were normal. No evidence of ectopic ureters.

The **kidneys** revealed normal size and structure, corticomedullary definition and ratio for this age. The cortices presented largely uniform texture with normal echogenic relationship to liver and spleen. Medullary structure differed distinctly from the cortex and no evidence of pelvic dilation was present. The capsules were acceptably uniform without significant irregularities. The left kidney measured 5.87 cm. The right kidney measured 6.27 cm.

Adrenal Glands

Both **adrenal glands** were visualized and recognized as having normal shape, size, position and echogenicity for this breed. The phrenic vasculature, glandular echogenicity and detail were unremarkable. Capsule, cortex, and medullary definition were normal for this age patient. The left adrenal gland measured 2.28 cm x 0.32 cm at the cranial pole and 0.41 cm at the caudal pole. The right adrenal gland measured 2.58 cm x 1.0 cm at the cranial pole and 0.50 cm at the caudal pole.

Spleen

The **spleen** presented a smooth homogeneous parenchyma hyperechoic to liver and renal cortical parenchyma. The capsule was smooth without noticeable expansion or deviation from within the spleen or adjacent pathology. The splenic vasculature demonstrated normal volume without signs of congestion or thrombosis. No sonographic evidence of acute or chronic inflammatory, neoplastic, or infarctual changes were noted.

Liver

The **liver** images submitted revealed subjectively normal liver size, contour, and structure. Parenchymal echogenicity was naturally coarse and hypoechoic to the spleen. Vascular and biliary tracts were of normal volume with no evidence of congestion. The gallbladder presented acceptably thin walls with primarily anechoic content. The cystic and common bile ducts were normal. No pathological hepatic lymphadenopathy was evident. No overt structural evidence of inflammatory, infiltrative or regenerative pathology was evident.



PATIENT

Gastrointestinal

Gabe Worthy Tails
Rescue

Examination of the **gastrointestinal tract** revealed a stomach and intestine free of stasis, of normal wall thickness, acceptable curvilinear mural detail, and peristaltic activity. Small and large intestine demonstrated normal luminal chyme and stool consistency respectively. No obstructive or overt infiltrative disease was noted. No associated abnormal lymphatic activity was noted.

SPECIES

Canine

Pancreas

BREED

Mastiff X

The base and limbs of the **pancreas** were observed to be largely isoechoic to surrounding omental fat. Pancreatic duct and capsular contour were acceptably normal and parenchyma respected normal curvilinear patterns. No overt evidence of active inflammatory or neoplastic disease was noted.

ULTRASONOGRAPHIC FINDINGS

SEX

- Normal abdomen and urinary tract

Male

INTERPRETATION OF THE FINDINGS & FURTHER RECOMMENDATIONS

No evidence of pathology.

AGE

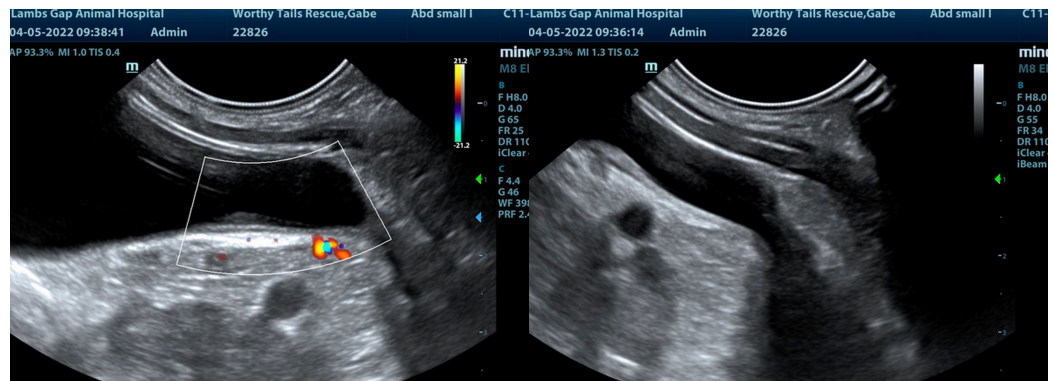
4 Months

WEIGHT

30 Pounds

INTERPRETED BY

Eric Lindquist, DMV
DABVP, Cert. IVUSS

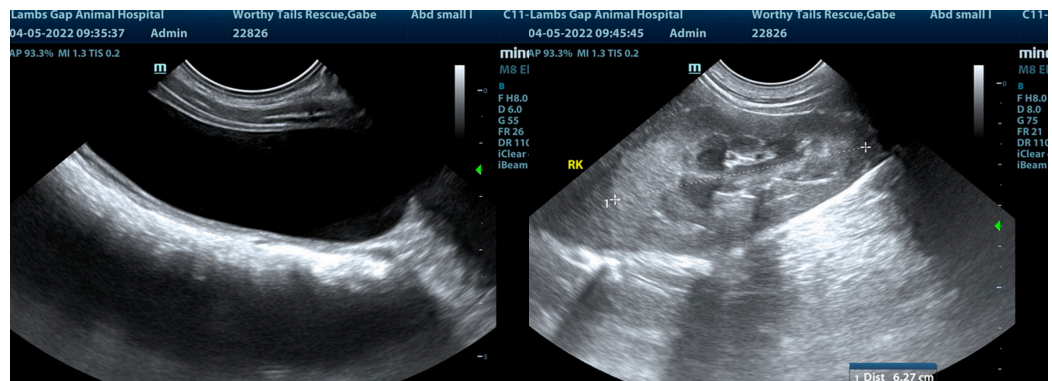


IMAGING PERFORMED BY

Dr. Jennifer Todd

HOSPITAL NAME

Lambs Gap AH



REFERRING VET

Dr. Cynthia Kinney

INVOICE

36725

DATE

4/5/22



PATIENT

Gabe Worthy Tails Rescue

SPECIES

Canine

BREED

Mastiff X

SEX

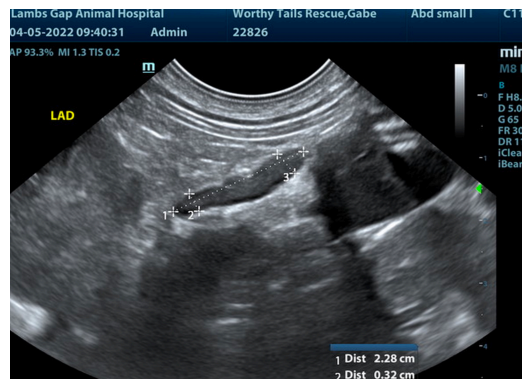
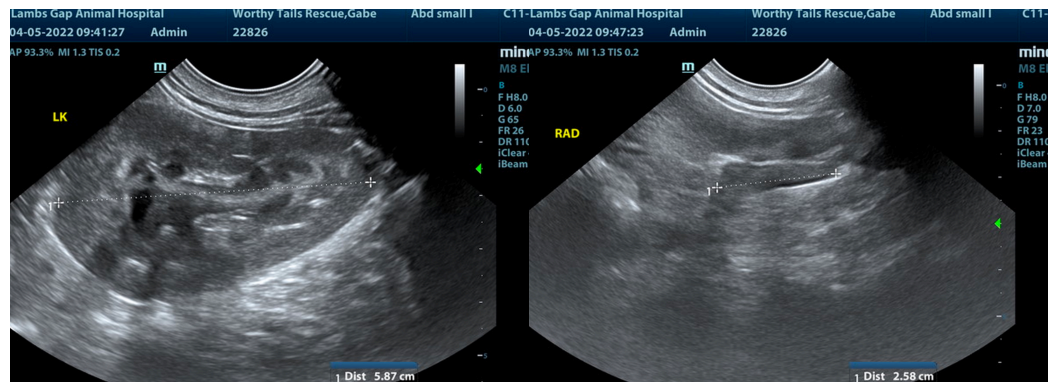
Male

AGE

4 Months

WEIGHT

30 Pounds



The information and recommendations provided are based on the images presented by the referring veterinarian/sonographer. No evaluation can be communicated regarding pathology that was not visible in the image/video clips provided.

Thank you for this referral. If the clinical or image interpretation does not parallel your findings or if I can be of any further assistance please contact me.

Eric Lindquist, DMV, DABVP, Cert. IVUSS, CEO of SonoPath.com

info@SonoPath.com

INTERPRETED BY

Eric Lindquist, DMV
DABVP, Cert. IVUSS

IMAGING PERFORMED BY

Dr. Jennifer Todd

HOSPITAL NAME

Lambs Gap AH

REFERRING VET

Dr. Cynthia Kinney

INVOICE

36725

DATE

4/5/22