



PATIENT

Fin Bressi

SPECIES

Canine

BREED

Terrier Mix

SEX

Neutered male

AGE

6 years

WEIGHT

18.8 lbs

INTERPRETED BY

Eric Lindquist, DMV
DABVP, Cert. IVUS

IMAGING PERFORMED BY

Jenn

HOSPITAL NAME

Rockaway AH

REFERRING VET

Dr. Maniar

INVOICE

74158

DATE

4/4/26

PRESENTING CLINICAL SIGNS

- Recheck from 4/3 gastric fb's

ULTRASONOGRAPHIC EXAMINATION OF THE ABDOMEN

Urinary System

The **urinary bladder**, trigone, and pelvic urethra presented normal thicknesses and normal tone. The ureters were not visible which is normal. No uroliths or sediment were visualized and anechoic urine was present. No evidence of inflammatory or neoplastic changes was noted. Ureteral papillae were normal.

The **kidneys** revealed normal size and structure, corticomedullary definition and ratio for this age. The cortices presented largely uniform texture with normal echogenic relationship to liver and spleen. Medullary structure differed distinctly from the cortex and no evidence of pelvic dilation was present. The capsules were acceptably uniform without significant irregularities. The right kidney measured 4.2 cm. The left kidney measured 4.63 cm.

Adrenal Glands

Both **adrenal glands** were visualized and recognized as having normal shape, size, position and echogenicity for this breed. The phrenic vasculature, glandular echogenicity and detail were unremarkable. Capsule, cortex, and medullary definition were normal for this age patient. The left adrenal gland measured 2.1 x 0.58 cm at the caudal pole and 0.51 cm at the cranial pole. The right adrenal gland measured 1.9 x 0.84 cm at the cranial pole and 0.56 cm at the caudal pole.

Spleen

The **spleen** presented a smooth homogeneous parenchyma hyperechoic to liver and renal cortical parenchyma. The capsule was smooth without noticeable expansion or deviation from within the spleen or adjacent pathology. The splenic vasculature demonstrated normal volume without signs of congestion or thrombosis. No sonographic evidence of acute or chronic inflammatory, neoplastic, or infarctual changes was noted.

Liver

The **liver** images submitted revealed subjectively normal liver size, contour, and structure. Parenchymal echogenicity was naturally coarse and hypoechoic to the spleen. Vascular and biliary tracts were of normal volume with no evidence of congestion. The gallbladder presented acceptably thin walls with primarily anechoic content. The cystic and common bile ducts were normal. No pathological hepatic lymphadenopathy was evident. No overt structural evidence of inflammatory, infiltrative or regenerative pathology was evident.



PATIENT

Fin Bressi

SPECIES

Canine

BREED

Terrier Mix

SEX

Neutered male

AGE

6 years

WEIGHT

18.8 lbs

INTERPRETED BY

Eric Lindquist, DMV
DABVP, Cert. IVUS

IMAGING PERFORMED BY

Jenn

HOSPITAL NAME

Rockaway AH

REFERRING VET

Dr. Maniar

INVOICE

74158

DATE

4/4/26

Gastrointestinal

The **stomach** was empty. The shadowing structures noted on the prior sonogram appear to have resolved. Gastric wall thickening remained with some minor heterogenous, mixed periserosal inflammatory pattern. The small intestines and colon were unremarkable with normal curvilinear mural patterns and content.

Pancreas

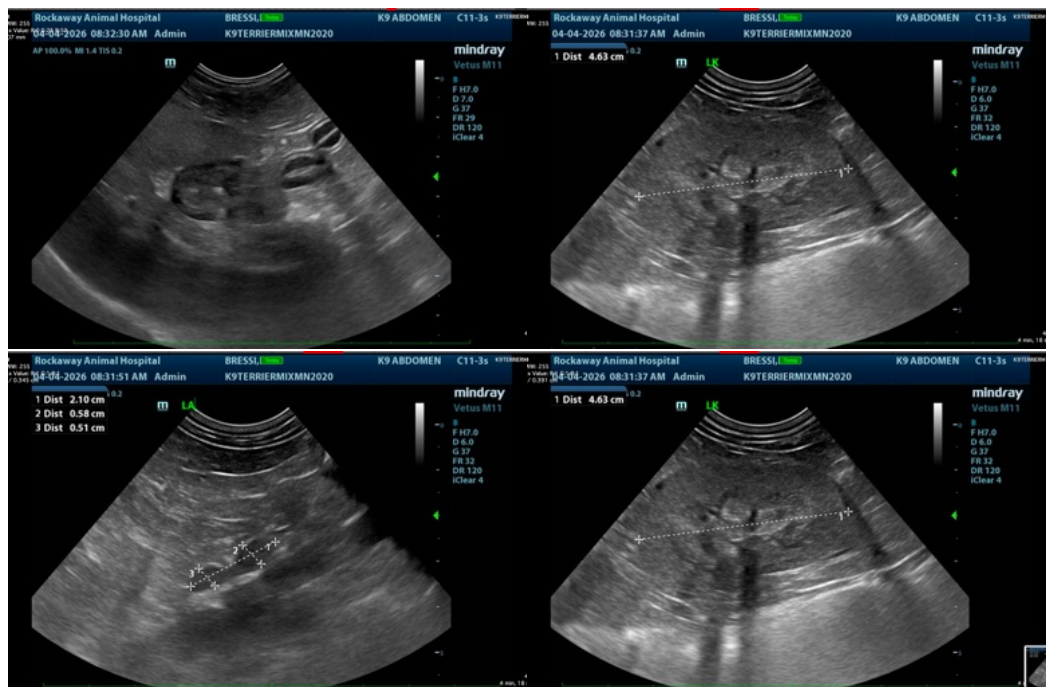
The **pancreas** was hypoechoic and irregular in the right base.

ULTRASONOGRAPHIC FINDINGS

- Gastritis.
- Minor pancreatitis pattern.

INTERPRETATION OF THE FINDINGS & FURTHER RECOMMENDATIONS

There were no residual foreign bodies noted. Medical management for gastritis and pancreatitis should prove effective.





PATIENT

Fin Bressi

SPECIES

Canine

BREED

Terrier Mix

SEX

Neutered male

AGE

6 years

WEIGHT

18.8 lbs

INTERPRETED BY

Eric Lindquist, DMV
DABVP, Cert. IVUSS

IMAGING PERFORMED BY

Jenn

HOSPITAL NAME

Rockaway AH

REFERRING VET

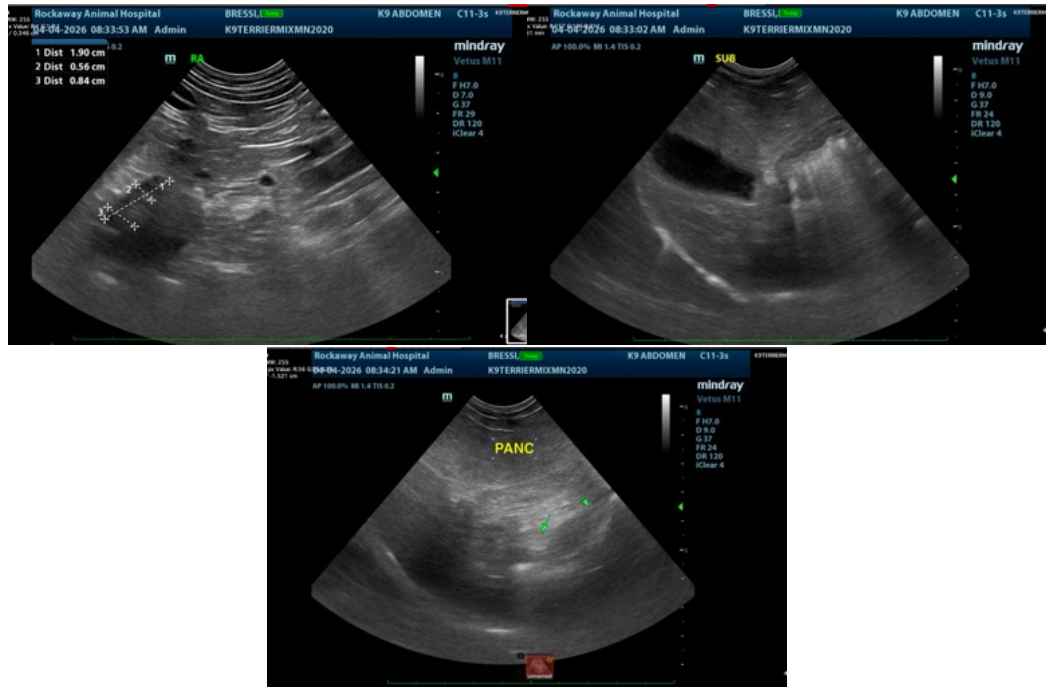
Dr. Maniar

INVOICE

74158

DATE

4/4/26



The information and recommendations provided are based on the images presented by the referring veterinarian/sonographer. No evaluation can be communicated regarding pathology that was not visible in the image/video clips provided.

Thank you for this referral. If the clinical or image interpretation does not parallel your findings or if I can be of any further assistance please contact me.

Eric Lindquist, DMV, DABVP, Cert. IVUSS, CEO of SonoPath.com

info@SonoPath.com