



PATIENT

Ranger Pandorf

SPECIES

Canine

BREED

Aussie Mix

SEX

Neutered male

AGE

3 years

WEIGHT

55 lbs

INTERPRETED BY

Eric Lindquist, DMV
DABVP, Cert. IVUSS

IMAGING PERFORMED BY

Jenn

HOSPITAL NAME

Rockaway AH

REFERRING VET

Dr. Maniar

INVOICE

43678

DATE

4/4/23

PRESENTING CLINICAL SIGNS

History: recheck from yesterday, full stomach with fluid no overt obstruction but delayed outflow noted

ULTRASONOGRAPHIC EXAMINATION OF THE ABDOMEN

Gastrointestinal

The **gastrointestinal tract** was empty in this patient. The curvilinear patterns were maintained. There was no evidence of residual luminal material. The small intestine and colon were unremarkable.

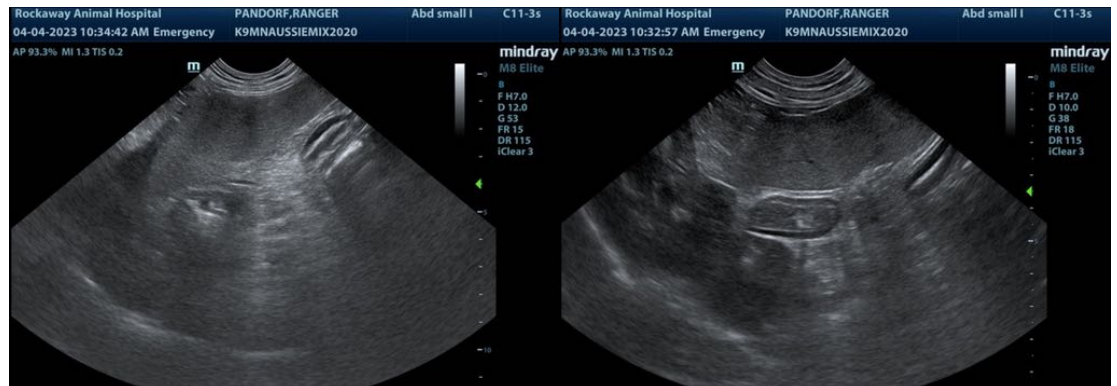
ULTRASONOGRAPHIC FINDINGS

Normalized GI tract.

No evidence of pathology.

INTERPRETATION OF THE FINDINGS & FURTHER RECOMMENDATIONS

There was complete resolution of the prior presentation.



The information and recommendations provided are based on the images presented by the referring veterinarian/sonographer. No evaluation can be communicated regarding pathology that was not visible in the image/video clips provided.

Thank you for this referral. If the clinical or image interpretation does not parallel your findings or if I can be of any further assistance please contact me.

Eric Lindquist, DMV, DABVP, Cert. IVUSS, CEO of SonoPath.com
info@SonoPath.com