



PATIENT

Brody Duren

SPECIES

Canine

BREED

Pomeranian Mix

SEX

Neutered male

AGE

14 years

WEIGHT

14.6 lbs

INTERPRETED BY

Eric Lindquist, DMV
DABVP, Cert. IVUSS

IMAGING PERFORMED BY

Jill Rumachik

HOSPITAL NAME

Clarity Imaging LLC

REFERRING VET

CC Sheldon

INVOICE

43699

DATE

4/4/23

PRESENTING CLINICAL SIGNS

History: Recheck echocardiogram recommended by Dr. Lindquist. Dx with stage B2 valvular dz and mitral insufficiency roughly 1-2 months ago and started on Pimobendan 1.875 mg BID. Has been doing well at home.

ULTRASONOGRAPHIC EXAMINATION OF THE HEART

The cardiac presentation revealed mild prolapse of the anterior mitral valve leaflet. The contractility and volumes were fairly contained with mild residual left atrial enlargement. There was no pericardial or pleural effusion. The right atrium and right ventricle were unremarkable. The pulmonary outflow tract was unremarkable.

CANINE CARDIAC PARAMETERS	MR VMAX (m/s)	TR VMAX (m/s)	LA/AO (Boon method)	LA/AO (Heart Base;)	FS (%)	EF (%)	EPSS (cm)
NORMAL PARAMETER	4.5-5.5	<2.7	1.3	<1.6	28-40	40-100	<0.6
PATIENT	>6.0		1.1		55		0.1
CANINE CARDIAC PARAMETERS	HR (BPM)	AV VMAX (m/s)	PV MAX (m/s)	BODY WEIGHT	LA 2D short axis Base view (cm)	LVIDd Avg; 2D and m- mode short axis (cm)	LVIDs Avg; 2D and m- mode short axis (cm)
NORMAL PARAMETER	50-100	0.7-1.7	0.7-1.6	BELOW	BELOW	BELOW	BELOW
PATIENT			0.8	14.6 lbs	3.7	3.57	

ULTRASONOGRAPHIC FINDINGS

Stable stage B2 valvular disease.

INTERPRETATION OF THE FINDINGS & FURTHER RECOMMENDATIONS

I recommend continuation of the current protocol with a recheck echocardiogram in 6 months. Blood pressure medications, sleeping respiratory rate and radiographs should all be monitored carefully.



PATIENT

Brody Duren

SPECIES

Canine

BREED

Pomeranian Mix

SEX

Neutered male

AGE

14 years

WEIGHT

14.6 lbs

INTERPRETED BY

Eric Lindquist, DMV
DABVP, Cert. IVUS

IMAGING PERFORMED BY

Jill Rumachik

HOSPITAL NAME

Clarity Imaging LLC

REFERRING VET

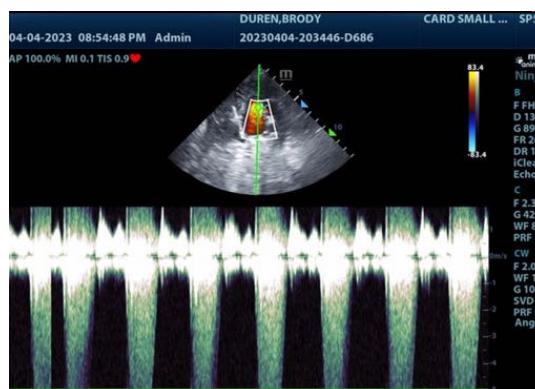
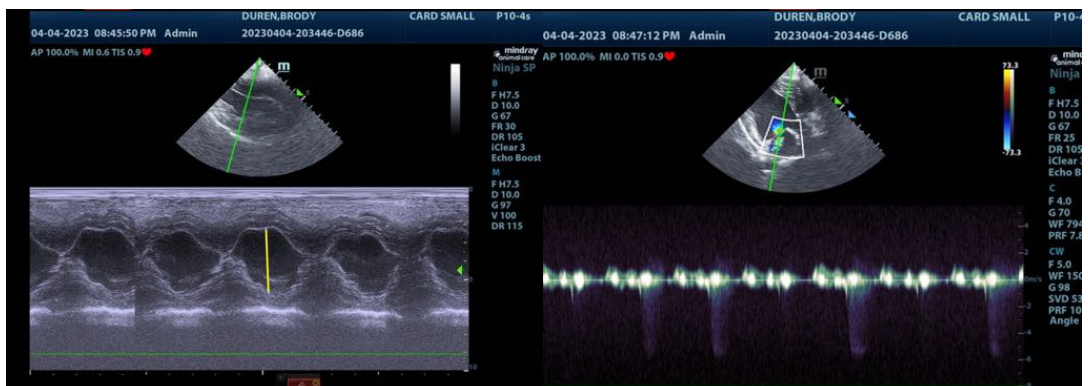
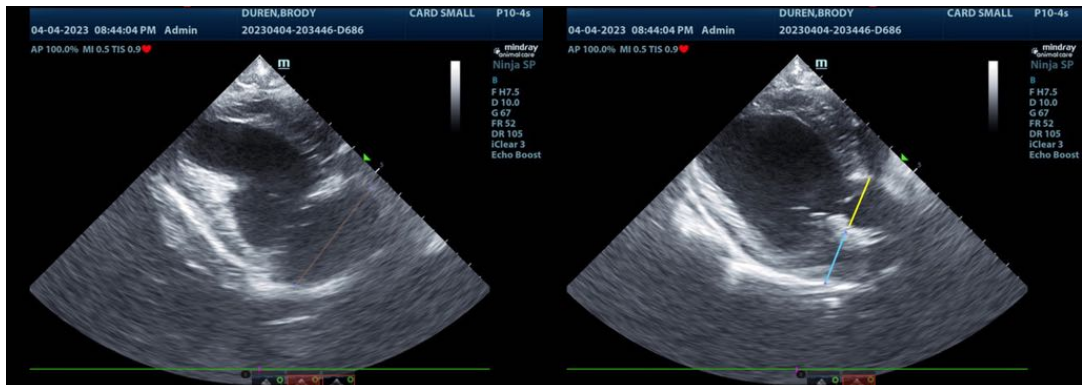
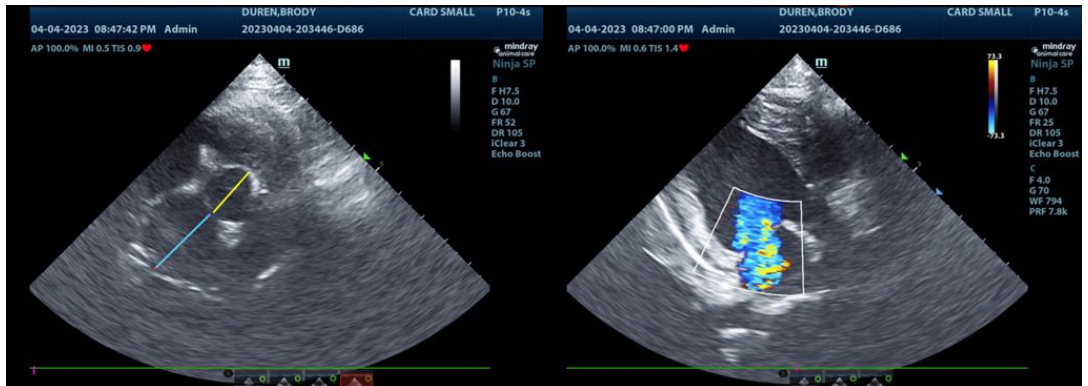
CC Sheldon

INVOICE

43699

DATE

4/4/23





PATIENT

Brody Duren

The information and recommendations provided are based on the images presented by the referring veterinarian/sonographer. No evaluation can be communicated regarding pathology that was not visible in the image/video clips provided.

SPECIES

Canine

Thank you for this referral. If the clinical or image interpretation does not parallel your findings or if I can be of any further assistance please contact me.

BREED

Pomeranian Mix

Eric Lindquist, DMV, DABVP, Cert. IVUSS, CEO of SonoPath.com
info@SonoPath.com

SEX

Neutered male

AGE

14 years

WEIGHT

14.6 lbs

INTERPRETED BY

Eric Lindquist, DMV
DABVP, Cert. IVUSS

**IMAGING
PERFORMED BY**

Jill Rumachik

HOSPITAL NAME

Clarity Imaging LLC

REFERRING VET

CC Sheldon

INVOICE

43699

DATE

4/4/23