



PATIENT

Bella Szollosy

SPECIES

Canine

BREED

Boxer

SEX

Spayed Female

AGE

8 Years

WEIGHT

52 Pounds

INTERPRETED BY

Eric Lindquist, DMV
DABVP, Cert. IVUSS

IMAGING PERFORMED BY

Jenn

HOSPITAL NAME

Rockaway AH

REFERRING VET

Dr. Maniar

INVOICE

14576

DATE

4/4/22

PRESENTING CLINICAL SIGNS

History: vomiting blood

ULTRASONOGRAPHIC EXAMINATION OF THE ABDOMEN

Urinary System

The **urinary bladder**, trigone, and pelvic urethra presented normal thicknesses and normal tone. The ureters were not visible which is normal. No uroliths or sediment were visualized, and anechoic urine was present. No evidence of inflammatory or neoplastic changes were noted. Ureteral papillae were normal.

The **kidneys** revealed normal size and structure, corticomedullary definition and ratio for this age. The cortices presented largely uniform texture with normal echogenic relationship to liver and spleen. Medullary structure differed distinctly from the cortex and no evidence of pelvic dilation was present. The capsules were acceptably uniform without significant irregularities. The left kidney measured 5.32 cm. The right kidney measured 5.4 cm.

Adrenal Glands

The **left adrenal gland** was visualized and recognized as having normal shape, size, position and echogenicity for this breed. The phrenic vasculature, glandular echogenicity and detail were unremarkable. Capsule, cortex, and medullary definition were normal for this age patient. The left adrenal gland measured 2.45 cm x 0.58 cm at the caudal pole and 0.71 cm at the cranial pole.

The region of the **right adrenal gland** was unremarkable.

Spleen

The **spleen** presented a smooth homogeneous parenchyma hyperechoic to liver and renal cortical parenchyma. The capsule was smooth without noticeable expansion or deviation from within the spleen or adjacent pathology. The splenic vasculature demonstrated normal volume without signs of congestion or thrombosis. No sonographic evidence of acute or chronic inflammatory, neoplastic, or infarctual changes were noted.

Liver

The **liver** images submitted revealed subjectively normal liver size, contour, and structure. Parenchymal echogenicity was naturally coarse and hypoechoic to the spleen. Vascular and biliary tracts were of normal volume with no evidence of congestion. The gallbladder presented acceptably thin walls with primarily anechoic content. The cystic and common bile ducts were normal. No pathological hepatic lymphadenopathy was evident. No overt structural evidence of inflammatory, infiltrative or regenerative pathology was evident.

Gastrointestinal

The **stomach** in this patient revealed concentric gastric mass. Wall thickness measured up to 2.0 cm. This is not resectable as both the lesser and greater curvature appears to be involved. Ultrasound guided FNA indicated to confirm suspicion of lymphoma or carcinoma. Minor potential for granulomatous disease. The small intestine and colon were unremarkable.

Pancreas



PATIENT

Bella Szollosy

The base and limbs of the **pancreas** were observed to be largely isoechoic to surrounding omental fat. Pancreatic duct and capsular contour were acceptably normal and parenchyma respected normal curvilinear patterns. No overt evidence of active inflammatory or neoplastic disease was noted.

SPECIES

Canine

Free Abdomen

The sublumbar **lymph nodes** were mildly enlarged, measuring up to 1.5 cm x 0.8 cm, reactive.

BREED

Boxer

ULTRASONOGRAPHIC FINDINGS

- Concentric gastric mass, infiltrative pattern, strongly suggestive for gastric lymphoma
- Sublumbar lymphadenopathy

SEX

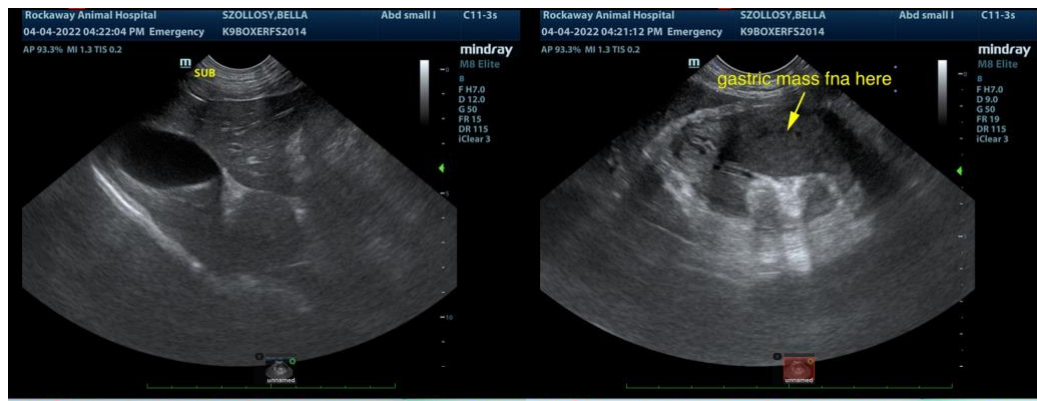
Spayed Female

INTERPRETATION OF THE FINDINGS & FURTHER RECOMMENDATIONS

FNA indicated.

AGE

8 Years

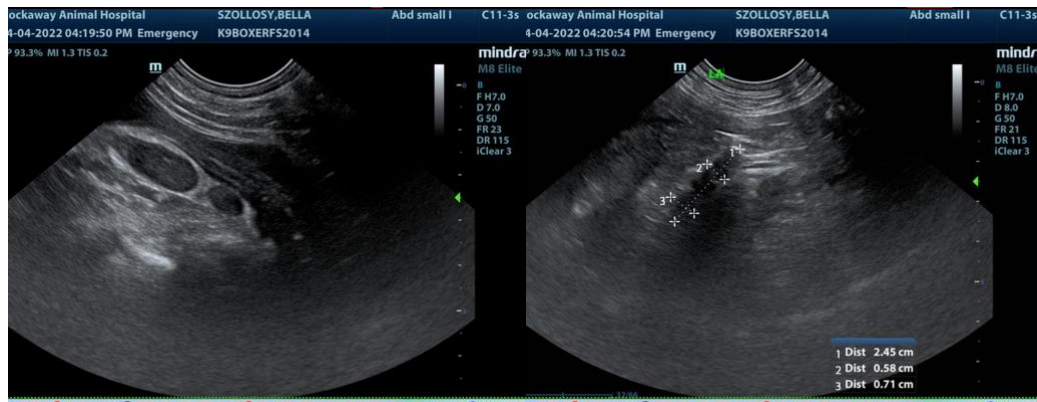


WEIGHT

52 Pounds

INTERPRETED BY

Eric Lindquist, DMV
DABVP, Cert. IVUSS



IMAGING PERFORMED BY

Jenn

HOSPITAL NAME

Rockaway AH

REFERRING VET

Dr. Maniar

INVOICE

14576

DATE

4/4/22



PATIENT

Bella Szollosy

SPECIES

Canine

BREED

Boxer

SEX

Spayed Female

AGE

8 Years

WEIGHT

52 Pounds

INTERPRETED BY

Eric Lindquist, DMV
DABVP, Cert. IVUSS

IMAGING PERFORMED BY

Jenn

HOSPITAL NAME

Rockaway AH

REFERRING VET

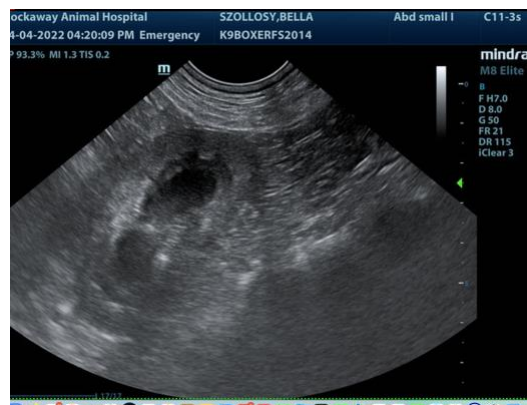
Dr. Maniar

INVOICE

14576

DATE

4/4/22




The information and recommendations provided are based on the images presented by the referring veterinarian. No evaluation can be communicated regarding pathology that was not visible in the image/video clips provided.

Thank you for this referral. If the clinical or image interpretation does not parallel your findings or if I can be of any further assistance please contact me.

Eric Lindquist, DMV, DABVP, Cert. IVUSS, CEO of SonoPath.com
info@SonoPath.com

The following is an applicable excerpt from the *Curbside Guide to Diagnosis & Treatment of Sonographic Disease* offered by [SonoPath.com](http://www.sonopath.com) Lindquist, Frank, Lobetti, and Modler.

An essential quick guide for every general practitioner and sonographer.



Canine Gastric Neoplasia

<http://www.sonopath.com/GastricNeoplasia>



PATIENT

Bella Szollosy

SPECIES

Canine

BREED

Boxer

SEX

Spayed Female

AGE

8 Years

WEIGHT

52 Pounds

INTERPRETED BY

Eric Lindquist, DMV
DABVP, Cert. IVUSS

IMAGING PERFORMED BY

Jenn

HOSPITAL NAME

Rockaway AH

REFERRING VET

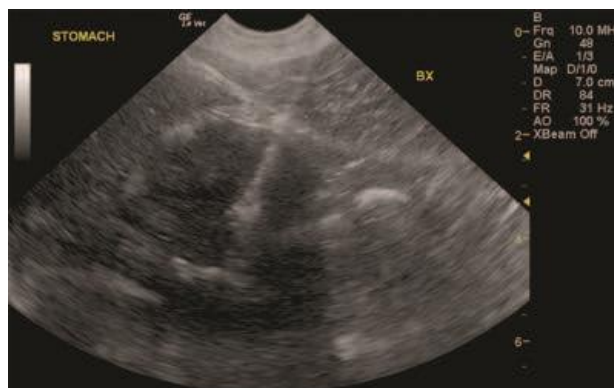
Dr. Maniar

INVOICE

14576

DATE

4/4/22



Short axis of the stomach in a dog with gastric lymphosarcoma during ultrasound guided biopsy. The automated core biopsy needle trajectory is seen as a hyperechoic line. Note the severe asymmetric circumferential wall thickening of the stomach with transmural loss of wall layering meets neoplastic criteria.

Description: Gastric neoplasia is uncommon in dogs, accounting for less than 1% of canine neoplasms. Up to 71% of malignant gastric tumors in dogs are adenocarcinomas and an additional 10% are due to lymphoma (LSA). Gastric LSA affects median age dogs of 6-7 years. Other primary gastric tumors include leiomyoma, leiomyosarcoma, extramedullary plasmacytoma, and fibrosarcoma. Although less common, metastasis to the stomach can occur secondary to adenocarcinomas, hemangiosarcomas, mast cell tumors, and LSA of other primary sites.

Clinical Signs: Gastric neoplasia incites nonspecific signs that are frequently seen either when gastrointestinal foreign bodies are present or with the following diseases: inflammatory bowel disease, pyloric stenosis, ulcerative disease, pythiosis, and viral GI disease. The most common signs associated with gastric neoplasia are chronic vomiting (particularly post-prandial), hematemesis weight loss, and anorexia; diarrhea and melena are also typical. Tenesmus and hematochezia may be observed in cases of large bowel involvement. Abdominal pain may also occur.

Diagnostics: Blood analysis results may be normal or indicate a spectrum of abnormalities. Gastric neoplasia may present with hypochromic microcytic anemia due to chronic blood loss; the latter can be confirmed by the presence of occult blood in the feces. Icterus may occur due to infiltrative post hepatic obstruction of the bile duct where it enters the duodenum. Hypochloremia and hypokalemia may be present in cases of protracted vomiting. Hypoproteinemia may occur if there is protein loss due to small bowel involvement or secondary to chronic blood loss in the stomach. A preliminary diagnosis of gastric neoplasia can be achieved by utilizing contrast radiography, ultrasonography, and endoscopy. Contrast radiographic studies may reveal mural thickening, filling defects, loss of normal rugal folds, and delayed pyloric outflow.

To achieve a definitive diagnosis, one must obtain a biopsy via laparotomy, an ultrasound-guided procedure, or endoscopy. Laparotomies are considered to be the most reliable means of arriving at a definitive diagnosis as they produce full thickness samples of the abnormal tissue. Less invasive sampling can frequently provide adequate tissue for a diagnosis via an ultrasound-guided needle biopsy or fine needle aspiration (FNA).



PATIENT

Bella Szollosy

SPECIES

Canine

BREED

Boxer

SEX

Spayed Female

AGE

8 Years

WEIGHT

52 Pounds

INTERPRETED BY

Eric Lindquist, DMV
DABVP, Cert. IVUSS

IMAGING PERFORMED BY

Jenn

HOSPITAL NAME

Rockaway AH

REFERRING VET

Dr. Maniar

INVOICE

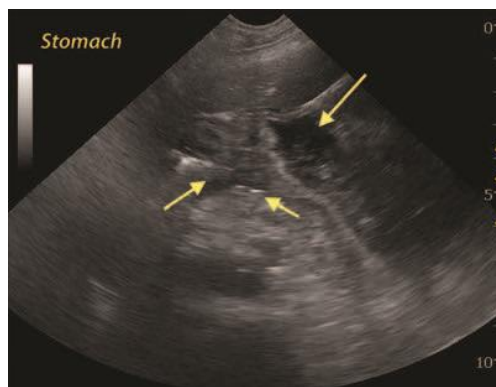
14576

DATE

4/4/22

Treatment: Specific treatment of gastric neoplasia depends on the diagnosis of the underlying tumor. Medical management should be oriented toward correcting the acid/base disturbances with fluid support, gastric protection (famotidine 0.5 mg/kg PO or IV BID, or omeprazole 0.7 mg/kg PO Q24hr as well as sucralfate 1 g PO TID at least 1 hour prior or after the ingestion of food and other medication), and anti-emetic therapy (maropitant citrate 1 mg/kg SC once daily for up to 5 days). Severe regenerative anemia secondary to ulcerative lesions is rare but may, when present, necessitate transfusion therapy. If a surgical bypass or partial gastric resection is performed, post-operative nutritional support should entail a bland, low-fat diet for the 24 hours following surgery in conjunction with anti-emetics and fluids comprised of a balanced electrolyte solution. Broad-spectrum antibiotics that are effective against *Helicobacter*, a common complicating factor, are indicated and may also be necessary during neutropenic episodes secondary to chemotherapy. Once a firm diagnosis of gastric neoplasia has been made, referral to a veterinary oncologist is appropriate.

Conclusion: Gastric adenocarcinoma carries a poor to grave prognosis; the disease is usually advanced by the time a diagnosis has been made. Gastric LSA has a variable prognosis, as do the other tumors that can occur in the stomach.



Long axis oblique view of the stomach (pyloric outflow) in a dog with gastric adenocarcinoma. Note the severe focal wall thickening with pseudolayering typical of adenocarcinoma (middle arrow). Also note the presence of hyperechoic gas (small arrow) outside the stomach and scant peritoneal effusion consistent with perforation as a sequel to the neoplastic infiltrate. Long arrow: gastric lumen and uid accumulation.

References:

Guilford WG, Strombeck DR. Neoplasms of the gastrointestinal tract, APUD tumors, endocrinopathies and the gastrointestinal tract. In: Guilford WG, Center SA,

Strombeck DR, Williams DA and Meyer DJ, eds: *Strombeck's Small Animal Gastroenterology 3rd ed.* Philadelphia: WB Saunders, 1996:519-31.

Lamb C, Grierson J. Ultrasonographic appearance of primary gastric neoplasia in 21 dogs. *J Small Anim Pract* 1999;40(5):211-15.

Magne ML. Gastrointestinal neoplasia. In: Bonagura JD, ed: *Kirk's Current Veterinary Therapy XIII: Small Animal Practice.* Philadelphia: WB Saunders, 2000: 622-24.



PATIENT

Bella Szollosy

Marks S. Update on canine and feline gastrointestinal neoplasia. Proceedings from the World Small Animal Veterinary Association World Congress, Vancouver, BC, 2001.

SPECIES

Canine

Pennick D. Characterization of gastrointestinal tumors. *Vet Clin North Am Small Anim Pract* 1998;28(4):777-95.

BREED

Boxer

SEX

Spayed Female

AGE

8 Years

WEIGHT

52 Pounds

INTERPRETED BY

Eric Lindquist, DMV
DABVP, Cert. IVUSS

**IMAGING
PERFORMED BY**

Jenn

HOSPITAL NAME

Rockaway AH

REFERRING VET

Dr. Maniar

INVOICE

14576

DATE

4/4/22