



PATIENT PRESENTING CLINICAL SIGNS

Bella Moss History: re check doing well at home eating and active

SPECIES LIMITED ULTRASONOGRAPHIC EXAMINATION

Canine The spleen revealed persistent micronodular changes yet stable. No progression from the prior sonogram. Age-related hepatic and renal changes present. Slight renal mineralization noted. The adrenal glands were normal and stable. The gastrointestinal tract was unremarkable.

BREED ULTRASONOGRAPHIC FINDINGS

Chihuahua

- Stable geriatric abdomen with undefined nodular splenic changes

SEX INTERPRETATION OF THE FINDINGS & FURTHER RECOMMENDATIONS

Spayed Female Given that no clinical signs are present, and the patient is not losing weight, then pronounced splenic hyperplasia is likely. No specific therapy warranted.

AGE

12 Years

WEIGHT

7.6 Pounds

INTERPRETED BY

Eric Lindquist, DMV
DABVP, Cert. IVUSS

IMAGING PERFORMED BY

Jenn

HOSPITAL NAME

Rockaway AH

REFERRING VET

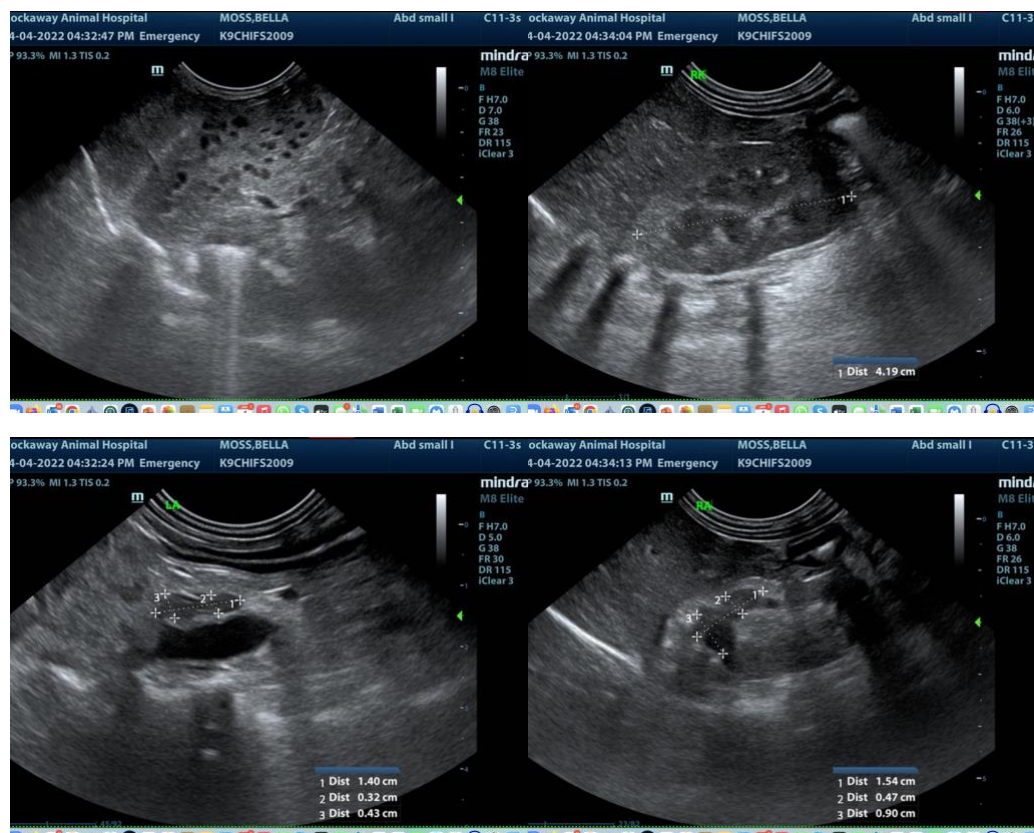
Dr. Maniar

INVOICE

14575

DATE

4/4/22





PATIENT

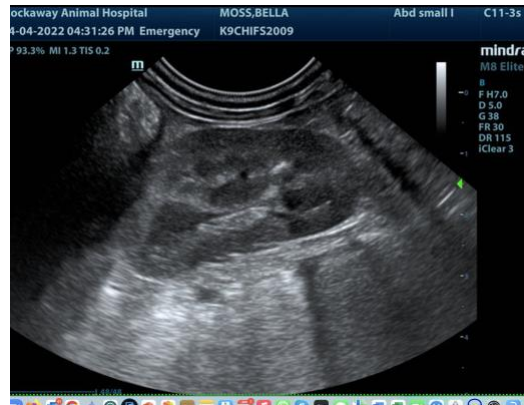Bella Moss

SPECIES

Canine

BREED

Chihuahua



SEX

Spayed Female

The information and recommendations provided are based on the images presented by the referring veterinarian. No evaluation can be communicated regarding pathology that was not visible in the image/video clips provided.

AGE

12 Years

Thank you for this referral. If the clinical or image interpretation does not parallel your findings or if I can be of any further assistance please contact me.

WEIGHT

7.6 Pounds

Eric Lindquist, DMV, DABVP, Cert. IVUSS, CEO of SonoPath.com
info@SonoPath.com

INTERPRETED BY

Eric Lindquist, DMV
DABVP, Cert. IVUSS

IMAGING PERFORMED BY

Jenn

HOSPITAL NAME

Rockaway AH

REFERRING VET

Dr. Maniar

INVOICE

14575

DATE

4/4/22