SonoPath
Clinical Sonography & Telecytology

EDUCATIONAL TELECONSULTATION SERVICES™

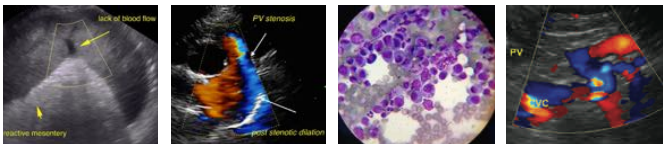

SonoPath.com™
1-800-838-4268 info@sonopath.com

PATIENT

Bella Montano

SPECIES

Ferret

BREED

SEX

Female

AGE

8 years

WEIGHT

0.5 kg

INTERPRETED BY

Eric Lindquist, DMV
DABVP, Cert. IVUSS

IMAGING PERFORMED BY

Dr. Wiley

HOSPITAL NAME

Petvacx AH

REFERRING VET

Dr. Wiley

INVOICE

98021

DATE

4/4/22

PRESENTING CLINICAL SIGNS

History: 2 d history of inappetence, hind in weakness, lethargy.
Abnormal PE/Chem/CBC/UA Results: Swollen vulva on exam, hair loss at hind end. BCS 2/9. 8% dehydrated. Infection in mouth. CBC/CHEM/Androgen panel pending. Blood Glucose 40.

ULTRASONOGRAPHIC EXAMINATION OF THE ABDOMEN

Urinary System

The **urinary bladder**, trigone, and pelvic urethra presented normal thicknesses and normal tone. The pelvic urethra was imaged 1.0 cm beyond the cystourethral junction. The ureters were not visible which is normal. No uroliths or sediment were visualized and anechoic urine was present. No evidence of inflammatory or neoplastic changes was noted. Ureteral papillae were normal.

The **left kidney** presented a relatively uniform cortical hyperechogenicity when compared to the renal medulla, spleen and liver. No overt masses were noted. Corticomedullary definition was nebulous and the ratio favored the cortex slightly. The ureters were not visible and assumed to be normal. These changes are most consistent with chronic interstitial nephritis yet infiltrative disease could not be entirely ruled out without biopsy though neoplasia is not suspected. The left kidney was subnormal in size with minor pyelectasia. The left kidney measured 2.0 cm with slight pinpoint mineralization. The right kidney was similar to the left kidney and measured 2.0 cm with slight pyelectasia, cortical infarcts and remodeling.

Adrenal Glands

The left **adrenal gland** was uniform and measured 0.4 cm. The right adrenal gland was enlarged, irregular and swollen without vascular invasion. The right adrenal gland measured 0.6 x 1.1 cm.

Spleen

The **spleen** presented a smooth homogeneous parenchyma hyperechoic to liver and renal cortical parenchyma. The capsule was smooth without noticeable expansion or deviation from within the spleen or adjacent pathology. The splenic vasculature demonstrated normal volume without signs of congestion or thrombosis. No sonographic evidence of acute or chronic inflammatory, neoplastic, or infarctual changes was noted.

Liver

The **liver** images from right and left intercostal as well as subcostal views revealed subjectively normal liver size, contour, and structure. Some age-related parenchymal remodeling was noted but likely not clinically significant at this time. Vascular and biliary tracts were of normal volume and no evidence of congestion was noted. The gallbladder presented some dependent debris with essentially normal contour. The cystic and common bile ducts were normal. No overt evidence of active inflammatory, infiltrative or regenerative pathology was noted but should be paired with current or past LE elevations regarding any clinical significance to this presentation. The hepatic lymph nodes were unremarkable.

SonoPath
Clinical Sonography & Telecytology

EDUCATIONAL TELECONSULTATION SERVICES™

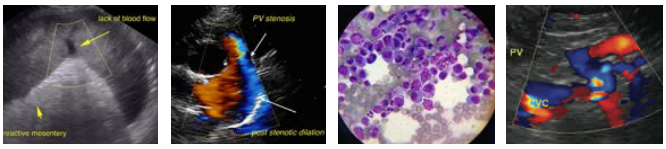

SonoPath.com™
1-800-838-4268 info@sonopath.com

PATIENT

Bella Montano

SPECIES

Ferret

BREED

SEX

Female

AGE

8 years

WEIGHT

0.5 kg

INTERPRETED BY

Eric Lindquist, DMV
DABVP, Cert. IVUSS

IMAGING PERFORMED BY

Dr. Wiley

HOSPITAL NAME

Petvacx AH

REFERRING VET

Dr. Wiley

INVOICE

98021

DATE

4/4/22

Gastrointestinal

Examination of the **gastrointestinal tract** revealed a stomach and intestine free of stasis, of normal wall thickness, acceptable curvilinear mural detail, and peristaltic activity. Small and large intestine demonstrated normal luminal chyme and stool consistency respectively. No obstructive or overt infiltrative disease was noted. No associated abnormal lymphatic activity was noted.

Pancreas

The base and limbs of the **pancreas** were observed to be largely isoechoic to surrounding omental fat. Pancreatic duct and capsular contour were acceptably normal and parenchyma respected normal curvilinear patterns. No overt evidence of active inflammatory or neoplastic disease was noted.

ULTRASONOGRAPHIC FINDINGS

Enlarged right adrenal gland.

Chronic interstitial nephrosis renal pattern with mineralization.

INTERPRETATION OF THE FINDINGS & FURTHER RECOMMENDATIONS

Regarding the adrenal signs with hair loss, this is likely owing to the right adrenal gland. There was no overt evidence of insulinoma present. However, a small insulinoma cannot be ruled out. The kidneys are concerning for end stage disease.

SonoPath

Clinical Sonography & Telecytology

EDUCATIONAL TELECONSULTATION SERVICES™

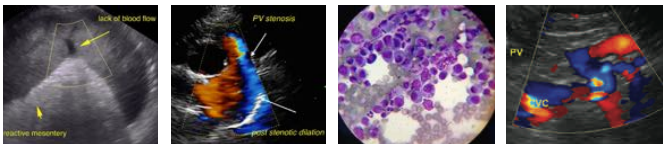

SonoPath.com™
1-800-838-4268 info@sonopath.com

PATIENT

Bella Montano

SPECIES

Ferret

BREED

SEX

Female

AGE

8 years

WEIGHT

0.5 kg

INTERPRETED BY

Eric Lindquist, DMV
DABVP, Cert. IVUSS

IMAGING PERFORMED BY

Dr. Wiley

HOSPITAL NAME

Petvacx AH

REFERRING VET

Dr. Wiley

INVOICE

98021

DATE

4/4/22

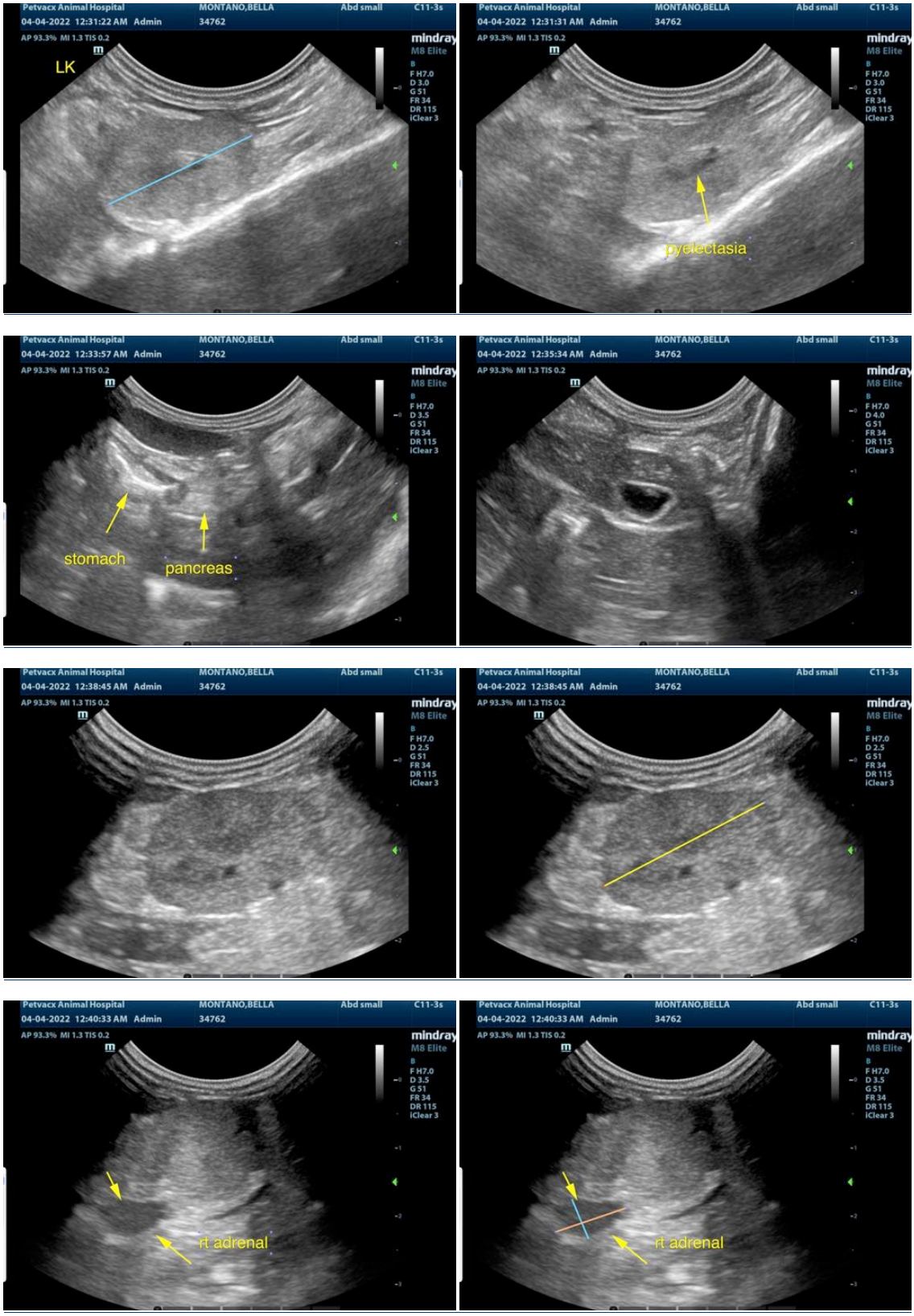

SonoPath
Clinical Sonography & Telecytology

EDUCATIONAL TELECONSULTATION SERVICES™

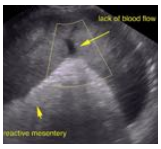

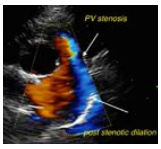

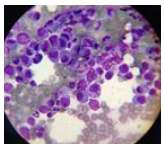
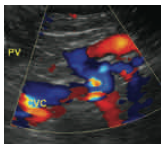

SonoPath.com™
1-800-838-4268 info@sonopath.com

PATIENT

Bella Montano

SPECIES

Ferret

BREED

SEX

Female

AGE

8 years

WEIGHT

0.5 kg

INTERPRETED BY

Eric Lindquist, DMV
DABVP, Cert. IVUSS

IMAGING PERFORMED BY

Dr. Wiley

HOSPITAL NAME

Petvacx AH

REFERRING VET

Dr. Wiley

INVOICE

98021

DATE

4/4/22

The information and recommendations provided are based on the images presented by the referring veterinarian/sonographer. No evaluation can be communicated regarding pathology that was not visible in the image/video clips provided.

Thank you for this referral. If the clinical or image interpretation does not parallel your findings or if I can be of any further assistance please contact me.

Eric Lindquist, DMV, DABVP, Cert. IVUSS, CEO of SonoPath.com
info@SonoPath.com