



PATIENT

Sierra Lawson

SPECIES

Canine

BREED

Chihuahua

SEX

Spayed female

AGE

11 years

WEIGHT

15.6 lbs

INTERPRETED BY

Eric Lindquist, DMV
DABVP, Cert. IVUSS

IMAGING PERFORMED BY

Ian Anderson

HOSPITAL NAME

Chester Animal Clinic

REFERRING VET

Dr. Feiring

INVOICE

75035

DATE

4/30/26

PRESENTING CLINICAL SIGNS

History: Mild PU/PD upon direct questioning, otherwise no clinical signs of Cushing's at home; routine screening lab work was performed
ALT mildly elevated, 160 IU/L, ALKP moderately elevated with 629 IU/L moderately elevated PSL, 404 U/L. Moderate thrombocytosis, $807 \times 10^3/uL$. UA: USG 1.018 and 2+ protein.

ULTRASONOGRAPHIC EXAMINATION OF THE ABDOMEN

Urinary System

The **urinary bladder**, trigone, and pelvic urethra presented normal thicknesses and normal tone. The ureters were not visible which is normal. No uroliths or sediment were visualized and anechoic urine was present. No evidence of inflammatory or neoplastic changes was noted. Ureteral papillae were normal.

The **kidneys** revealed normal size and structure, corticomedullary definition and ratio for this age. The cortices presented largely uniform texture with normal echogenic relationship to liver and spleen. Medullary structure differed distinctly from the cortex and no evidence of pelvic dilation was present. The capsules were acceptably uniform without significant irregularities. The left kidney measured 4.2 cm. The right kidney measured 4.4 cm.

The uterine stump was excessively long and extended the body of the bladder, yet was empty with no evidence of inflammation.

Adrenal Glands

The **left adrenal gland** was enlarged and swollen measuring 0.87 cm at the caudal pole and 0.8 cm at the cranial pole. There was capsular expansion without capsular escape was noted.

The **right adrenal gland** was at the upper limits of normal measuring 0.85 cm at the cranial pole and 0.51 cm at the caudal pole.

Spleen

The **spleen** presented a smooth homogeneous parenchyma hyperechoic to liver and renal cortical parenchyma. The capsule was smooth without noticeable expansion or deviation from within the spleen or adjacent pathology. The splenic vasculature demonstrated normal volume without signs of congestion or thrombosis. No sonographic evidence of acute or chronic inflammatory, neoplastic, or infarctual changes was noted.

Liver

The **liver** images submitted revealed subjectively normal liver size, contour, and structure. Parenchymal echogenicity was naturally coarse and hypoechoic to the spleen. Vascular and biliary tracts were of normal volume with no evidence of congestion. The gallbladder presented acceptably thin walls with



PATIENT

Sierra Lawson

primarily anechoic content. The cystic and common bile ducts were normal. No pathological hepatic lymphadenopathy was evident. No overt structural evidence of inflammatory, infiltrative or regenerative pathology was evident.

SPECIES

Canine

Gastrointestinal

BREED

Chihuahua

Examination of the **gastrointestinal tract** revealed a stomach and intestine free of stasis, of normal wall thickness, acceptable curvilinear mural detail, and peristaltic activity. Small and large intestine demonstrated normal luminal chyme and stool consistency respectively. No obstructive or overt infiltrative disease was noted. No associated abnormal lymphatic activity was noted.

SEX

Spayed female

Pancreas

AGE

11 years

The base and limbs of the **pancreas** were observed to be largely isoechoic to surrounding omental fat. Pancreatic duct and capsular contour were acceptably normal and parenchyma respected normal curvilinear patterns. No overt evidence of active inflammatory or neoplastic disease was noted.

WEIGHT

15.6 lbs

ULTRASONOGRAPHIC FINDINGS

INTERPRETED BY

Eric Lindquist, DMV
DABVP, Cert. IVUSS

Enlarged left adrenal

Upper limits of normal in the right adrenal gland

IMAGING PERFORMED BY

Ian Anderson

INTERPRETATION OF THE FINDINGS & FURTHER RECOMMENDATIONS

There is a strong concern for Cushing's, likely PDH. However, emerging neoplasia of the left adrenal gland cannot be ruled out. Cushing's work-up is recommended. Recheck sonogram of the adrenal glands are recommended to ensure that morphology is not progressively changing.

HOSPITAL NAME

Chester Animal Clinic

Efficient & Accurate Cushing's Work up-Lindquist

REFERRING VET

Dr. Feiring

Notes regarding Cushing's Clinical Presentations:

Nearly all Cushing's dogs have SAP elevations and true PU/PD (USG < 1.025) and most are polyphagic.

INVOICE

75035

Cushing's dogs are > 6 years and usually > 9 years old, usually have poor skin coats, body scores > 3/5, and are usually sedentary animals.

DATE

4/30/26

Its important to remember that Cushing's dogs usually look and play the part and other diseases cause false + stress related cortisol spikes. On rare occasion a Cushing's dog will not follow the rules but this is truly an exception.

Potential Cushing's patient workups can be costly and frustrating if not definitive and, in my experience, the non-definitive patient usually has something else going on that may be contributing to some of the clinical signs a Cushing's dog will have, especially SAP elevations or PU/PD. Based on this prelude of information I came up with the following algorithm in the spirit of diagnostic efficiency.



PATIENT

Sierra Lawson

The following suggested protocol is based on current available literature on Cushing's disease and extensive clinical-sonographic experience evaluation + Cushing's and False + LDDST & ACTH stim. cases in order to maximize the efficiency of a Cushing's workup in practice.

SPECIES

Canine

Screen first, workup second

1) **UA:** Repeatable (2-3 urine samples) Urine specific gravity & urine cortisol/creatinine ratio (UCCR): If **repeatable USG < 10.20 and + UCCR** move to next step 2.

BREED

Chihuahua

Note: UA is inexpensive and easy to obtain and if UA criteria is not met for Cushing's then resources can be spent into other more pertinent diagnostics or left on hold until the UA criteria is met in emerging Cushing's cases.

SEX

Spayed female

2) **Sonogram:** Does the patient **have concurrent disease** clinically or sonographically as non-Cushing's illness will influence the potential false + LDDST or even ACTH stim. The sonogram gives a global perspective of the internal health of the patient to be considered in the Cushing's workup as an assessment of concurrent disease. Is there a concurrent neoplastic process, UTI pancreatitis, mucocele...? Are the adrenals enlarged (Cushing's-PDH, stress, age related or breed variant), or atrophied (iatrogenic Cushing's or adrenal burnout), have asymmetric enlargement (Adrenal tumor, hyperplasia, adenoma, age related variant), or is there vascular invasion (Invasive pheo with false + UA criteria or adenocarcinoma or phrenic thrombosis)? The sonogram answers these questions proactively.

AGE

11 years

WEIGHT

15.6 lbs

Address & treat concurrent disease first before performing Cushing's testing or testing will be artificially altered increasing false negatives and positives.

INTERPRETED BY

Eric Lindquist, DMV
DABVP, Cert. IVUSS

3) **LDDST** (0.01 D-Sodium phosphate mg/kg IV **with precise dosing******) (Better screening test but plagued with false + but considered more specific than ACTH stim) Use if there is potential early Cushing's or if adrenal asymmetry present on sonogram suspecting tumor. Use LDDST in cats at a higher dose (0.1 mg/kg IV). **Interpretation LDDST:** Look at 8-hour post first: If > 1.4 = Cushing's. Then look at 4-hour: if > 1.4 or > 50% baseline = Cushing's. 4-hour do then 8-hour spike most consistent with PDH. Flat line high constant curve without dip more consistent with tumor but can be PDH. See attached graph.

IMAGING PERFORMED BY

Ian Anderson

HOSPITAL NAME

Chester Animal Clinic

REFERRING VET

Dr. Feiring

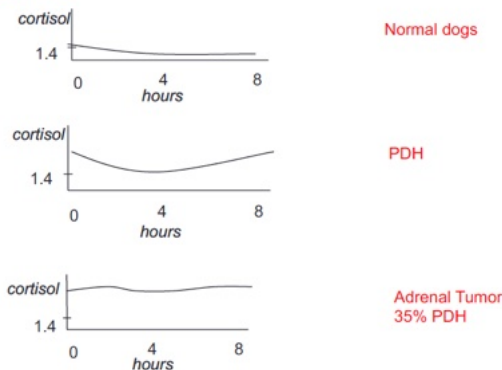
INVOICE

75035

DATE

4/30/26

LDDS



Courtesy: Rebecca Berg DACVIM, DECVIM



PATIENT

Sierra Lawson

SPECIES

Canine

BREED

Chihuahua

SEX

Spayed female

AGE

11 years

WEIGHT

15.6 lbs

INTERPRETED BY

Eric Lindquist, DMV
DABVP, Cert. IVUSS

IMAGING PERFORMED BY

Ian Anderson

HOSPITAL NAME

Chester Animal Clinic

REFERRING VET

Dr. Feiring

INVOICE

75035

DATE

4/30/26

4) **ACTH stim.** (Better confirming test but can have false +) Use if the patient “looks” Cushingoid or if bilateral adrenal enlargement is present, or high normal width on sonogram, or if iatrogenic Cushing’s suspected (Cortisone Tx in past). ACTH stim is better for diagnosis of Addison’s, Iatrogenic Cushing’s, and Cushing’s therapy monitoring but problematic with initial Cushing’s diagnosis. First dx LDDST is suggested.

5) If **diabetic** then run both LDDST & ACTH stim but stabilize as much as possible first.

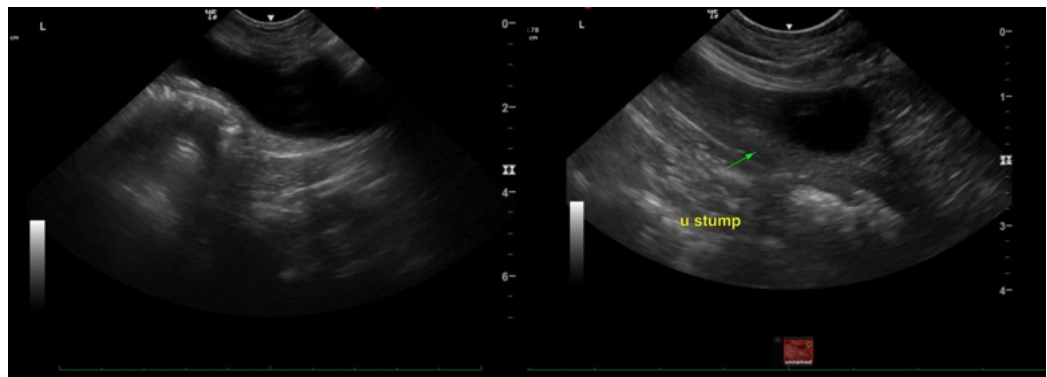
5) Run a **serial blood pressure** in a BP friendly non “white coat effect” atmosphere. Run at least 3 at different times over a few hours or when eating as the patient tends to be calm when eating or give Torbutrol when entering the facility. Cushing’s hypertension is usually 150-180 systolic range while pheochromocytoma range is more often > 180 systolic.

6) **Perform CT** of the pituitary to identify macro adenoma expansion if any lethargy or dullness or other central clinical CNS signs are minimally present. CT for adrenal may be more thorough for adrenalectomy surgical planning if ultrasound views of the CVC were problematic.

7) **Adrenectomy** for adrenal mass is prescribed then it is essential to stabilize the patient first regarding secondary disease such as organ dysfunction, hypertension, diabetes mellitus, hypernatremia, thromboembolic risk urinary and other infection in order to minimize potential for operative and postoperative complications as they are common in adrenalectomy. Trilostane stabilization therapy for Cushing’s would be the first approach then address surgery and hypertension should be managed ideally < 160 systolic with ace inhibitors, phenoxybenzamine, or amlodipine.

Suggested reading:

Behrend EN, Kooistra HS, Nelson R, et al. Diagnosis of Spontaneous Canine Hyperadrenocorticism: 2012 ACVIM Consensus Statement (Small Animal). J Vet Intern Med 2013;27:1292-1304.





PATIENT

Sierra Lawson

SPECIES

Canine

BREED

Chihuahua

SEX

Spayed female

AGE

11 years

WEIGHT

15.6 lbs

INTERPRETED BY

Eric Lindquist, DMV
DABVP, Cert. IVUSS

IMAGING PERFORMED BY

Ian Anderson

HOSPITAL NAME

Chester Animal Clinic

REFERRING VET

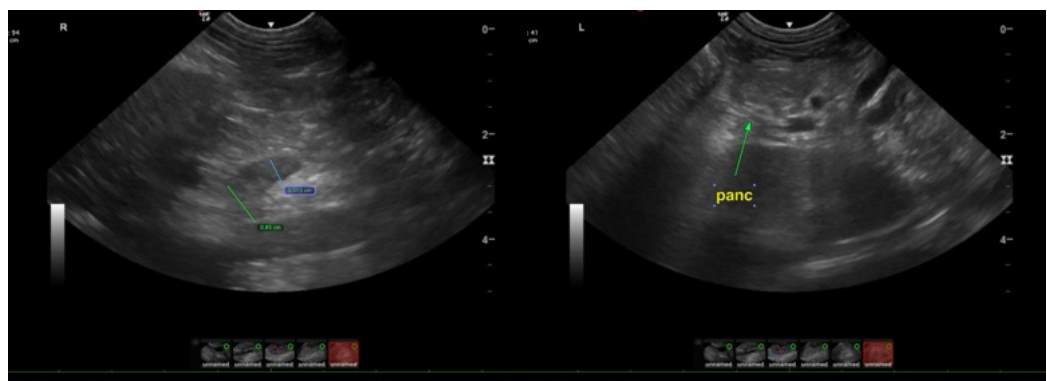
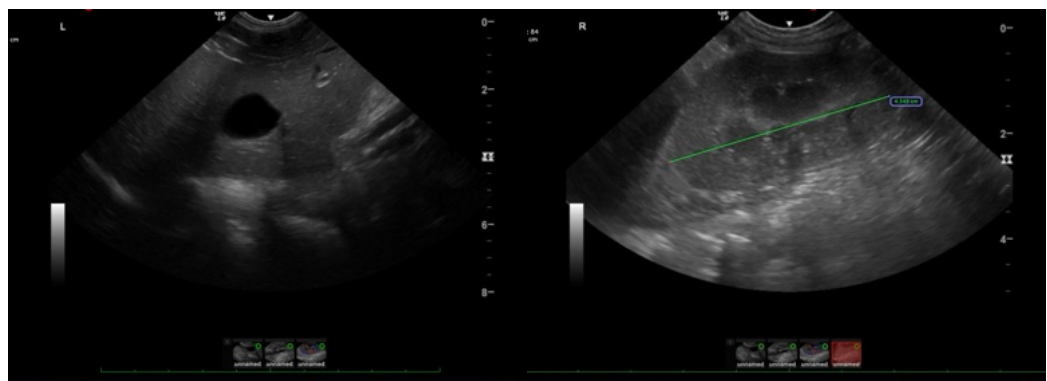
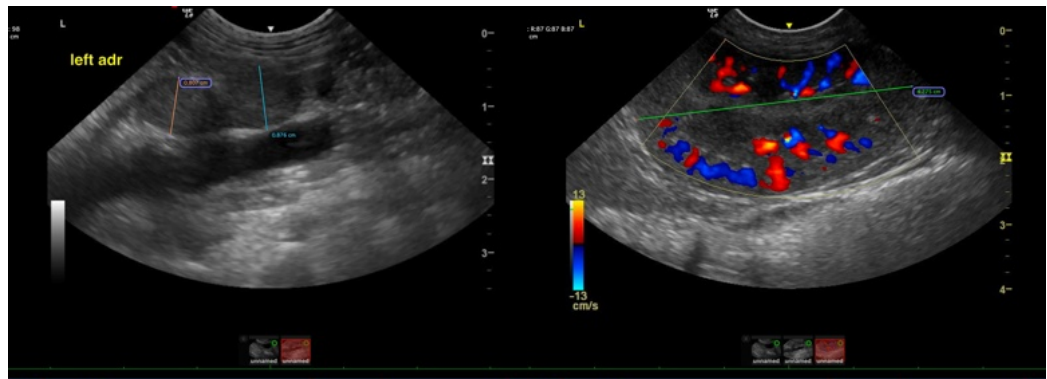
Dr. Feiring

INVOICE

75035

DATE

4/30/26



The information and recommendations provided are based on the images presented by the referring veterinarian/sonographer. No evaluation can be communicated regarding pathology that was not visible in the image/video clips provided.

Thank you for this referral. If the clinical or image interpretation does not parallel your findings or if I can be of any further assistance please contact me.

Eric Lindquist, DMV, DABVP (CFM), Cert. IVUSS, CEO of SonoPath.com

info@SonoPath.com