



PATIENT

Max Isenberg

SPECIES

Canine

BREED

Dachshund Mix

SEX

Neutered male

AGE

9 years

WEIGHT

20 lbs

INTERPRETED BY

Eric Lindquist, DMV
DABVP, Cert. IVUSS

IMAGING PERFORMED BY

Sara Crawford

HOSPITAL NAME

Countryside VS
Champion

REFERRING VET

Dr. Crawford

INVOICE

75061

DATE

4/30/26

PRESENTING CLINICAL SIGNS

History: Recent potential history of not eating regular dog food. Has been eating high value items such as jerky. Vomited once but not repeated and is drinking. Owners stated patient was not urinating but that is in question?

Abnormal PE/Chem/CBC/UA Results: CBC--WNL Chem--Phos L 2.2, TP H 7.8, Alb H 4.0, ALP H 367 T4--L 0.8 Spec cPL--WNL U/A--pH H 8.5, Prot 1+, RBC 3+, RBC H 75-100/HPF, Amorphous crystals present (urine collected via cystocentesis)

ULTRASONOGRAPHIC EXAMINATION OF THE ABDOMEN

Urinary System

The **urinary bladder**, trigone, and pelvic urethra presented normal thicknesses and normal tone. The ureters were not visible which is normal. No uroliths or sediment were visualized and anechoic urine was present. No evidence of inflammatory or neoplastic changes was noted. Ureteral papillae were normal.

The **kidneys** revealed normal size and structure, corticomedullary definition and ratio for this age. The cortices presented largely uniform texture with normal echogenic relationship to liver and spleen. Medullary structure differed distinctly from the cortex and no evidence of pelvic dilation was present. The capsules were acceptably uniform without significant irregularities.

Adrenal Glands

Both **adrenal glands** were visualized and recognized as having normal shape, size, position and echogenicity for this breed. The phrenic vasculature, glandular echogenicity and detail were unremarkable. Capsule, cortex, and medullary definition were normal for this age patient. The left adrenal gland measured 0.67 cm. The right kidney measured 5.0 cm.

Spleen

The **spleen** presented a smooth homogeneous parenchyma hyperechoic to liver and renal cortical parenchyma. The capsule was smooth without noticeable expansion or deviation from within the spleen or adjacent pathology. The splenic vasculature demonstrated normal volume without signs of congestion or thrombosis. No sonographic evidence of acute or chronic inflammatory, neoplastic, or infarctual changes was noted.

Liver

The **liver** images submitted revealed subjectively normal liver size, contour, and structure. Parenchymal echogenicity was naturally coarse and hypoechoic to the spleen. Vascular and biliary tracts were of normal volume with no evidence of congestion. The gallbladder presented acceptably thin walls with primarily anechoic content. The cystic and common bile ducts were normal. No pathological hepatic



PATIENT

Max Isenberg

SPECIES

Canine

BREED

Dachshund Mix

SEX

Neutered male

AGE

9 years

WEIGHT

20 lbs

INTERPRETED BY

Eric Lindquist, DMV
DABVP, Cert. IVUSS

IMAGING PERFORMED BY

Sara Crawford

HOSPITAL NAME

Countryside VS
Champion

REFERRING VET

Dr. Crawford

INVOICE

75061

DATE

4/30/26

lymphadenopathy was evident. No overt structural evidence of inflammatory, infiltrative or regenerative pathology was evident.

Gastrointestinal

Examination of the **gastrointestinal tract** revealed a stomach and intestine free of stasis, of normal wall thickness, acceptable curvilinear mural detail, and peristaltic activity. A large amount of gastric gas and artifact is noted in the upper GI tract. Small and large intestine demonstrated normal luminal chyme and stool consistency respectively. No obstructive or overt infiltrative disease was noted. No associated abnormal lymphatic activity was noted.

Pancreas

The base and limbs of the **pancreas** were observed to be largely isoechoic to surrounding omental fat. Pancreatic duct and capsular contour were acceptably normal and parenchyma respected normal curvilinear patterns. No overt evidence of active inflammatory or neoplastic disease was noted.

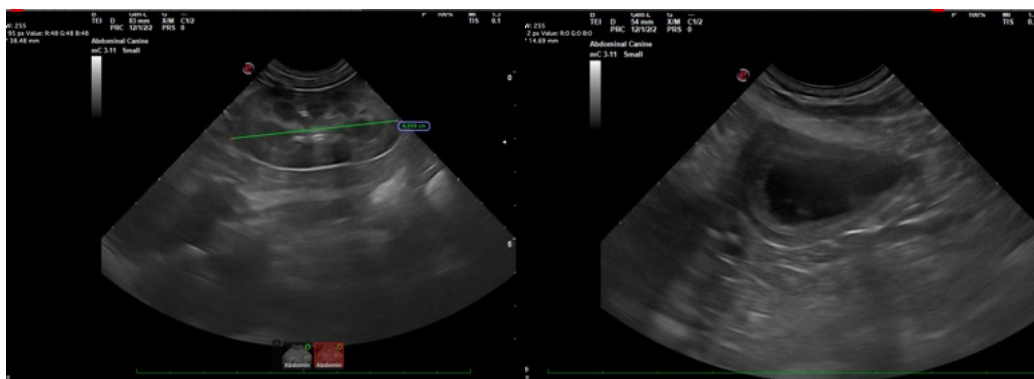
ULTRASONOGRAPHIC FINDINGS

Structurally unremarkable abdomen.

Benign abdominal changes, there was no evidence of significant disease.

INTERPRETATION OF THE FINDINGS & FURTHER RECOMMENDATIONS

Gastric gas artifact noted in the upper gastrointestinal may be obscuring more significant pathology. If clinical signs persist then I recommend a recheck sonogram at complete n.p.o. status.





PATIENT

Max Isenberg

SPECIES

Canine

BREED

Dachshund Mix

SEX

Neutered male

AGE

9 years

WEIGHT

20 lbs

INTERPRETED BY

Eric Lindquist, DMV
DABVP, Cert. IVUSS

IMAGING PERFORMED BY

Sara Crawford

HOSPITAL NAME

Countryside VS
Champion

REFERRING VET

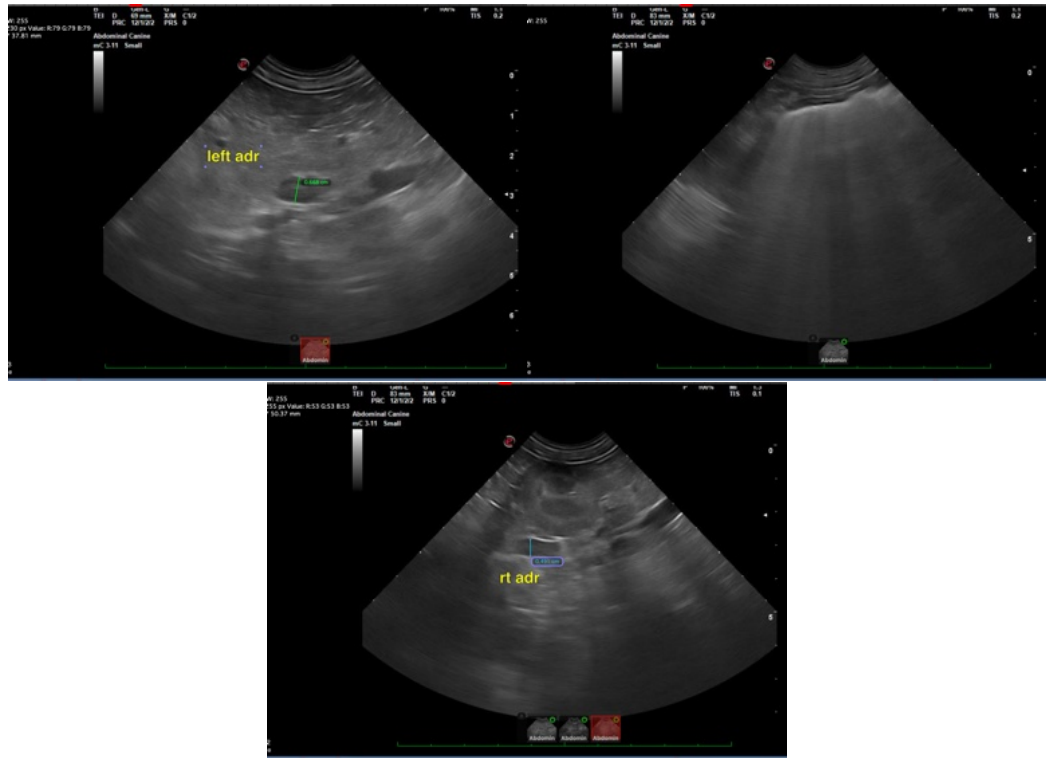
Dr. Crawford

INVOICE

75061

DATE

4/30/26



The information and recommendations provided are based on the images presented by the referring veterinarian/sonographer. No evaluation can be communicated regarding pathology that was not visible in the image/video clips provided.

Thank you for this referral. If the clinical or image interpretation does not parallel your findings or if I can be of any further assistance please contact me.

Eric Lindquist, DMV, DABVP (CFM), Cert. IVUSS, CEO of SonoPath.com

info@SonoPath.com