



PATIENT

Marley Rogers

SPECIES

Canine

BREED

Boxer Mix

SEX

Spayed Female

AGE

6 years

WEIGHT

59.6 lbs

INTERPRETED BY

Eric Lindquist, DMV
DABVP, Cert. IVUSS

IMAGING PERFORMED BY

Laura Klaassen

HOSPITAL NAME

Animal Care Group of
Lake Oswego

REFERRING VET

Dr. Klaassen

INVOICE

75059

DATE

4/30/26

PRESENTING CLINICAL SIGNS

History: hyperglobulinemia and lymphocytosis on routine lab work
Abnormal PE/Chem/CBC/UA Results: glob 3.9 H lymph 5244 H

ULTRASONOGRAPHIC EXAMINATION OF THE ABDOMEN

Urinary System

The **urinary bladder**, trigone, and pelvic urethra presented normal thicknesses and normal tone. The ureters were not visible which is normal. No uroliths or sediment were visualized and anechoic urine was present. No evidence of inflammatory or neoplastic changes was noted. Ureteral papillae were normal.

The **kidneys** revealed normal size and structure, corticomedullary definition and ratio for this age. The cortices presented largely uniform texture with normal echogenic relationship to liver and spleen. Medullary structure differed distinctly from the cortex and no evidence of pelvic dilation was present. The capsules were acceptably uniform without significant irregularities. The left kidney measured 5.5 cm.

Adrenal Glands

Both **adrenal glands** were visualized and recognized as having normal shape, size, position and echogenicity for this breed. The phrenic vasculature, glandular echogenicity and detail were unremarkable. Capsule, cortex, and medullary definition were normal for this age patient. The left adrenal gland measured 0.5 cm.

Spleen

The **spleen** was enlarged with swollen contour. Micronodular changes were noted throughout the spleen with a honeycomb type appearance.

Liver

The **liver** images from right and left intercostal as well as subcostal views revealed subjectively normal liver size, contour, and structure. Some age-related parenchymal remodeling was noted but likely not clinically significant at this time. Vascular and biliary tracts were of normal volume and no evidence of congestion was noted. The gallbladder presented some dependent debris with essentially normal contour. The cystic and common bile ducts were normal. No overt evidence of active inflammatory, infiltrative or regenerative pathology was noted but should be paired with current or past LE elevations regarding any clinical significance to this presentation. The hepatic lymph nodes were unremarkable.



PATIENT

Marley Rogers

SPECIES

Canine

BREED

Boxer Mix

SEX

Spayed Female

AGE

6 years

WEIGHT

59.6 lbs

INTERPRETED BY

Eric Lindquist, DMV
DABVP, Cert. IVUSS

IMAGING PERFORMED BY

Laura Klaassen

HOSPITAL NAME

Animal Care Group of
Lake Oswego

REFERRING VET

Dr. Klaassen

INVOICE

75059

DATE

4/30/26

Gastrointestinal

Examination of the **gastrointestinal tract** revealed a stomach and intestine free of stasis, of normal wall thickness, acceptable curvilinear mural detail, and peristaltic activity. Small and large intestine demonstrated normal luminal chyme and stool consistency respectively. No obstructive or overt infiltrative disease was noted.

Pancreas

The base and limbs of the **pancreas** were observed to be largely isoechoic to surrounding omental fat. Pancreatic duct and capsular contour were acceptably normal and parenchyma respected normal curvilinear patterns. No overt evidence of active inflammatory or neoplastic disease was noted.

Free Abdomen

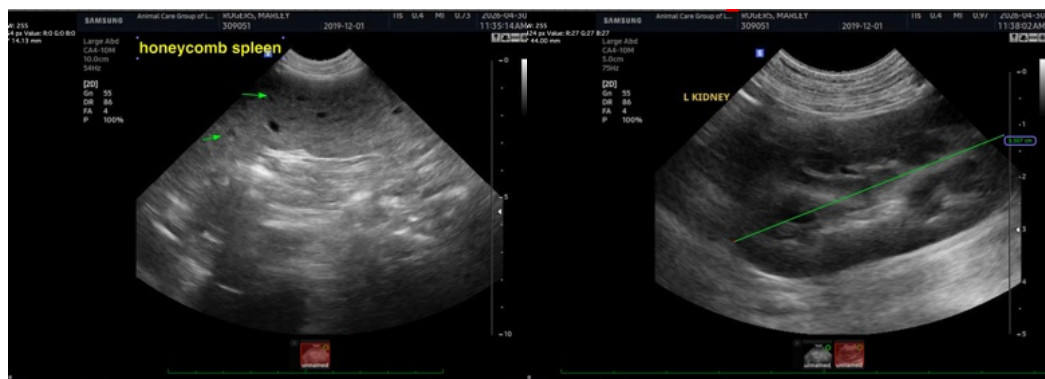The cranial abdomen revealed an enlarged irregular nodular lymph node that measured 2.5 cm.

ULTRASONOGRAPHIC FINDINGS

Infiltrative spleen and lymph node patterns.

INTERPRETATION OF THE FINDINGS & FURTHER RECOMMENDATIONS

Round cell neoplasia is suspected. Lymphadenitis is possible, yet less likely. The presumed lymph node adjacent to the right adrenal. They do not appear to be directly attached; however, I cannot completely rule out that potential. Ultrasound-guided FNA of the lymph node and spleen is recommended for further definition. There is a strong potential for multiple myeloma.





PATIENT

Marley Rogers

SPECIES

Canine

BREED

Boxer Mix

SEX

Spayed Female

AGE

6 years

WEIGHT

59.6 lbs

INTERPRETED BY

Eric Lindquist, DMV
DABVP, Cert. IVUSS

IMAGING PERFORMED BY

Laura Klaassen

HOSPITAL NAME

Animal Care Group of
Lake Oswego

REFERRING VET

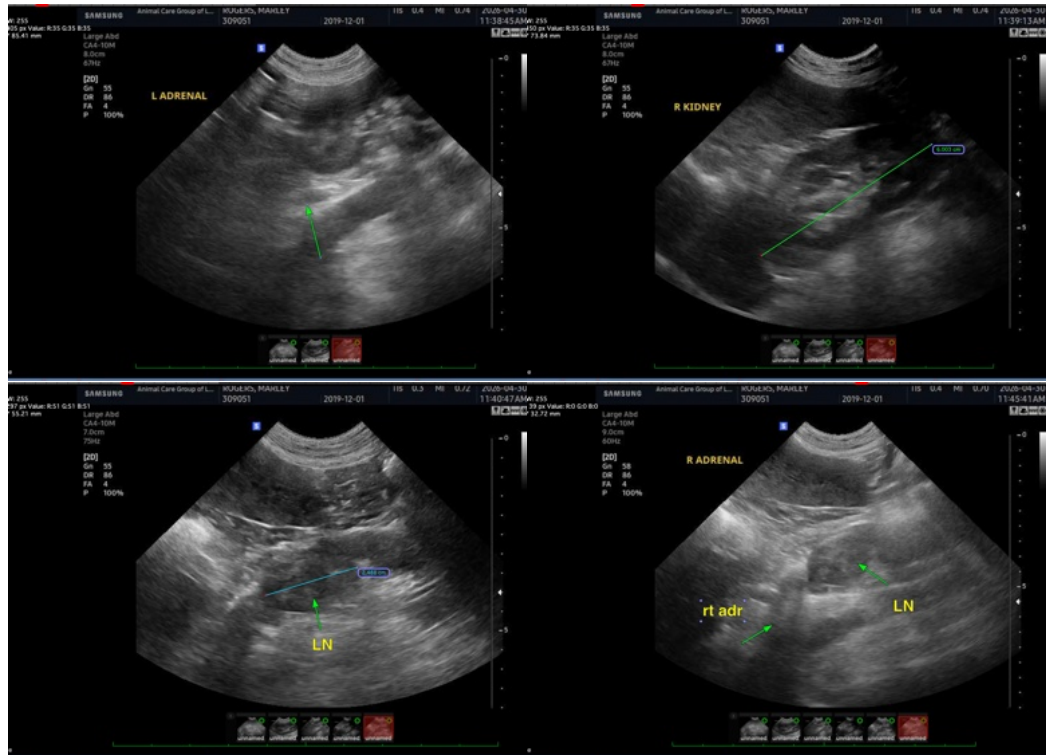
Dr. Klaassen

INVOICE

75059

DATE

4/30/26



The information and recommendations provided are based on the images presented by the referring veterinarian/sonographer. No evaluation can be communicated regarding pathology that was not visible in the image/video clips provided.

Thank you for this referral. If the clinical or image interpretation does not parallel your findings or if I can be of any further assistance please contact me.

Eric Lindquist, DMV, DABVP (CFM), Cert. IVUSS, CEO of SonoPath.com

info@SonoPath.com