



PATIENT

Lumi Rolon

SPECIES

Feline

BREED

Scottish Fold

SEX

Intact Female

AGE

6 Months

WEIGHT

4.1 lbs

INTERPRETED BY

Eric Lindquist, DMV,
DABVP (CFM), Cert.
IVUSS

IMAGING PERFORMED BY

Chloe Lowe, CVT

HOSPITAL NAME

VCA Blairstown Animal
Hospital

REFERRING VET

Dr. Clegg

INVOICE

74857

DATE

4/30/25

PRESENTING CLINICAL SIGNS

Pre-anesthetic check heart murmur. Grade 3/6 murmur.
Abnormal PE/Chem/CBC/UA Results: Pending

ULTRASONOGRAPHIC EXAMINATION OF THE HEART

FELINE CARDIAC PARAMETERS	BODY WEIGHT (lbs)	HR (BPM)	IVSd (cm)	LVIDd (cm)	LVWd (cm)	FS (%)	EF (%)
NORMAL PARAMETER	-----	150-240	0.3-0.6	1.0-2.1	0.25-0.6	35-67	80-100
PATIENT	4.1	202	0.35	1.0	0.35	51	86
FELINE CARDIAC PARAMETERS	LA/AO (M-mode)	LA/AO HEART BASE (Sisson)	LAD LA MAX 4 Chamber		LVOT VEL. (m/s)	RVOT VEL. (m/s)	IVRT (m)
NORMAL PARAMETER	<1.5	1.6	0.7-1.7		<1.6	<1.3	40-60
PATIENT	1.48	1.4	1.4		1.0	0.7	NM
Adapted from June Boon, Veterinary Echocardiography, 1998 Sisson D et al. JVIM 1991; 5: 232, Jacobs et al. Am J Vet Res 1985; 46:1705							

E-wave velocity = 0.7, EPSS = 0.1

Cardiac Presentation

The echocardiogram in this patient demonstrated normal **left atrial** size based on 3 separate LA measurements. The cranial and caudal **mitral** valve leaflets presented normal linear structure and kinetics. The **left ventricle** presented normal thicknesses with linear contour and was not dilated nor restricted. Membranous ventricular septum noted, slightly irregular. The **myocardium** presented normal echogenicity without subjective evidence of significant fibrotic or ischemic disease. **Contractility** of the ventricular walls was adequate and in normal range for this patient evidenced by the fractional shortening measurement and subjective evaluation of the different regions and angles of the myocardium. The **left ventricular outflow** tract demonstrated normal laminar flow and subjective structural integrity. The **right atrium** and auricle revealed normal size, structure and content. No evidence of masses was noted or chamber overload. **Tricuspid** valvular assessment demonstrated adequate linear morphology and kinetics. The **right ventricle** was of normal size (1/3 diameter of LV), chordae structure, myocardial echogenicity and thickness. **Pulmonic** tract assessment revealed normal valve structure, laminar flow, and diameter (approx. 1:1 pa/ao ratio). No visible **pericardial** or free pleura fluid was noted or extra cardiac pathology in the visible planes. The cranial **mediastinum** and **pericardial regions** were free of masses in the visible window.

ULTRASONOGRAPHIC FINDINGS

- Flow murmur or possible minor ventricular septal defect.



PATIENT

Lumi Rolon

SPECIES

Feline

BREED

Scottish Fold

SEX

Intact Female

AGE

6 Months

WEIGHT

4.1 lbs

INTERPRETED BY

Eric Lindquist, DMV,
 DABVP (CFM), Cert.
 IVUSS

IMAGING PERFORMED BY

Chloe Lowe, CVT

HOSPITAL NAME

VCA Blairstown Animal
 Hospital

REFERRING VET

Dr. Clegg

INVOICE

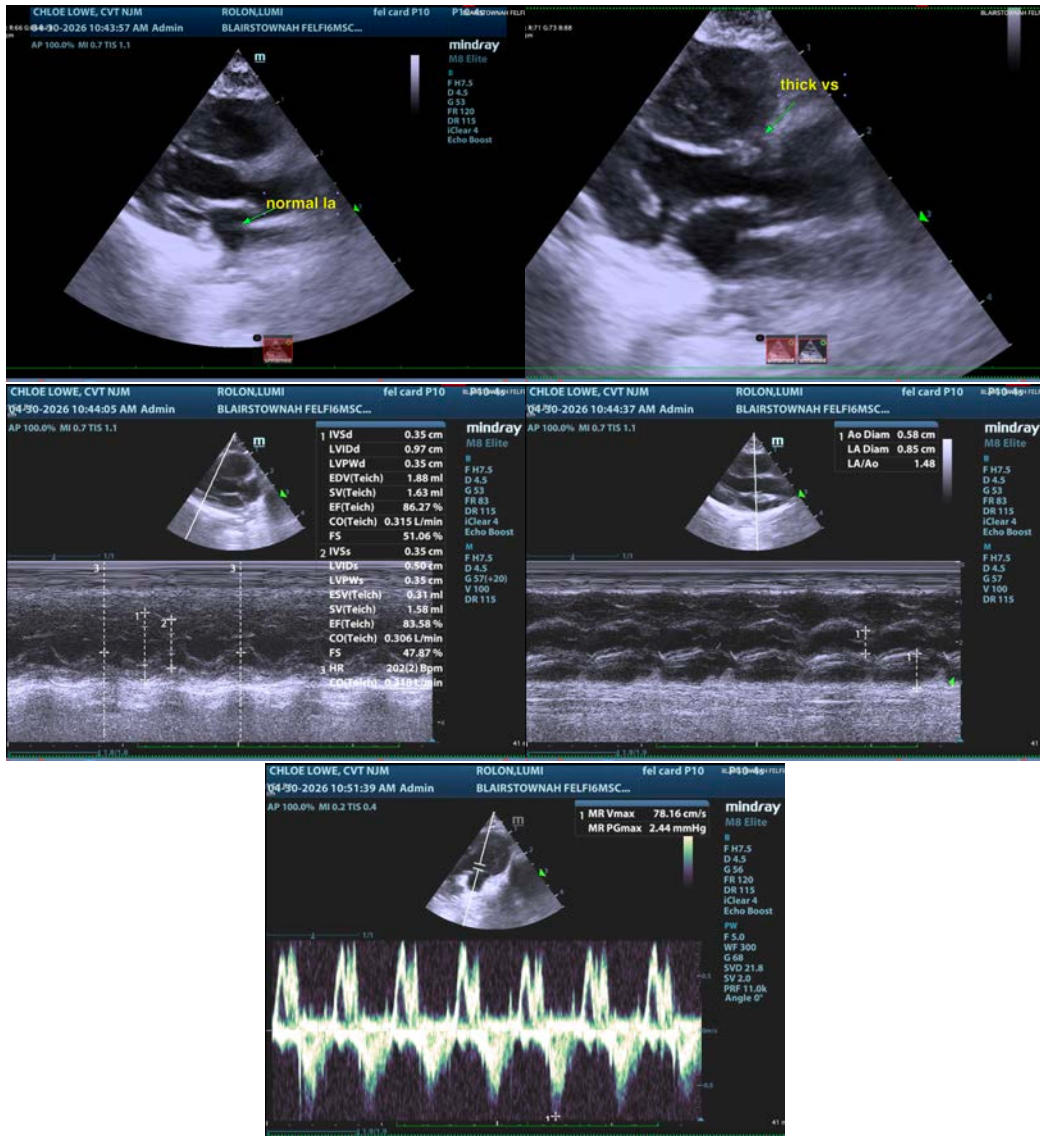
74857

DATE

4/30/25

INTERPRETATION OF THE FINDINGS & FURTHER RECOMMENDATIONS

Doppler did not demonstrate any overt turbulence in ventricular septum. However, I cannot rule out a very small ventricular septal defect. No contraindication to anesthetic procedure in this patient. If murmur is persistently present at one year of age, recommend recheck echocardiogram at that time.





PATIENT

Lumi Rolon

The information and recommendations provided are based on the images presented by the referring veterinarian/sonographer. No evaluation can be communicated regarding pathology that was not visible in the image/video clips provided.

SPECIES

Feline

Thank you for this referral. If the clinical or image interpretation does not parallel your findings or if I can be of any further assistance please contact me.

BREED

Scottish Fold

Eric Lindquist, DMV, DABVP(CFM), Cert. IVUSS,
CEO, Owner, Founder -- SonoPath.com
info@SonoPath.com

SEX

Intact Female

AGE

6 Months

WEIGHT

4.1 lbs

INTERPRETED BY

Eric Lindquist, DMV,
DABVP (CFM), Cert.
IVUSS

**IMAGING
PERFORMED BY**

Chloe Lowe, CVT

HOSPITAL NAME

VCA Blirstown Animal
Hospital

REFERRING VET

Dr. Clegg

INVOICE

74857

DATE

4/30/25