



PATIENT

Belle Armfield

SPECIES

Canine

BREED

Pit Bull

SEX

Intact Female

AGE

10 Months

WEIGHT

37.6 lbs

INTERPRETED BY

Eric Lindquist, DMV,
DABVP (CFM), Cert.
IVUSS

IMAGING PERFORMED BY

Chloe Lowe, CVT

HOSPITAL NAME

VCA AVH Animal
Hospital

REFERRING VET

Dr. Kaulius

INVOICE

74859

DATE

4/30/26

PRESENTING CLINICAL SIGNS

Heart murmur. Pre-anesthesia screen for spay. New patient to us this month. Noted heart murmur and auscultated again at recheck. Focal left basilar 3/6, no clinical signs. Simparica Trio, gabapentin/trazodone last night and today for echo.

Abnormal PE/Chem/CBC/UA Results: N/a. Fecal NSP, Accuplex negative x 4

ULTRASONOGRAPHIC EXAMINATION OF THE HEART

CANINE CARDIAC PARAMETERS	MR VMAX (m/s)	TR VMAX (m/s)	LA/AO (M-Mode)	LA/AO (Heart Base; Swe)	FS (%)	EF (%)	EPSS (cm)
NORMAL PARAMETER	4.5-5.5	<2.7	1.3	Up to 1.6	28-40	40-100	<0.6
PATIENT	--	--	1.0	1.3	49	82	NM
CANINE CARDIAC PARAMETERS	HR (BPM)	AV VMAX (m/s)	PV MAX (m/s)	BODY WEIGHT (lbs)	LAD LA MAX 4 Chamber	LVIDd Avg; 2D and m-mode short axis (cm)	LVIDs Avg; 2D and m-mode short axis (cm)
NORMAL PARAMETER	50-100	0.7-1.7	0.7-1.6				
PATIENT	192	4.5-6.0	1.6	37.6	2.9	2.7	--

Cardiac Presentation

The echocardiogram in this patient demonstrated normal left atrial size based on 3 separate methods of LA evaluation. The cranial and caudal mitral valve leaflets presented normal linear structure, extension in systole, and union in diastole with normal kinesis. The left ventricle presented hypertrophy and septal thickening just prior to the aortic valve. The myocardium presented normal echogenicity without subjective evidence of significant fibrotic or ischemic disease. Contractility of the ventricular walls was adequate and in normal range for this patient evidenced by the fractional shortening measurement and subjective evaluation of the different regions of the myocardium. The aortic valve was mildly thickened. Aortic velocity was elevated. The right atrium and auricle revealed normal size, structure and content. No evidence of masses was noted. Tricuspid valvular assessment demonstrated adequate linear morphology and kinesis. The right ventricle was of normal size (1/3 diameter of LV), chordae structure, myocardial echogenicity and thickness. Pulmonic velocity slightly elevated. No visible pericardial or free pleura fluid was noted. The cranial mediastinum and pericardial and extra-cardiac regions were free of masses in the visible window.

ULTRASONOGRAPHIC FINDINGS

- Cardiac changes consistent with subaortic stenosis with secondary left ventricular hypertrophy.

INTERPRETATION OF THE FINDINGS & FURTHER RECOMMENDATIONS

There is mild anesthetic risk at this time in this patient. Long-term prognosis is guarded. I strongly



PATIENT

Belle Armfield

SPECIES

Canine

BREED

Pit Bull

SEX

Intact Female

AGE

10 Months

WEIGHT

37.6 lbs

INTERPRETED BY

Eric Lindquist, DMV,
 DABVP (CFM), Cert.
 IVUSS

IMAGING PERFORMED BY

Chloe Lowe, CVT

HOSPITAL NAME

VCA AVH Animal
 Hospital

REFERRING VET

Dr. Kaulius

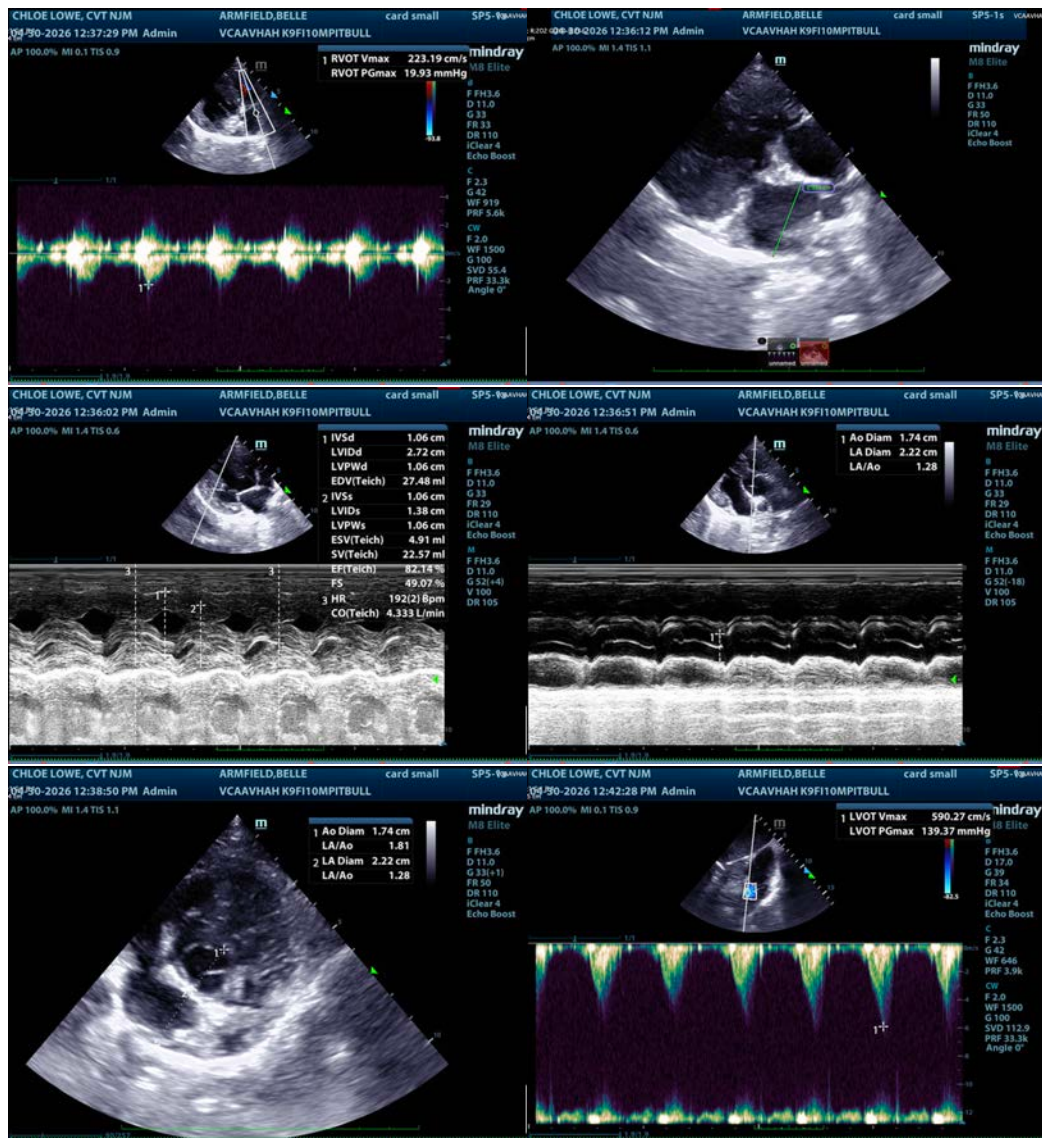
INVOICE

74859

DATE

4/30/26

recommend no reproductive activity in this patient, and therefore ovariohysterectomy is justified. Torbutrol pre-med, Propofol induction, Isoflurane maintenance recommended as well as prophylactic antibiotics 5 days prior and 5 days post surgery. Recheck echo in 6 months. If resting heart rate is >120, Atenolol therapy would be indicated.





PATIENT

Belle Armfield

SPECIES

Canine

BREED

Pit Bull

SEX

Intact Female

AGE

10 Months

WEIGHT

37.6 lbs

INTERPRETED BY

Eric Lindquist, DMV,
 DABVP (CFM), Cert. IVUSS

IMAGING PERFORMED BY

Chloe Lowe, CVT

HOSPITAL NAME

VCA AVH Animal
 Hospital

REFERRING VET

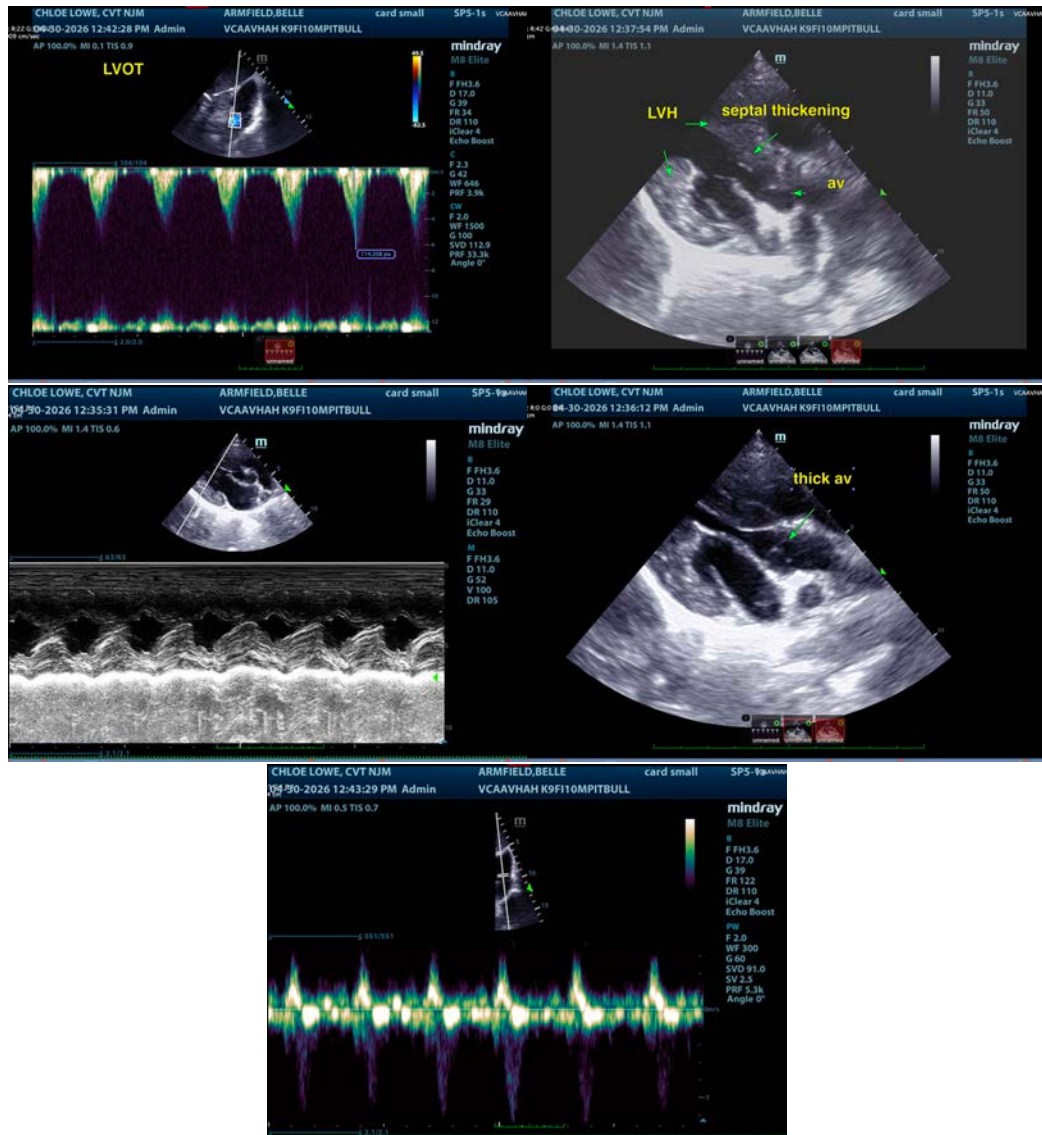
Dr. Kaulius

INVOICE

74859

DATE

4/30/26



The information and recommendations provided are based on the images presented by the referring veterinarian/sonographer. No evaluation can be communicated regarding pathology that was not visible in the image/video clips provided.

Thank you for this referral. If the clinical or image interpretation does not parallel your findings or if I can be of any further assistance please contact me.

Eric Lindquist, DMV, DABVP(CFM), Cert. IVUSS,
 CEO, Owner, Founder -- SonoPath.com
info@SonoPath.com



PATIENT

Belle Armfield

SPECIES

Canine

BREED

Pit Bull

SEX

Intact Female

AGE

10 Months

WEIGHT

37.6 lbs

INTERPRETED BY

Eric Lindquist, DMV,
DABVP (CFM), Cert.
IVUSS

IMAGING PERFORMED BY

Chloe Lowe, CVT

HOSPITAL NAME

VCA AVH Animal
Hospital

REFERRING VET

Dr. Kaulius

INVOICE

74859

DATE

4/30/26

Subvalvular Aortic Stenosis

<http://www.sonopath.com/SAS>

<http://www.sonopath.com/EchoModler>

Description: Subvalvular aortic stenosis (SAS) is the second most common heart defect in dogs and is more common in larger breeds, such as the Newfoundland, Golden Retriever, Boxer, and Rottweiler.

Clinical Signs: Primary clinical signs include an ejection character heart-based murmur, syncope, and occasionally congestive heart failure (CHF). Hypokinetic pulses may be present in more advanced cases. Primary differentials include pulmonic stenosis, ventricular septal defect, mitral regurgitation, patent ductus arteriosus, and an idiopathic flow murmur. SAS patients are predisposed to bacterial endocarditis and necessitate prolonged antibiotic therapy during surgical and dental procedures as well as under circumstances where an infection, such as pyoderma, pyometra, or a UTI, may be present.

Diagnostics: Radiographs may present as completely normal or they can reveal an aortic bulge as well as left atrial and ventricular enlargement. Pulmonary venous congestion and CHF are also sometimes detected.

Ascertaining NT-proBNP levels may be useful in young puppies with murmurs as a means of screening for congenital anomalies. One study showed that median NT-proBNP levels in dogs with SAS were 833 pmol/L compared to 333 pmol/l for normal dogs. Although NT-proBNP is not specific for SAS, an elevated level should prompt additional diagnostic tests and echocardiography in particular.

Moderate to severe SAS is easily confirmed by 2D or Doppler echocardiography. Typical findings include concentric left ventricular hypertrophy, a subvalvular obstructing lesion, and poststenotic dilation of the aorta. The papillary muscles and endocardial surface of the ventricular myocardium often appear hyperechoic, presumably because of myocardial ischemia and replacement fibrosis or calcification. Structural changes in the mitral valve can often be appreciated and abnormal motion of the mitral valve (systolic anterior motion) can be detected in those dogs with coexisting mitral valve dysplasia and dynamic obstruction. Spectral Doppler measures the peak velocity of flow in the left ventricular outflow tract (LVOT). It is performed to assess disease severity; the results correlate closely with those obtained using invasive measures. Although Doppler-estimated pressure gradients between 80 and 100 mm Hg (peak flow velocities ranging from 4.5-5.0 m/s) are taken to indicate moderate LVOT obstruction and higher velocities more severe obstructions, these designations are somewhat arbitrary. Doppler color flow recordings are valuable for detecting and estimating the severity of any coexisting aortic or mitral valve insufficiency. The detection of mild SAS by echocardiography is often not possible as dogs with subtle abnormalities may escape detection by even the most accomplished examiners. A diagnosis of mild SAS is more secure when mildly elevated velocity measures are accompanied by disturbed flow, an anatomic lesion is visible, or velocity flow suddenly accelerates over a discrete region in the LVOT.

Treatment: Both moderate and severe cases of SAS are at risk for sudden death. Medical therapy with a beta blocker (e.g. atenolol at 0.5-1mg/kg BID) is the preferred treatment; mild exercise restriction is also recommended in severe cases. A number of surgical treatment options can be considered for dogs with moderate to severe SAS, but most are of uncertain value. Open resection of the obstructing lesion during cardiopulmonary bypass offers the best opportunity for reducing the systolic pressure gradient. Other surgical procedures employed to dilate or bypass obstructions have either failed to achieve a sustained reduction of the systolic pressure gradient or they entail an unacceptable risk of complication. Balloon valvuloplasty is no longer typically performed in most cases due to a lack of lasting beneficial effects and difficulty in adequately reducing the pressure gradient.

References:

Bussadori C, Amberger C, LeBobinecc G, Lombard CW. Guidelines for the echocardiographic studies of suspected subaortic and pulmonic stenosis. *J Vet Cardiol* 2000;2:15-22.



PATIENT

Belle Armfield

Kienle RD, Thomas WP, Pion PD. The natural clinical history of canine congenital subaortic stenosis. *J Vet Intern Med* 1994;8:423-31.

SPECIES

Canine

Oyama MA, Sisson DD. Cardiac troponin-I concentration in dogs with cardiac disease. *J Vet Int Med* 2004;18:831-39.

BREED

Pit Bull

Reist-Marti SB, Dolf G, Leeb T, et al. Genetic evidence of subaortic stenosis in the Newfoundland dog. *Vet Rec* 2012;170:597.

SEX

Intact Female

AGE

10 Months

WEIGHT

37.6 lbs

INTERPRETED BY

Eric Lindquist, DMV,
DABVP (CFM), Cert.
IVUSS

**IMAGING
PERFORMED BY**

Chloe Lowe, CVT

HOSPITAL NAME

VCA AVH Animal
Hospital

REFERRING VET

Dr. Kaulius

INVOICE

74859

DATE

4/30/26