



## PATIENT

Beau Manlove

## SPECIES

Canine

## BREED

Goldendoodle

## SEX

Neutered male

## AGE

11 years

## WEIGHT

49 lbs

## INTERPRETED BY

Eric Lindquist, DMV  
DABVP, Cert. IVUSS

## IMAGING PERFORMED BY

Ashley Whitesell

## HOSPITAL NAME

Dickson AC

## REFERRING VET

Dr. Whitesell

## INVOICE

75008

## DATE

4/30/26

## PRESENTING CLINICAL SIGNS

History: 4/1/26: Lasix 30mg BID, Vetmedin BID  
ECHO: severely enlarged LA, hemodynamic changes; ACVIM stage 3  
added enalapril 10mg BID  
Abnormal PE/Chem/CBC/UA Results: 3/2026 bloodwork at urgent vet: ALT 111, ALP 490 4/16/26  
recheck lab work after starting enalapril and lasix w/ CHF ALT 231, ALP 597

## ULTRASONOGRAPHIC EXAMINATION OF THE ABDOMEN

### Urinary System

The **urinary bladder**, trigone, and pelvic urethra presented normal thicknesses and normal tone. The ureters were not visible which is normal. No uroliths or sediment were visualized and anechoic urine was present. No evidence of inflammatory or neoplastic changes was noted. Ureteral papillae were normal.

The **kidneys** revealed largely normal size and structure, corticomedullary definition and ratio (cortex 1/3 of medulla) were essentially maintained with some age-related loss of curvilinear patterns regarding the capsule and C/M junction. The cortices presented largely uniform texture with some increased echogenicity expected for this age patient. Medullary structure differed distinctly from that of the cortex and no evidence of pelvic dilation was present. The left kidney measured 6.3 cm. The right kidney measured 6.7 cm.

### Adrenal Glands

Both **adrenal glands** were visualized and recognized as having normal shape, size, position and echogenicity for this breed. The phrenic vasculature, glandular echogenicity and detail were unremarkable. Capsule, cortex, and medullary definition were normal for this age patient. The left adrenal gland measured 0.64 cm at the caudal pole and 0.49 cm at the cranial pole. The right adrenal gland measured 0.78 cm at the cranial pole and 0.68 cm at the caudal pole.

### Spleen

The **spleen** presented a smooth homogeneous parenchyma hyperechoic to liver and renal cortical parenchyma. The capsule was smooth without noticeable expansion or deviation from within the spleen or adjacent pathology. The splenic vasculature demonstrated normal volume without signs of congestion or thrombosis. No sonographic evidence of acute or chronic inflammatory, neoplastic, or infarctual changes was noted.

### Liver

The **liver** images from right and left intercostal as well as subcostal views revealed subjectively normal liver size, contour, and structure. Some age-related parenchymal remodeling was noted but likely not



## PATIENT

Beau ManLove

## SPECIES

Canine

## BREED

Goldendoodle

## SEX

Neutered male

## AGE

11 years

## WEIGHT

49 lbs

## INTERPRETED BY

Eric Lindquist, DMV  
DABVP, Cert. IVUSS

## IMAGING PERFORMED BY

Ashley Whitesell

## HOSPITAL NAME

Dickson AC

## REFERRING VET

Dr. Whitesell

## INVOICE

75008

## DATE

4/30/26

clinically significant at this time. Vascular and biliary tracts were of normal volume and no evidence of congestion was noted. The gallbladder presented some dependent debris with essentially normal contour. The cystic and common bile ducts were normal. No overt evidence of active inflammatory, infiltrative or regenerative pathology was noted but should be paired with current or past LE elevations regarding any clinical significance to this presentation. The hepatic lymph nodes were unremarkable.

## Gastrointestinal

Examination of the **gastrointestinal tract** revealed a stomach and intestine free of stasis, of normal wall thickness, acceptable curvilinear mural detail, and peristaltic activity. Small and large intestine demonstrated normal luminal chyme and stool consistency respectively. No obstructive or overt infiltrative disease was noted. No associated abnormal lymphatic activity was noted.

## Pancreas

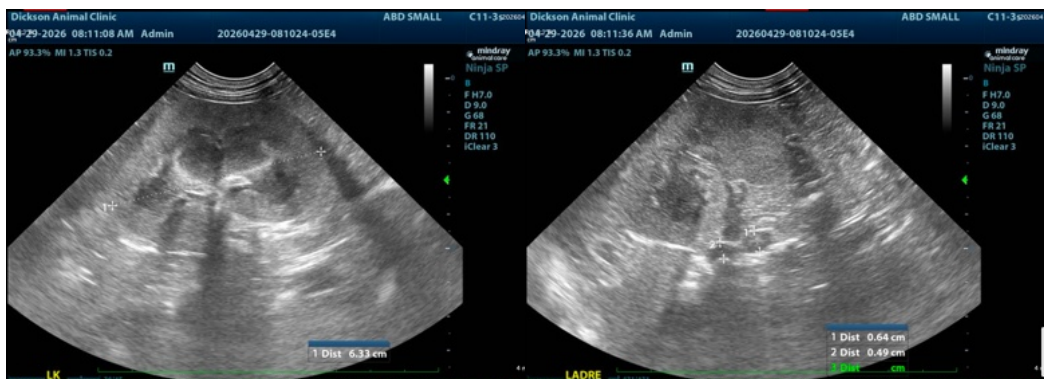
The base and limbs of the **pancreas** were observed to be largely isoechoic to surrounding omental fat. Pancreatic duct and capsular contour were acceptably normal and parenchyma respected normal curvilinear patterns. No overt evidence of active inflammatory or neoplastic disease was noted.

## ULTRASONOGRAPHIC FINDINGS

Structurally unremarkable abdomen.

## INTERPRETATION OF THE FINDINGS & FURTHER RECOMMENDATIONS

There was no evidence of visceral pathology. The changes are expected for this patient's age and breed.





**PATIENT**

Beau Manlove

**SPECIES**

Canine

**BREED**

Goldendoodle

**SEX**

Neutered male

**AGE**

11 years

**WEIGHT**

49 lbs

**INTERPRETED BY**

Eric Lindquist, DMV  
DABVP, Cert. IVUSS

**IMAGING  
PERFORMED BY**

Ashley Whitesell

**HOSPITAL NAME**

Dickson AC

**REFERRING VET**

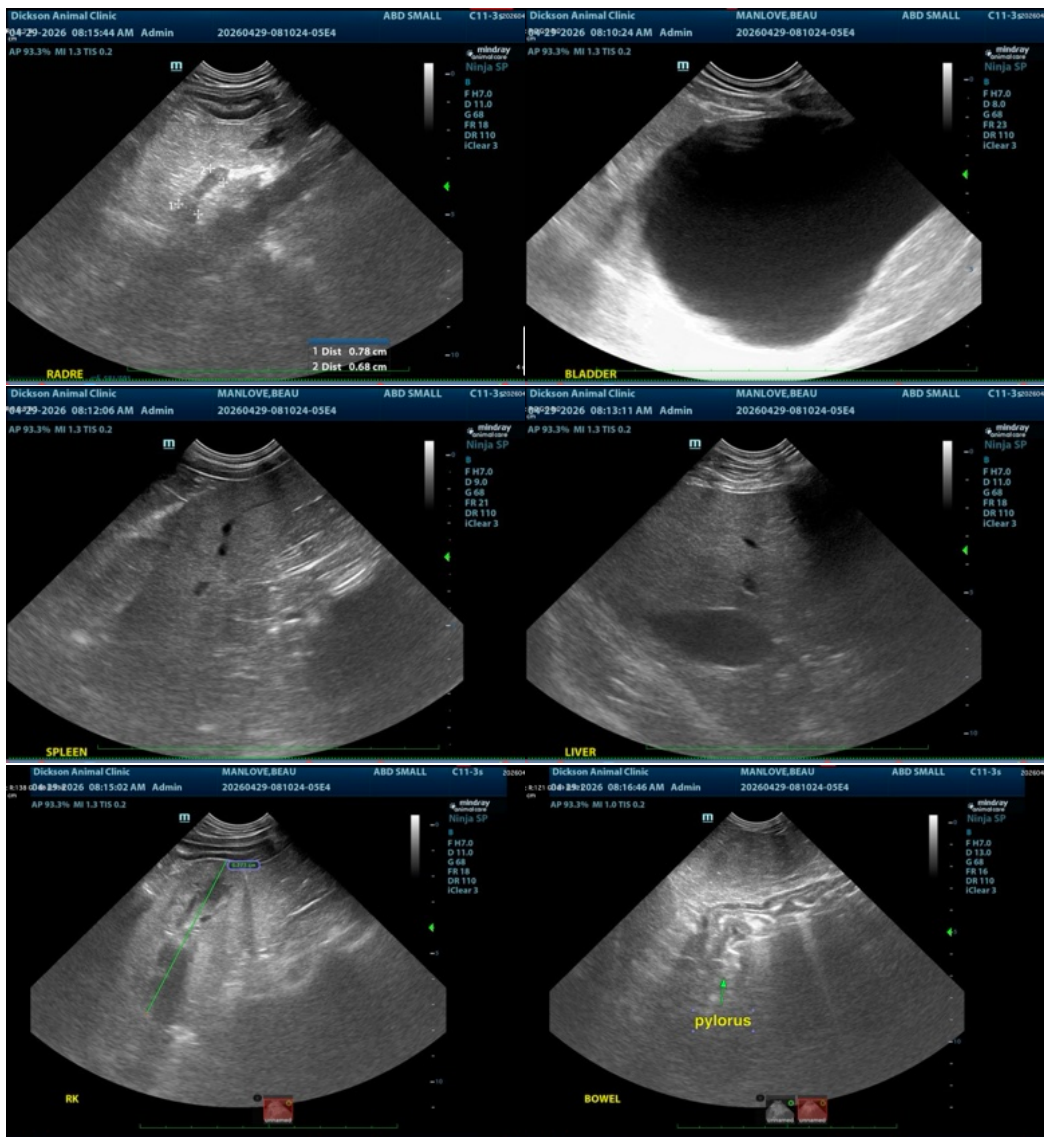
Dr. Whitesell

**INVOICE**

75008

**DATE**

4/30/26



The information and recommendations provided are based on the images presented by the referring veterinarian/sonographer. No evaluation can be communicated regarding pathology that was not visible in the image/video clips provided.

Thank you for this referral. If the clinical or image interpretation does not parallel your findings or if I can be of any further assistance please contact me.

Eric Lindquist, DMV, DABVP (CFM), Cert. IVUSS, CEO of SonoPath.com

[info@SonoPath.com](mailto:info@SonoPath.com)