



PATIENT

Tilly Paugh

SPECIES

Canine

BREED

Terrier Mix

SEX

Spayed Female

AGE

10 Years

WEIGHT

25

INTERPRETED BY

Eric Lindquist, DMV
DABVP, Cert. IVUSS

IMAGING PERFORMED BY

JK

HOSPITAL NAME

Hamburg VC

REFERRING VET

Dr. Martens

INVOICE

22236

DATE

4/30/23

PRESENTING CLINICAL SIGNS

History: Elevated liver and pancreatic values. Vomiting not eating

Abnormal PE/Chem/CBC/UA Results: ALT 145, ALK PHOS 404, PSL 205

ULTRASONOGRAPHIC EXAMINATION OF THE ABDOMEN

Urinary System

The **urinary bladder**, trigone, and pelvic urethra presented normal thicknesses and normal tone. The ureters were not visible which is normal. No uroliths or sediment were visualized and anechoic urine was present. No evidence of inflammatory or neoplastic changes were noted. Ureteral papillae were normal. The pelvic urethra was imaged 2.0 cm beyond the cystourethral junction.

The **kidneys** revealed largely normal size and structure, corticomedullary definition and ratio (cortex 1/3 of medulla) were essentially maintained with some moderate age-related loss of curvilinear patterns regarding the capsule and C/M junction. The cortices presented largely uniform texture with some increased echogenicity expected for his age patient. Medullary structure differed distinctly from that of the cortex and no evidence of pelvic dilation was present. Mineralization was present in the kidneys. The right kidney measured 5.81 cm. The left kidney measured 5.57 cm.

Adrenal Glands

Both **adrenal glands** were visualized and recognized as having normal shape, size, position and echogenicity for this breed. The phrenic vasculature, glandular echogenicity and detail were unremarkable. Capsule, cortex, and medullary definition were normal for this age patient. The left adrenal gland measured 1.66 cm x 0.59 cm. The right adrenal gland measured 0.84 cm at the cranial pole and 0.58 cm at the caudal pole.

Spleen

The **spleen** presented a smooth homogeneous parenchyma hyperechoic to liver and renal cortical parenchyma. The capsule was smooth without noticeable expansion or deviation from within the spleen or adjacent pathology. The splenic vasculature demonstrated normal volume without signs of congestion or thrombosis. Cranial folding of the spleen was noted. Occasional lipogranulomas/or lipid plaques were noted in the spleen.

Liver

The **liver** images from right and left intercostal as well as subcostal views revealed subjectively normal liver size, contour, and structure. Some minor age-related parenchymal remodeling was noted but likely not clinically significant at this time. Vascular and biliary tracts were of normal volume and no evidence of congestion was noted. The gallbladder presented some dependent debris with essentially normal contour. The cystic and common bile ducts were normal. No overt evidence of active inflammatory, infiltrative or regenerative pathology was noted but should be paired with current or past LE elevations regarding any clinical significance to this presentation. The hepatic lymph nodes were unremarkable.

Gastrointestinal

There was some residual chyme and gas was noted in the **stomach**, yet not pathological. This is consistent with end post prandial presentation. Transit of chyme into the small intestine was normal.



PATIENT

Tilly Paugh

Curvilinear patterns were maintained throughout the GI tract. No evidence of pathology. Small and large intestine demonstrated normal luminal chyme and stool consistency respectively. No obstructive or overt infiltrative disease was noted. No associated abnormal lymphatic activity was noted.

SPECIES

Canine

Pancreas

The base and limbs of the **pancreas** were observed to be largely isoechoic to surrounding omental fat. Pancreatic duct and capsular contour were acceptably normal and parenchyma respected normal curvilinear patterns. No overt evidence of active inflammatory or neoplastic disease was noted.

BREED

Terrier Mix

ULTRASONOGRAPHIC FINDINGS

SEX

Spayed Female

- Minor retention of ingesta in the stomach
- Cranial folding of the spleen. Occasional lipogranulomas/or lipid plaques in the spleen.
- Age-related hepatic changes
- Age-related renal changes with mineralization
- Age-related abdominal changes- no evidence of significant disease

AGE

10 Years

INTERPRETATION OF THE FINDINGS & FURTHER RECOMMENDATIONS

The cause of vomiting is unclear in this patient. If the patient was NPO at the time of the sonogram, then soft foreign matter or grass is possible yet no obstructive disease is noted. FNA of the liver could be considered for further definition. Symptomatic care and diet change should prove effective.

WEIGHT

25

INTERPRETED BY

Eric Lindquist, DMV
DABVP, Cert. IVUSS

IMAGING PERFORMED BY

JK

HOSPITAL NAME

Hamburg VC

REFERRING VET

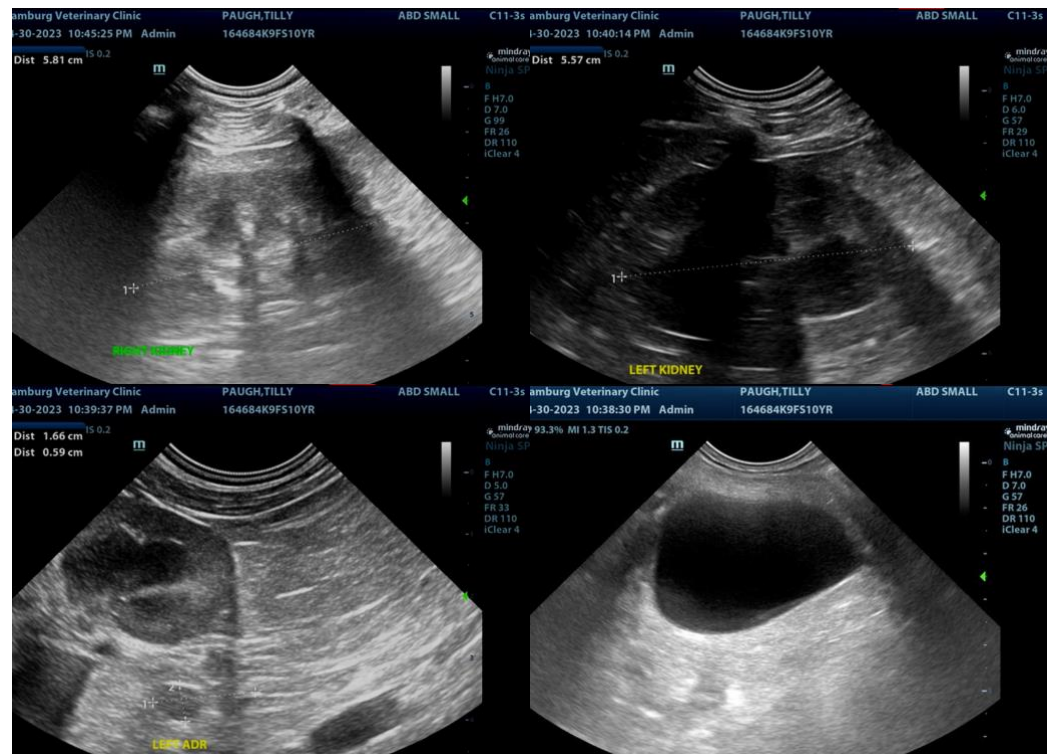
Dr. Martens

INVOICE

22236

DATE

4/30/23





PATIENT

Tilly Paugh

SPECIES

Canine

BREED

Terrier Mix

SEX

Spayed Female

AGE

10 Years

WEIGHT

25

INTERPRETED BY

Eric Lindquist, DMV
DABVP, Cert. IVUSS

IMAGING PERFORMED BY

JK

HOSPITAL NAME

Hamburg VC

REFERRING VET

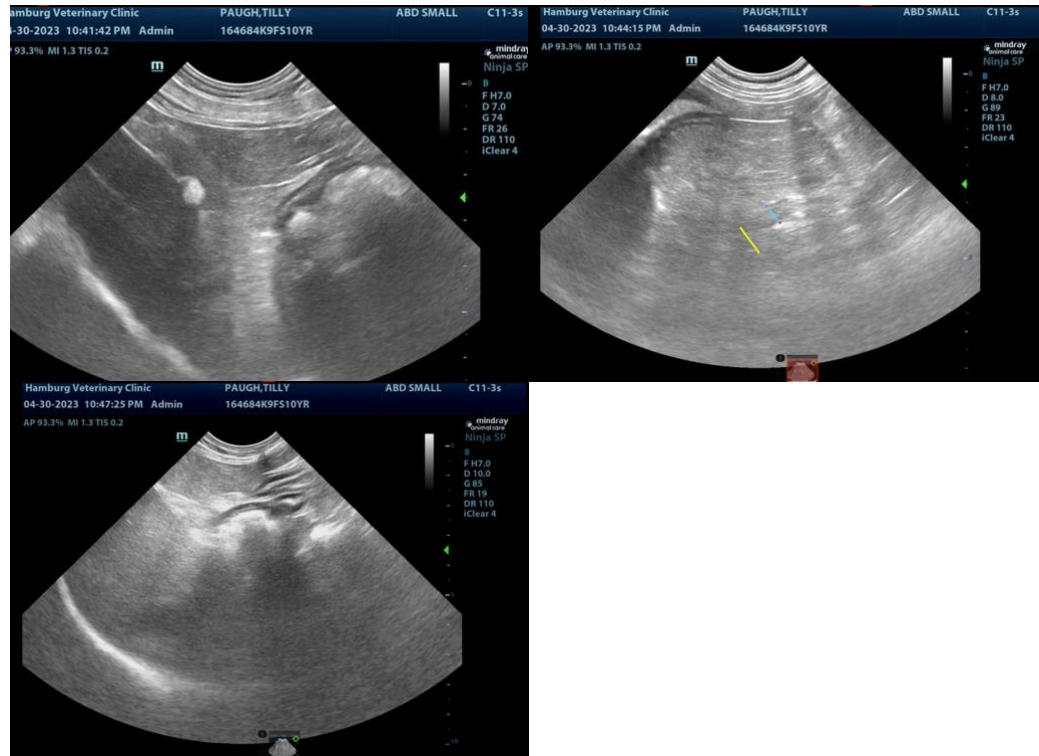
Dr. Martens

INVOICE

22236

DATE

4/30/23



The information and recommendations provided are based on the images presented by the referring veterinarian. No evaluation can be communicated regarding pathology that was not visible in the image/video clips provided.

Thank you for this referral. If the clinical or image interpretation does not parallel your findings or if I can be of any further assistance please contact me.

Eric Lindquist, DMV, DABVP, Cert. IVUSS, CEO of SonoPath.com
info@SonoPath.com