

PATIENT

Sweetie Phogat

SPECIES

Feline

BREED

DSH

SEX

Spayed Female

AGE

3 Years

WEIGHT

10 pounds

INTERPRETED BY

Eric Lindquist, DMV,
DABVP(CFM), Cert.
IVUSS

IMAGING PERFORMED BY

Dr. Jeremiah Gabriel

HOSPITAL NAME

Central Jersey Animal
Hospital

REFERRING VET

Dr. Jeremiah Gabriel

INVOICE

14817

DATE

04/03/26

PRESENTING CLINICAL SIGNS

- ate a string (8 ft)
- vomited twice today
- vomited small part of the string

ULTRASONOGRAPHIC EXAMINATION OF THE ABDOMEN

Urinary System

The **urinary bladder**, trigone, and pelvic urethra to a depth of 2.0 cm presented normal thicknesses and normal tone. The ureters were not visible which is normal. No uroliths or sediment were visualized, and anechoic urine was present. No evidence of inflammatory or neoplastic changes were noted. Ureteral papillae were normal.

The **kidneys** revealed normal size and structure, corticomedullary definition and ratio for this age. The cortices presented largely uniform texture with normal echogenic relationship to liver and spleen. Medullary structure differed distinctly from the cortex and no evidence of pelvic dilation was present. The capsules were acceptably uniform without significant irregularities. The left kidney measured 3.1 cm in length. The right kidney measured X cm in length.

Adrenal Glands

Both **adrenal glands** were not visualized.

Spleen

The **spleen** presented a smooth homogeneous parenchyma hyperechoic to liver and renal cortical parenchyma. The capsule was smooth without noticeable expansion or deviation from within the spleen or adjacent pathology. The splenic vasculature demonstrated normal volume without signs of congestion or thrombosis. No sonographic evidence of acute or chronic inflammatory, neoplastic, or infarctual changes were noted.

Liver

The **liver** images submitted revealed subjectively normal liver size, contour, and structure. Parenchymal echogenicity was naturally coarse and hypoechoic to the spleen. Vascular and biliary tracts were of normal volume with no evidence of congestion. The gallbladder presented acceptably thin walls with primarily anechoic content. The cystic and common bile ducts were normal. No pathological hepatic lymphadenopathy was evident. No overt structural evidence of inflammatory, infiltrative or regenerative pathology was evident.

Gastrointestinal

The **stomach** was overdistended with fluid with a luminal gastric shadowing material. Suspended linear material was noted in the pylorus and stomach and appeared to continue into the small intestine.

Pancreas

The base and limbs of the **pancreas** were observed to be largely isoechoic to surrounding omental fat. Pancreatic duct and capsular contour were acceptably normal and parenchyma respected normal curvilinear patterns. No overt evidence of active inflammatory or neoplastic disease was noted.



PATIENT

Sweetie Phogat

SPECIES

Feline

BREED

DSH

SEX

Spayed Female

AGE

3 Years

WEIGHT

10 pounds

INTERPRETED BY

Eric Lindquist, DMV,
DABVP(CFM), Cert.
IVUSS

IMAGING PERFORMED BY

Dr. Jeremiah Gabriel

HOSPITAL NAME

Central Jersey Animal
Hospital

REFERRING VET

Dr. Jeremiah Gabriel

INVOICE

14817

DATE

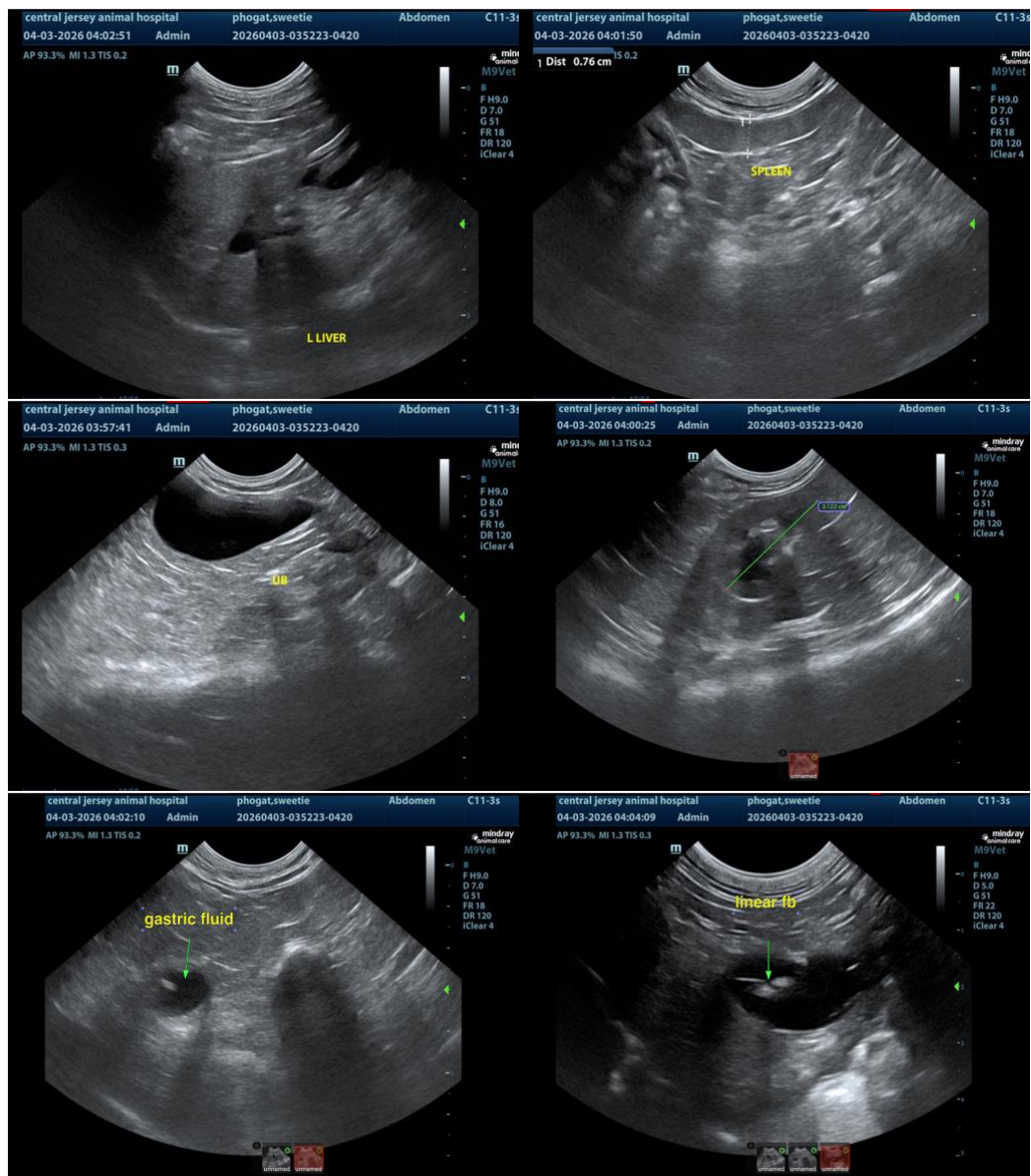
04/03/26

ULTRASONOGRAPHIC FINDINGS

- Gastric linear foreign matter possibly anchored at the base of the tongue entering into the stomach.

INTERPRETATION OF THE FINDINGS & FURTHER RECOMMENDATIONS

Recommend assessing the base of the tongue for a connection as it appeared to continue into the small intestine. Surgical intervention is recommended.





PATIENT

Sweetie Phogat

SPECIES

Feline

BREED

DSH

SEX

Spayed Female

AGE

3 Years

WEIGHT

10 pounds

INTERPRETED BY

Eric Lindquist, DMV,
DABVP(CFM), Cert.
IVUSS

IMAGING PERFORMED BY

Dr. Jeremiah Gabriel

HOSPITAL NAME

Central Jersey Animal
Hospital

REFERRING VET

Dr. Jeremiah Gabriel

INVOICE

14817

DATE

04/03/26

The information and recommendations provided are based on the images presented by the referring veterinarian/sonographer. No evaluation can be communicated regarding pathology that was not visible in the image/video clips provided.

Thank you for this referral. If the clinical or image interpretation does not parallel your findings or if I can be of any further assistance, please contact me.

Eric Lindquist, DMV, DABVP(CFM), Cert. IVUSS,

CEO, Owner, Founder -- SonoPath.com

info@SonoPath.com