



PATIENT

Sammy Illescas

SPECIES

Canine

BREED

Miniature Schnauzer

SEX

Neutered male

AGE

11 years

WEIGHT

20 lbs

INTERPRETED BY

Eric Lindquist, DMV
DABVP, Cert. IVUSS

IMAGING PERFORMED BY

Heather

HOSPITAL NAME

Animal Care Center of
Flanders

REFERRING VET

Dr. Hallihan

INVOICE

74134

DATE

4/3/26

PRESENTING CLINICAL SIGNS

- Recheck echo after starting Pimobendan, Enalapril, and Spironolactone
- Did have seizure like episode - suspect syncopal episode before starting medication
- Medications: Vetmedin 2.5mg BID, Enalapril 2.5mg BID, Spironolactone 25mg 1/2 tab po BID
- 2/20/26: BUN 31 4/3/26: BP = 180 systolic

ULTRASONOGRAPHIC EXAMINATION OF THE HEART

The echocardiogram in this patient revealed persistent volume overload in the left atrium and left ventricle. Mitral valve prolapse was noted. Mitral and tricuspid insufficiency was noted. Contractility appeared to be adequately compensatory. There was no pericardial or pleural effusion noted. The hepatic veins were not dilated.

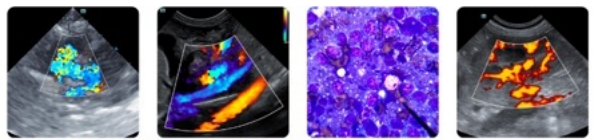
CANINE CARDIAC PARAMETERS	MR VMAX (m/s)	TR VMAX (m/s)	LA/AO	LA/AO (Heart Base)	FS (%)	EF (%)	EPSS (cm)
NORMAL PARAMETER	4.5-5.5	<2.7	1.3	<1.6	28-40	40-100	<0.6
PATIENT	>5.0	1.2	1.5	2.0	50	80	0.1
CANINE CARDIAC PARAMETERS	HR (BPM)	AV VMAX (m/s)	PV MAX (m/s)	BODY WEIGHT	LA 2D short axis Base view (cm)	LVIDd Avg; 2D and m-mode short axis (cm)	LVIDs Avg; 2D and m-mode short axis (cm)
NORMAL PARAMETER	50-100	0.7-1.7	0.7-1.6	BELOW	BELOW	BELOW	BELOW
PATIENT	110	1.3	0.8	20 lbs	3.9 max	2.95	

ULTRASONOGRAPHIC FINDINGS

Partially compensated valvular disease.

INTERPRETATION OF THE FINDINGS & FURTHER RECOMMENDATIONS

Given the current protocol I recommend adding Lasix at 2 mg/kg b.i.d. given the elevated systolic pressure Telmisartan can be considered. I recommend reducing Spironolactone to s.i.d. dosing at 1-2 mg/kg. Rehceck echocardiogram is recommended in 3 months. Considerable improvement has occurred in this patient. However, I recommend refining on the additional measures.



PATIENT

Sammy Illescas

SPECIES

Canine

BREED

Miniature Schnauzer

SEX

Neutered male

AGE

11 years

WEIGHT

20 lbs

INTERPRETED BY

Eric Lindquist, DMV
DABVP, Cert. IVUSS

IMAGING PERFORMED BY

Heather

HOSPITAL NAME

Animal Care Center of
Flanders

REFERRING VET

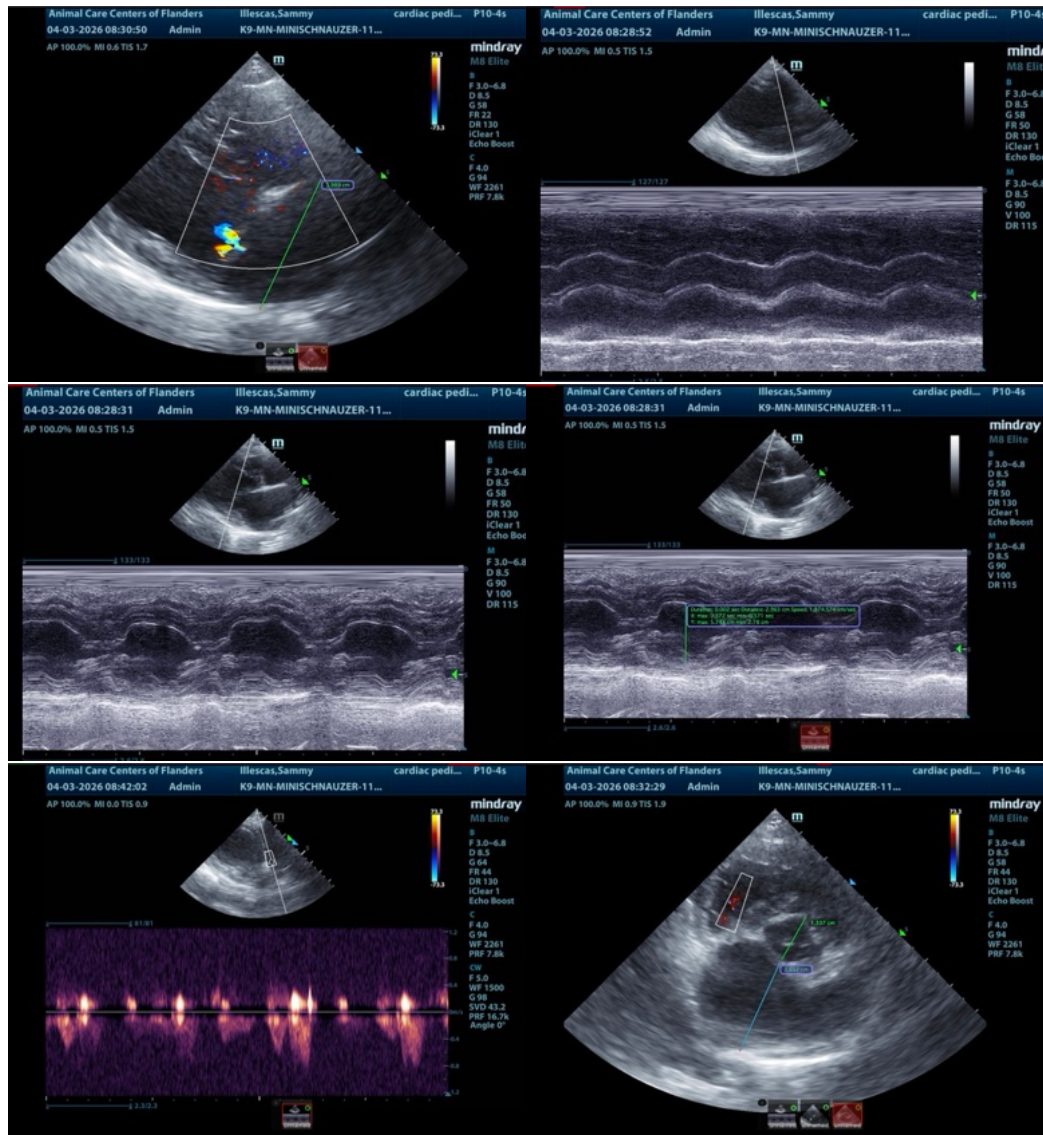
Dr. Hallihan

INVOICE

74134

DATE

4/3/26



The information and recommendations provided are based on the images presented by the referring veterinarian/sonographer. No evaluation can be communicated regarding pathology that was not visible in the image/video clips provided.

Thank you for this referral. If the clinical or image interpretation does not parallel your findings or if I can be of any further assistance please contact me.

Eric Lindquist, DMV, DABVP (CFM), Cert. IVUSS, CEO of SonoPath.com

info@SonoPath.com