



PATIENT

Ginger Fernandez

SPECIES

Canine

BREED

Poodle

SEX

Spayed Female

AGE

6 Years 10 Months

WEIGHT

8.2 pounds

INTERPRETED BY

Eric Lindquist, DMV,
DABVP(CFM), Cert.
IVUSS

IMAGING PERFORMED BY

Vincent Ravancho CVT

HOSPITAL NAME

Englewood Veterinary
Clinic

REFERRING VET

Dr. Ezik

INVOICE

14842

DATE

04/03/26

PRESENTING CLINICAL SIGNS

Hx of urinary calculi previously removed surgically. Currently on urinary diet (C/D). Treated for UTI last week. Serial urinalyses show a progressive decline in USG (1.046 - 1.022 - 1.019 - 1.017) Chemistry unremarkable with BUN, creatinine, and SDMA WNL. U/S request to evaluate renal parenchyma and architecture of early or subclinical renal disease. Assess urinary bladder for recurrent uroliths, sediment, mural changes, or other abnormalities that may predispose to infection or contribute to decreased urine concentrating ability.

Abnormal PE/Chem/CBC/UA Results: U/A - marked cocci USG 1.017

ULTRASONOGRAPHIC EXAMINATION OF THE ABDOMEN

Urinary System

The **urinary bladder**, trigone, and pelvic urethra to a depth of 2.0 cm presented normal thicknesses and normal tone. The ureters were not visible which is normal. No uroliths or sediment were visualized, and anechoic urine was present. No evidence of inflammatory or neoplastic changes were noted. Ureteral papillae were normal.

The **kidneys** revealed normal size and structure, corticomedullary definition and ratio for this age. The cortices presented largely uniform texture with normal echogenic relationship to liver and spleen. Medullary structure differed distinctly from the cortex and no evidence of pelvic dilation was present. The capsules were acceptably uniform without significant irregularities. The left kidney measured 3.99 cm in length. The right kidney measured 3.37 cm in length.

Adrenal Glands

Both **adrenal glands** were visualized and recognized as having normal shape, size, position and echogenicity for this breed. The phrenic vasculature, glandular echogenicity and detail were unremarkable. Capsule, cortex, and medullary definition were normal for this age patient. The left adrenal gland measured 0.27 cm width at the cranial pole and 0.25 cm width at the caudal pole. The right adrenal gland measured 0.44 cm width at the cranial pole and 0.30 cm width at the caudal pole.

Spleen

The **spleen** presented a smooth homogeneous parenchyma hyperechoic to liver and renal cortical parenchyma. The capsule was smooth without noticeable expansion or deviation from within the spleen or adjacent pathology. The splenic vasculature demonstrated normal volume without signs of congestion or thrombosis. No sonographic evidence of acute or chronic inflammatory, neoplastic, or infarctual changes were noted.

Liver

The **liver** images submitted revealed subjectively normal liver size, contour, and structure. Parenchymal echogenicity was naturally coarse and hypoechoic to the spleen. Vascular and biliary tracts were of normal volume with no evidence of congestion. The gallbladder presented acceptably thin walls with primarily anechoic content. The cystic and common bile ducts were normal. No pathological hepatic lymphadenopathy was evident. No overt structural evidence of inflammatory, infiltrative or regenerative pathology was evident.



PATIENT

Ginger Fernandez

SPECIES

Canine

BREED

Poodle

SEX

Spayed Female

AGE

6 Years 10 Months

WEIGHT

8.2 pounds

INTERPRETED BY

Eric Lindquist, DMV,
 DABVP(CFM), Cert.
 IVUSS

IMAGING PERFORMED BY

Vincent Ravancho CVT

HOSPITAL NAME

Englewood Veterinary
 Clinic

REFERRING VET

Dr. Ezik

INVOICE

14842

DATE

04/03/26

Gastrointestinal

Examination of the **gastrointestinal tract** revealed a stomach and intestine free of stasis, of normal wall thickness, acceptable curvilinear mural detail, and peristaltic activity. Small and large intestine demonstrated normal luminal chyme and stool consistency respectively. No obstructive or overt infiltrative disease was noted. No associated abnormal lymphatic activity was noted.

Pancreas

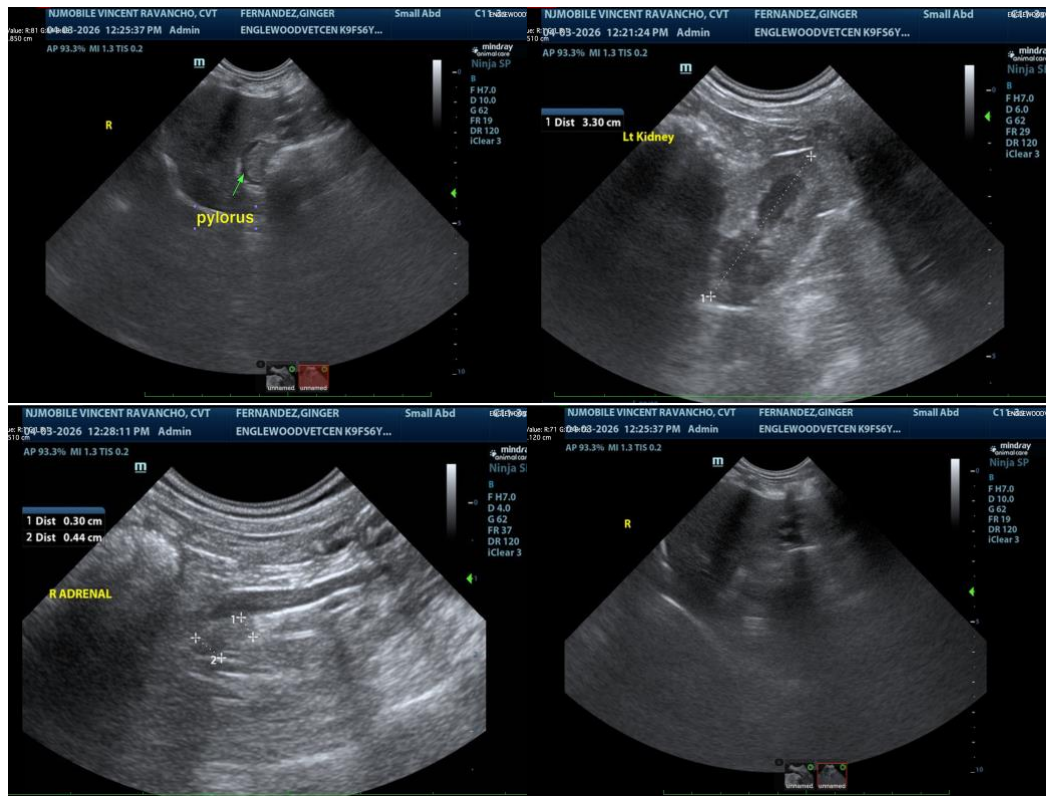
The base and limbs of the **pancreas** were observed to be largely isoechoic to surrounding omental fat. Pancreatic duct and capsular contour were acceptably normal and parenchyma respected normal curvilinear patterns. No overt evidence of active inflammatory or neoplastic disease was noted.

ULTRASONOGRAPHIC FINDINGS

- Structurally unremarkable abdomen.

INTERPRETATION OF THE FINDINGS & FURTHER RECOMMENDATIONS

No evidence of urolithiasis or other pathology.





PATIENT

Ginger Fernandez

SPECIES

Canine

BREED

Poodle

SEX

Spayed Female

AGE

6 Years 10 Months

WEIGHT

8.2 pounds

INTERPRETED BY

Eric Lindquist, DMV,
 DABVP(CFM), Cert.
 IUUSS

IMAGING PERFORMED BY

Vincent Ravancho CVT

HOSPITAL NAME

Englewood Veterinary
 Clinic

REFERRING VET

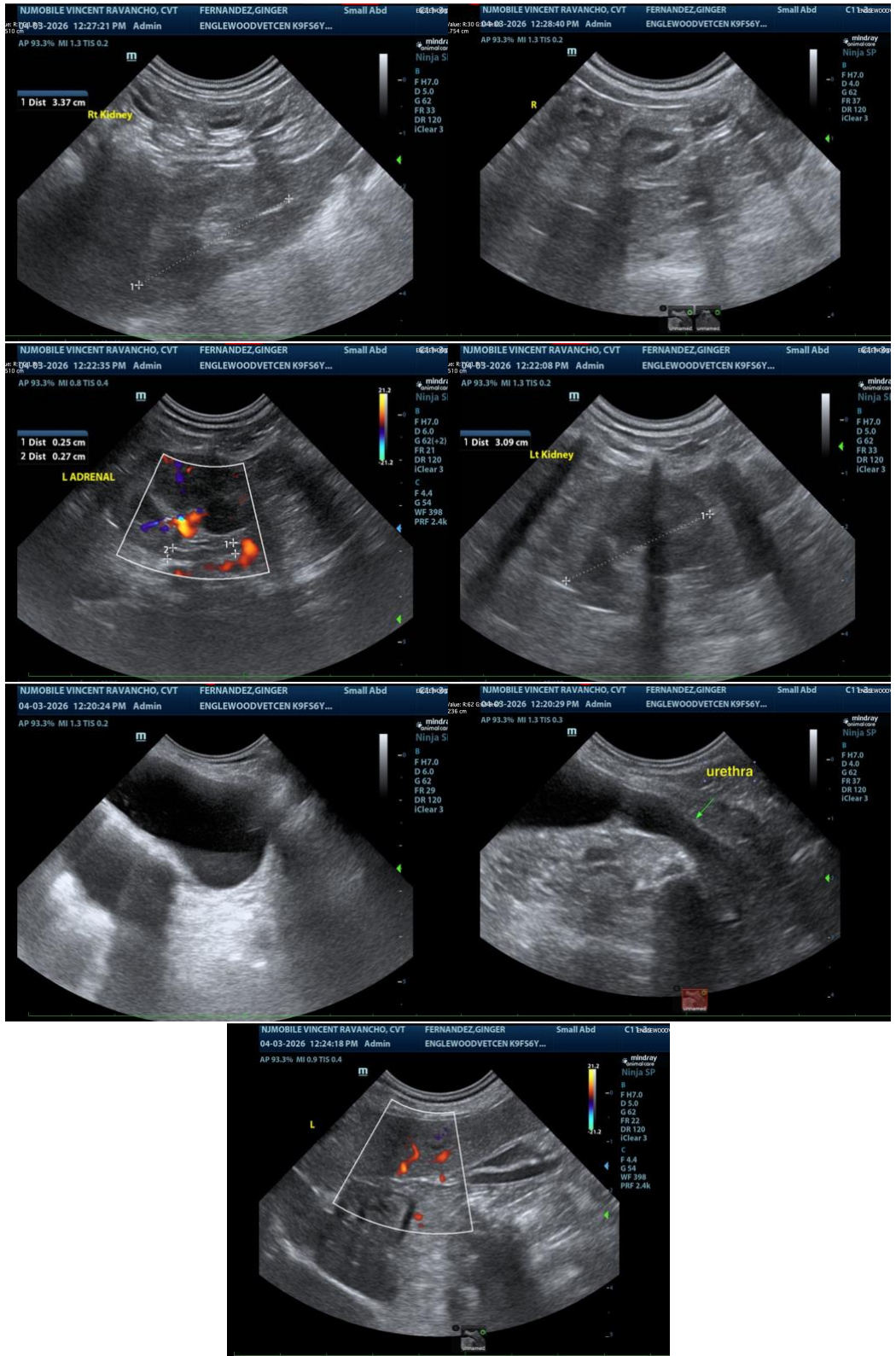
Dr. Ezik

INVOICE

14842

DATE

04/03/26





PATIENT

Ginger Fernandez

The information and recommendations provided are based on the images presented by the referring veterinarian/sonographer. No evaluation can be communicated regarding pathology that was not visible in the image/video clips provided.

SPECIES

Canine

Thank you for this referral. If the clinical or image interpretation does not parallel your findings or if I can be of any further assistance, please contact me.

BREED

Poodle

Eric Lindquist, DMV, DABVP(CFM), Cert. IVUSS,

CEO, Owner, Founder -- SonoPath.com

info@SonoPath.com

SEX

Spayed Female

AGE

6 Years 10 Months

WEIGHT

8.2 pounds

INTERPRETED BY

Eric Lindquist, DMV,
DABVP(CFM), Cert.
IVUSS

**IMAGING
PERFORMED BY**

Vincent Ravancho CVT

HOSPITAL NAME

Englewood Veterinary
Clinic

REFERRING VET

Dr. Ezik

INVOICE

14842

DATE

04/03/26