



PATIENT

Frederick
Harounzadeh

SPECIES

Feline

BREED

Scottish Fold

SEX

Neutered male

AGE

6 years

WEIGHT

10.6 lbs

INTERPRETED BY

Eric Lindquist, DMV
DABVP, Cert. IVUS

IMAGING PERFORMED BY

Jocelyn Smith, CVT

HOSPITAL NAME

Anville Cleona
Veterinary Associates

REFERRING VET

Dr. Keck

INVOICE

74136

DATE

4/3/26

PRESENTING CLINICAL SIGNS

- Pro BNP 102 pmol/L 3/23/26
- Previous vet requested echocardiogram prior to performing a dental procedure.

ULTRASONOGRAPHIC EXAMINATION OF THE HEART

The echocardiogram in this patient demonstrated normal **left atrial** size based on 3 separate LA measurements. The cranial and caudal **mitral** valve leaflets presented normal linear structure and kinetics. The **left ventricle** presented normal thicknesses with linear contour and was not dilated nor restricted. The **myocardium** presented normal echogenicity without subjective evidence of significant fibrotic or ischemic disease. **Contractility** of the ventricular walls was adequate and in normal range for this patient evidenced by the fractional shortening measurement and subjective evaluation of the different regions and angles of the myocardium. The **left ventricular outflow** tract demonstrated normal laminar flow and subjective structural integrity. The **right atrium** and auricle revealed normal size, structure and content. No evidence of masses was noted or chamber overload. **Tricuspid** valvular assessment demonstrated adequate linear morphology and kinetics. The **right ventricle** was of normal size (1/3 diameter of LV), chordae structure, myocardial echogenicity and thickness. **Pulmonic** tract assessment revealed normal valve structure, laminar flow, and diameter (approx.1:1 pa/ao ratio). No visible **pericardial** or free pleura fluid was noted or extra cardiac pathology in the visible planes. The cranial **mediastinum and pericardial regions** were free of masses in the visible window.

FELINE CARDIAC PARAMETERS	BODY WEIGHT	HR (BPM)	IVSd (cm)	LVIDd (cm)	LVWd (cm)	FS (%)	EF (%)
NORMAL PARAMETER	-----	150-240	0.3-0.6	1.0-2.1	0.25-0.6	35-67	80-100
PATIENT	10.6 lbs	130	0.5	1.1	0.5	50	80
FELINE CARDIAC PARAMETERS	LA/AO (M-mode)	LA/AO HEART BASE (Sisson)	LAD LA MAX 4 Chamber		LVOT VEL. (m/s)	RVOT VEL. (m/s)	IVRT (m/)
NORMAL PARAMETER	<1.5	1.6	0.7-1.7		<1.6	<1.3	40-60
PATIENT	1.0	1.2	1.15 max		NM	0.8	NM
Adapted from June Boon, Veterinary Echocardiography, 1998 Sisson D et al. JVIM 1991; 5: 232, Jacobs et al. Am J Vet Res 1985; 46:1705							

ULTRASONOGRAPHIC FINDINGS

Normal echocardiogram.



PATIENT

Frederick Harounzadeh

SPECIES

Feline

BREED

Scottish Fold

SEX

Neutered male

AGE

6 years

WEIGHT

10.6 lbs

INTERPRETED BY

Eric Lindquist, DMV DABVP, Cert. IVUSS

IMAGING PERFORMED BY

Jocelyn Smith, CVT

HOSPITAL NAME

Annville Cleona Veterinary Associates

REFERRING VET

Dr. Keck

INVOICE

74136

DATE

4/3/26

INTERPRETATION OF THE FINDINGS & FURTHER RECOMMENDATIONS

There was no evidence of pathology.

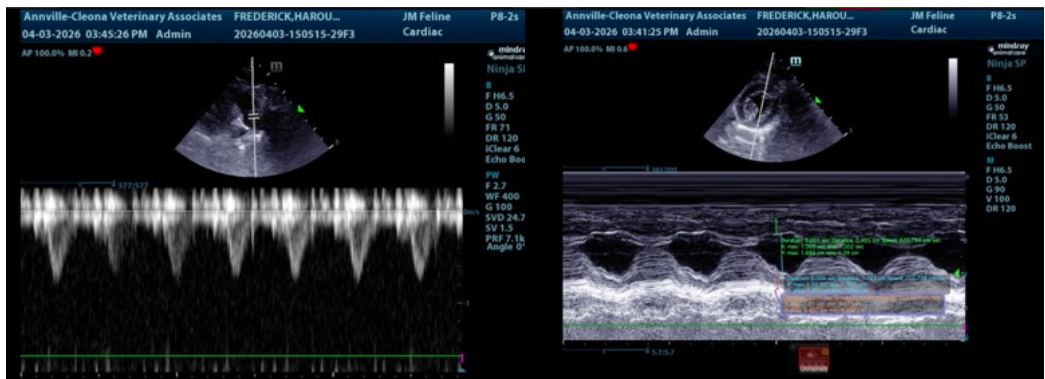
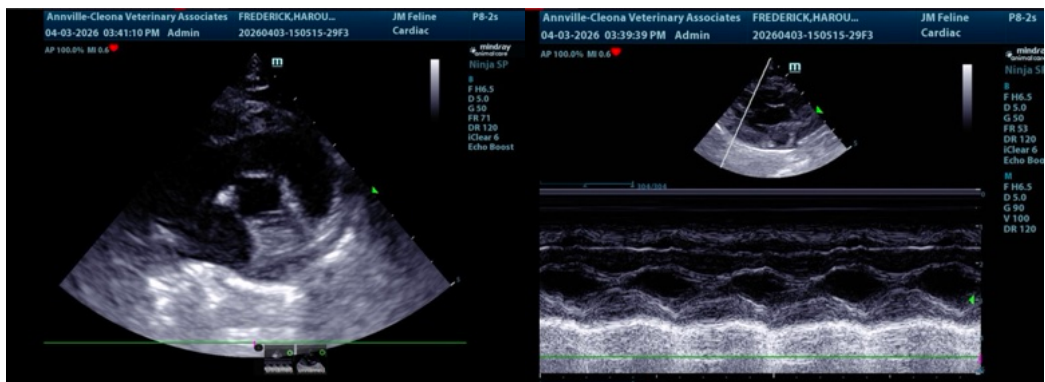
Bio markers such as NT-proBNP are screening tests for myocardial stress. A positive test (>100 pmol/liter) does not mean that cardiac disease is necessarily present.

BNP false +can occur in hyperthyroid, renal insufficiency, severe airway disease, systemic hypertension and potentially other systemic influences.

A negative result largely rules out clinically relevant myocardial disease but does not rule out occult cardiomyopathy.

In cases of pleural effusion, diluting the fluid 1:1 and testing BNP on the fluid is useful to assess if the pleural effusion is cardiogenic in nature.

Ultrasound, however, is the gold standard as far as evaluating clinically significant and occult heart disease.





PATIENT

Frederick
Harounzadeh

SPECIES

Feline

BREED

Scottish Fold

SEX

Neutered male

AGE

6 years

WEIGHT

10.6 lbs

INTERPRETED BY

Eric Lindquist, DMV
DABVP, Cert. IVUSS

IMAGING PERFORMED BY

Jocelyn Smith, CVT

HOSPITAL NAME

Annvile Cleona
Veterinary Associates

REFERRING VET

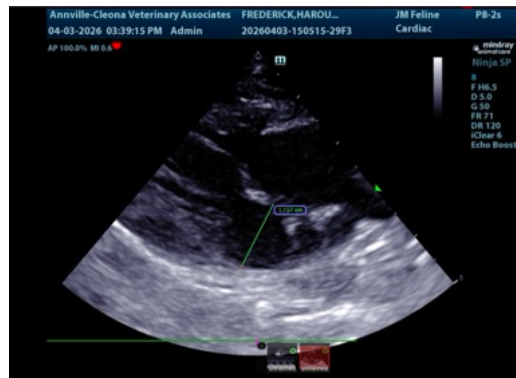
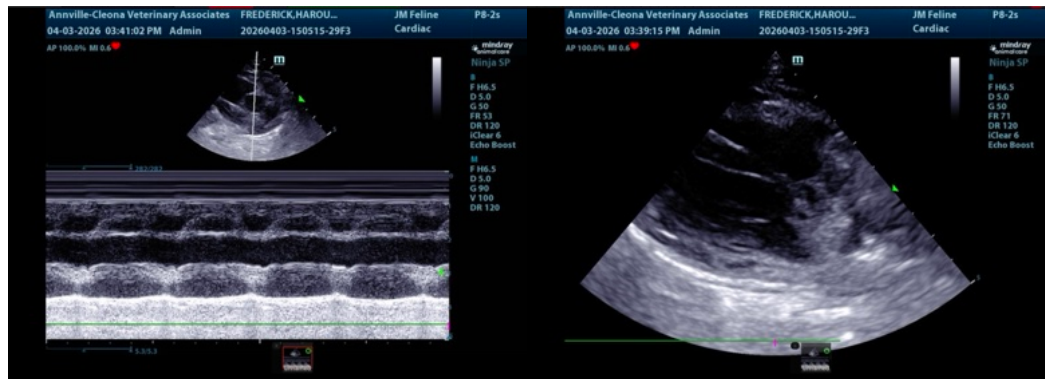
Dr. Keck

INVOICE

74136

DATE

4/3/26



The information and recommendations provided are based on the images presented by the referring veterinarian/sonographer. No evaluation can be communicated regarding pathology that was not visible in the image/video clips provided.

Thank you for this referral. If the clinical or image interpretation does not parallel your findings or if I can be of any further assistance please contact me.

Eric Lindquist, DMV, DABVP (CFM), Cert. IVUSS, CEO of SonoPath.com

info@SonoPath.com