



PATIENT

Cora Bonarrigo

SPECIES

Canine

BREED

Pembroke Welsh Corgi

SEX

Female

AGE

11 months

WEIGHT

20.6 lbs

INTERPRETED BY

Eric Lindquist, DMV
DABVP, Cert. IVUSS

IMAGING PERFORMED BY

Dr. Anleu

HOSPITAL NAME

Ellwood AH

REFERRING VET

Dr. Jones

INVOICE

74135

DATE

4/3/26

PRESENTING CLINICAL SIGNS

- Pre-anesthetic EKG shows supraventricular arrhythmia
- Normal Cardiopet ProBNP of 250 (normal range 0-900)

ULTRASONOGRAPHIC EXAMINATION OF THE HEART

The echocardiogram in this patient demonstrated normal **left atrial** size based on 3 separate methods of LA evaluation. The cranial and caudal **mitral** valve leaflets presented normal linear structure, extension in systole, and union in diastole with normal kinesis. The **left ventricle** presented thicknesses with linear contour and was not dilated nor restricted. The **myocardium** presented normal echogenicity without subjective evidence of significant fibrotic or ischemic disease. **Contractility** of the ventricular walls was adequate and in normal range for this patient evidenced by the fractional shortening measurement and subjective evaluation of the different regions of the myocardium. The **left ventricular outflow** tract demonstrated normal laminar flow and subjective structural integrity. The **right atrium** and auricle revealed normal size, structure and content. No evidence of masses was noted. **Tricuspid** valvular assessment demonstrated adequate linear morphology and kinesis. The **right ventricle** was of normal size (1/3 diameter of LV), chordae structure, myocardial echogenicity and thickness. **Pulmonary outflow** tract assessment revealed normal valve structure, laminar flow, and diameter (approx. 1:1 pa/ao ratio). No visible **pericardial** or free pleura fluid was noted. The cranial **mediastinum and pericardial and extra-cardiac regions** were free of masses in the visible window.

CANINE CARDIAC PARAMETERS	MR VMAX (m/s)	TR VMAX (m/s)	LA/AO	LA/AO (Heart Base)	FS (%)	EF (%)	EPSS (cm)
NORMAL PARAMETER	4.5-5.5	<2.7	1.3	<1.6	28-40	40-100	<0.6
PATIENT	-	-	1.1	1.1	50	70	0.1
CANINE CARDIAC PARAMETERS	HR (BPM)	AV VMAX (m/s)	PV MAX (m/s)	BODY WEIGHT	LA 2D short axis Base view (cm)	LVIDd Avg; 2D and m-mode short axis (cm)	LVIDs Avg; 2D and m-mode short axis (cm)
NORMAL PARAMETER	50-100	0.7-1.7	0.7-1.6	BELOW	BELOW	BELOW	BELOW
PATIENT	70	1.26	0.6	20.6 lbs	2.9 max	2.9	

ULTRASONOGRAPHIC FINDINGS

Structurally and functionally normal heart.



PATIENT

Cora Bonarrigo

SPECIES

Canine

BREED

Pembroke Welsh Corgi

SEX

Female

AGE

11 months

WEIGHT

20.6 lbs

INTERPRETED BY

Eric Lindquist, DMV
DABVP, Cert. IVUSS

IMAGING PERFORMED BY

Dr. Anleu

HOSPITAL NAME

Ellwood AH

REFERRING VET

Dr. Jones

INVOICE

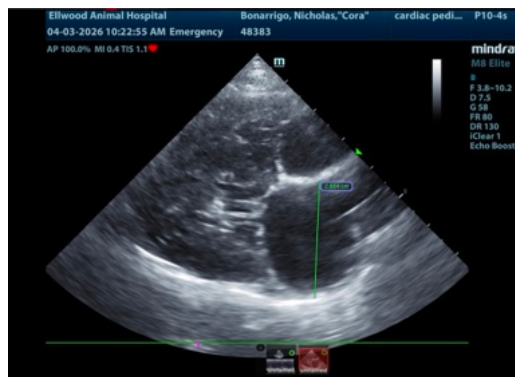
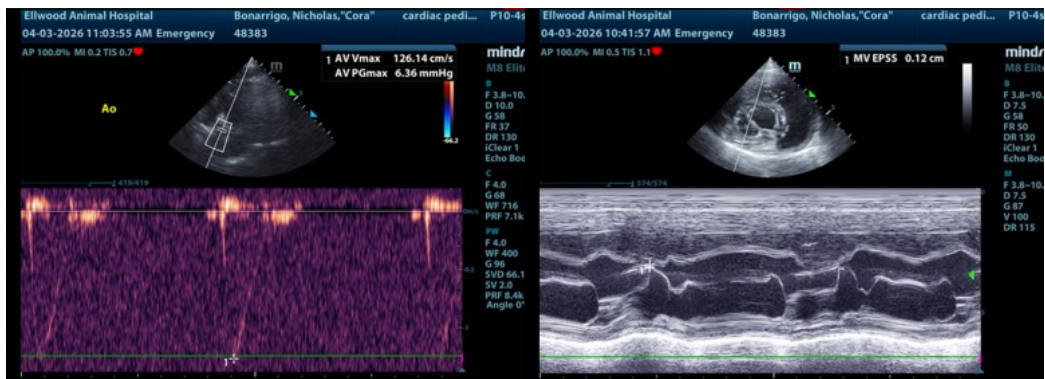
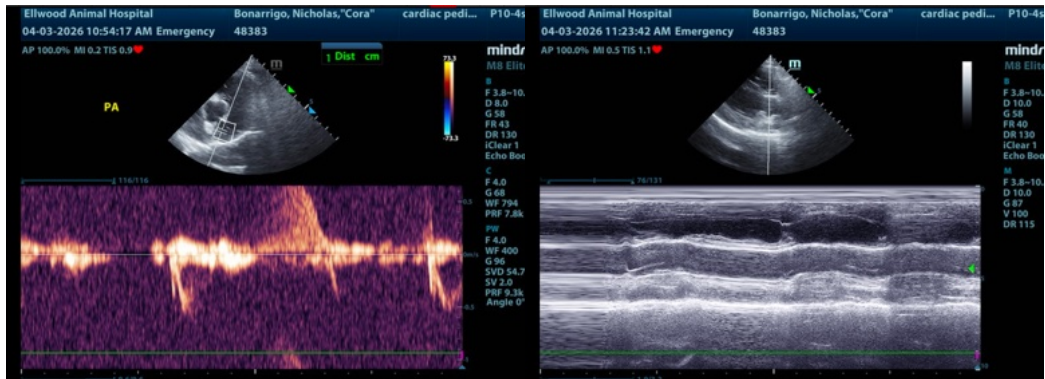
74135

DATE

4/3/26

INTERPRETATION OF THE FINDINGS & FURTHER RECOMMENDATIONS

I recommend management based on EKG results. Causes of myocardial irritation such as occult infectious disease should be considered. Holter monitor would be ideal. This can be obtained from our office, yet no evidence of structural disease was noted.



The information and recommendations provided are based on the images presented by the referring veterinarian/sonographer. No evaluation can be communicated regarding pathology that was not visible in the image/video clips provided.

Thank you for this referral. If the clinical or image interpretation does not parallel your findings or if I



PATIENT

Cora Bonarrigo

SPECIES

Canine

BREED

Pembroke Welsh Corgi

SEX

Female

AGE

11 months

WEIGHT

20.6 lbs

INTERPRETED BY

Eric Lindquist, DMV
DABVP, Cert. IVUSS

**IMAGING
PERFORMED BY**

Dr. Anleu

HOSPITAL NAME

Ellwood AH

REFERRING VET

Dr. Jones

INVOICE

74135

DATE

4/3/26

can be of any further assistance please contact me.

Eric Lindquist, DMV, DABVP (CFM), Cert. IVUSS, CEO of SonoPath.com

info@SonoPath.com