



PATIENT

Bubusjka al Khulaify

SPECIES

Feline

BREED

Scottish Fold

SEX

Female

AGE

4 Years

WEIGHT

3.0 kg

PRESENTING CLINICAL SIGNS

History: Enlarged heart, got worse after vaccine.

ULTRASONOGRAPHIC EXAMINATION OF THE HEART

FELINE CARDIAC PARAMETERS	BODY WEIGHT (kg)	HR (BPM)	IVSd (cm)	LVIDd (cm)	LVWd (cm)	FS (%)	EF (%)
NORMAL PARAMETER	-----	150-240	0.3-0.6	1.0-2.1	0.25-0.6	35-67	80-100
PATIENT	3.0 kg	~190	--	--	--	--	--
FELINE CARDIAC PARAMETERS	LA/AO (M-mode)	LA/AO HEART BASE (Sisson)	LAD LA MAX 4 Chamber		LVOT VEL (m/s)	RVOT VEL (m/s)	IVRT (m/)
NORMAL PARAMETER	<1.5	1.6	0.7-1.7		<1.6	<1.3	40-60
PATIENT	--	1.9	1.8		--	--	NM
Adapted from June Boon, Veterinary Echocardiography, 1998 Sisson D et al. JVIM 1991; 5: 232, Jacobs et al. Am J Vet Res 1985; 46:1705							

INTERPRETED BY

Eric Lindquist, DMV, DABVP (Canine & Feline), Cert. IVUSS

IMAGING PERFORMED BY

Dr. Samad Khan

HOSPITAL NAME

The Veterinary Surgery

REFERRING VET

Dr. Samad Khan

INVOICE

36471

DATE

4/3/26

Cardiac Presentation

Multiple images were submitted with volume overload of the left heart and left ventricular hypertrophy. Some views revealed a separation of the epicardium from the pericardium with a fat density; an odd angle was also noted with the heart that would suggest a pericardial diaphragmatic hernia. There is volume overload and mitral insufficiency in the left atrium. In one view, there is a possibility of ventricular septal defect, however, further imaging is necessary.

ULTRASONOGRAPHIC FINDINGS

- Hypertrophic cardiomyopathy with potential pericardial diaphragmatic hernia to be confirmed by radiographs and cranial abdominal sonogram.

INTERPRETATION OF THE FINDINGS & FURTHER RECOMMENDATIONS

Abdominal sonogram is recommended to assess for potential hernia formation. Low dose Lasix and ACE inhibitor would be indicated.



PATIENT

Bubusjka al Khulaify

SPECIES

Feline

BREED

Scottish Fold

SEX

Female

AGE

4 Years

WEIGHT

3.0 kg

INTERPRETED BY

Eric Lindquist, DMV,
DABVP (Canine &
Feline), Cert. IVUSS

**IMAGING
PERFORMED BY**

Dr. Samad Khan

HOSPITAL NAME

The Veterinary Surgery

REFERRING VET

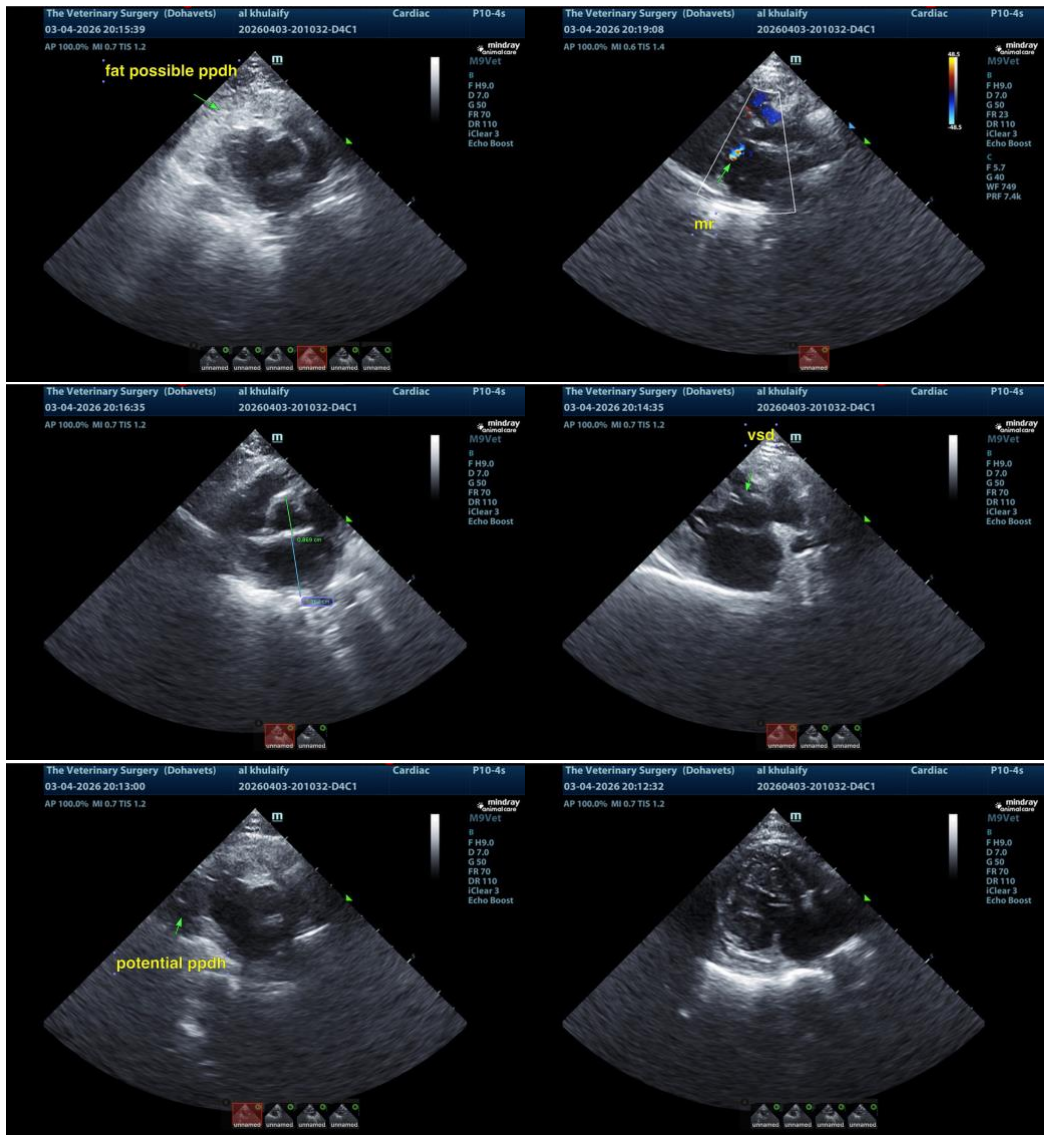
Dr. Samad Khan

INVOICE

36471

DATE

4/3/26



The information and recommendations provided are based on the images presented by the referring veterinarian/sonographer. No evaluation can be communicated regarding pathology that was not visible in the image/video clips provided.

Thank you for this referral. If the clinical or image interpretation does not parallel your findings or if I can be of any further assistance please contact me.

Eric Lindquist, DMV, DABVP(CFM), Cert. IVUSS,
CEO, Owner, Founder -- SonoPath.com
info@SonoPath.com