



PATIENT

Lulu Luchenbill

SPECIES

Canine

BREED

Poodle

SEX

Female

AGE

15 Years 5 Months

WEIGHT

5.6 Pounds

INTERPRETED BY

Eric Lindquist, DMV
DABVP, Cert. IVUSS

IMAGING PERFORMED BY

Adrienne Waffle

HOSPITAL NAME

Torch Lake VC

REFERRING VET

Dr. Loretta Pattenburg-
Bellaire AH

INVOICE

21825

DATE

4/3/23

PRESENTING CLINICAL SIGNS

History: P presented on referral. P is excessively drinking and urinating. Malodorous vulvar discharge. Eating well. P improved with round of antibiotics. Then declined when finished.

ULTRASONOGRAPHIC EXAMINATION OF THE ABDOMEN

Urinary System

A polypoid mass was noted in the **urinary bladder** (measuring 1.7 cm), deriving from the ventral wall. The bladder was normal otherwise.

The **kidneys** revealed largely normal size and structure, corticomedullary definition and ratio (cortex 1/3 of medulla) were essentially maintained with some moderate age-related loss of curvilinear patterns regarding the capsule and C/M junction. The cortices presented largely uniform texture with some increased echogenicity expected for his age patient. Medullary structure differed distinctly from that of the cortex and no evidence of pelvic dilation was present. The left kidney measured 3.0 cm. The right kidney measured 2.77 cm. A hyperechoic medullary rim sign was noted bilaterally.

Adrenal Glands

The regions of the **adrenal glands** were imaged and revealed no evident pathology

Spleen

The **spleen** presented a smooth homogeneous parenchyma hyperechoic to liver and renal cortical parenchyma. The capsule was smooth without noticeable expansion or deviation from within the spleen or adjacent pathology. The splenic vasculature demonstrated normal volume without signs of congestion or thrombosis. No sonographic evidence of acute or chronic inflammatory, neoplastic, or infarctual changes were noted.

Liver

The **liver** images from right and left intercostal as well as subcostal views revealed subjectively normal liver size, contour, and structure. Some mild age-related parenchymal remodeling was noted but likely not clinically significant at this time. Vascular and biliary tracts were of normal volume and no evidence of congestion was noted. The gallbladder presented some dependent debris with essentially normal contour. The cystic and common bile ducts were normal. No overt evidence of active inflammatory, infiltrative or regenerative pathology was noted but should be paired with current or past LE elevations regarding any clinical significance to this presentation. The hepatic lymph nodes were unremarkable.

Gastrointestinal

The **gastrointestinal tract** presented considerable gastric artifact due to the presence of ingesta. This did not permit thorough evaluation of portions of the gastric and upper intestinal structure. No overt abnormality was seen in the visualized tissue, however. This is consistent with a post-prandial presentation within a few hours of mealtime. If the prandial temporal interval does not fit the case history, and the patient presents a history of post-prandial vomiting, this could indicate a delayed upper gastrointestinal outflow due to primary or secondary pyloric hypertrophy, upper GI infiltrative disease, motor deficits, or a non-visualized foreign body. A prudent approach would be to rescan this



PATIENT

Lulu Luchenbill

patient at 24 hour NPO status to further review the non-visible regions if stomach primarily as well as assess any delayed outflow issue.

Pancreas

SPECIES

Canine

The base and limbs of the **pancreas** were observed to be largely isoechoic to surrounding omental fat. Pancreatic duct and capsular contour were acceptably normal and parenchyma respected normal curvilinear patterns. No overt evidence of active inflammatory or neoplastic disease was noted.

BREED

Poodle

Other

The **uterus** was thickened (1.4 cm in width) with slight fluid filled lumen. The regions of the ovaries were unremarkable.

SEX

Female

ULTRASONOGRAPHIC FINDINGS

- Thickened uterus, possible open pyometra
- Ventral bladder wall mass, appears resectable
- Hyperechoic medullary rim sign bilaterally
- Age-related hepatic changes
- Full stomach

AGE

15 Years 5 Months

INTERPRETATION OF THE FINDINGS & FURTHER RECOMMENDATIONS

WEIGHT

5.6 Pounds

Ovariohysterectomy and ventral bladder wall resection are indicated.

INTERPRETED BY

Eric Lindquist, DMV
DABVP, Cert. IVUSS

IMAGING PERFORMED BY

Adrienne Waffle

HOSPITAL NAME

Torch Lake VC

REFERRING VET

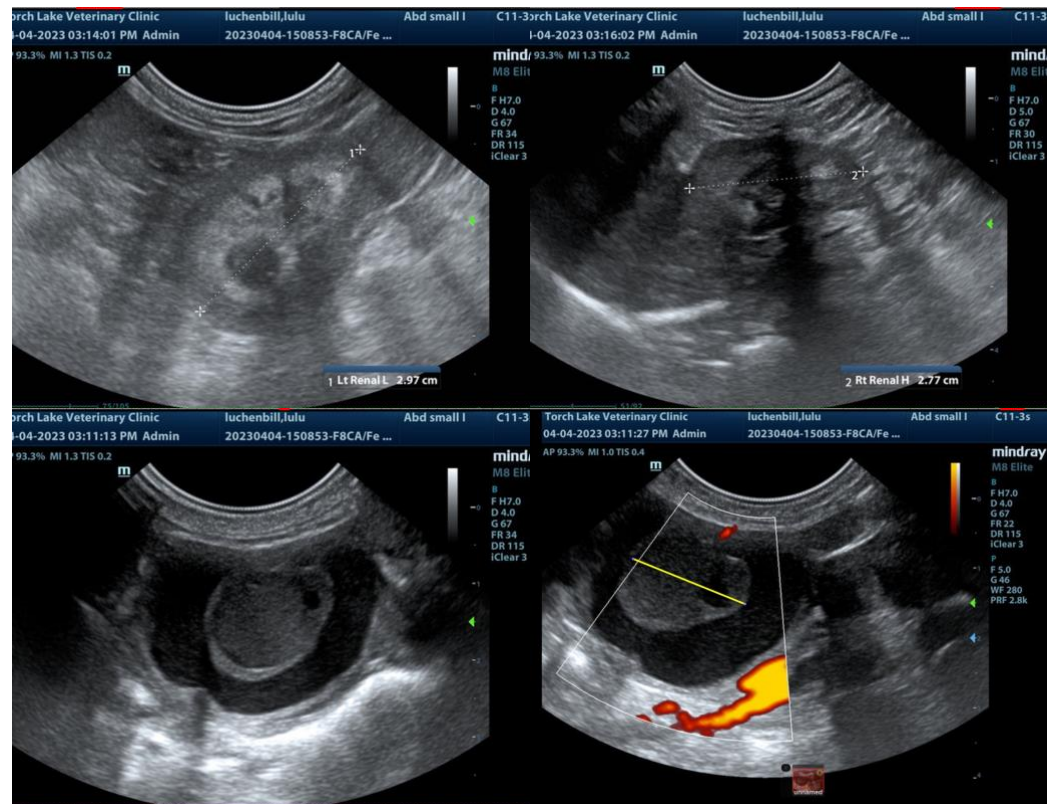
Dr. Loretta Pattenburg-
Bellaire AH

INVOICE

21825

DATE

4/3/23





PATIENT

Lulu Luchenbill

SPECIES

Canine

BREED

Poodle

SEX

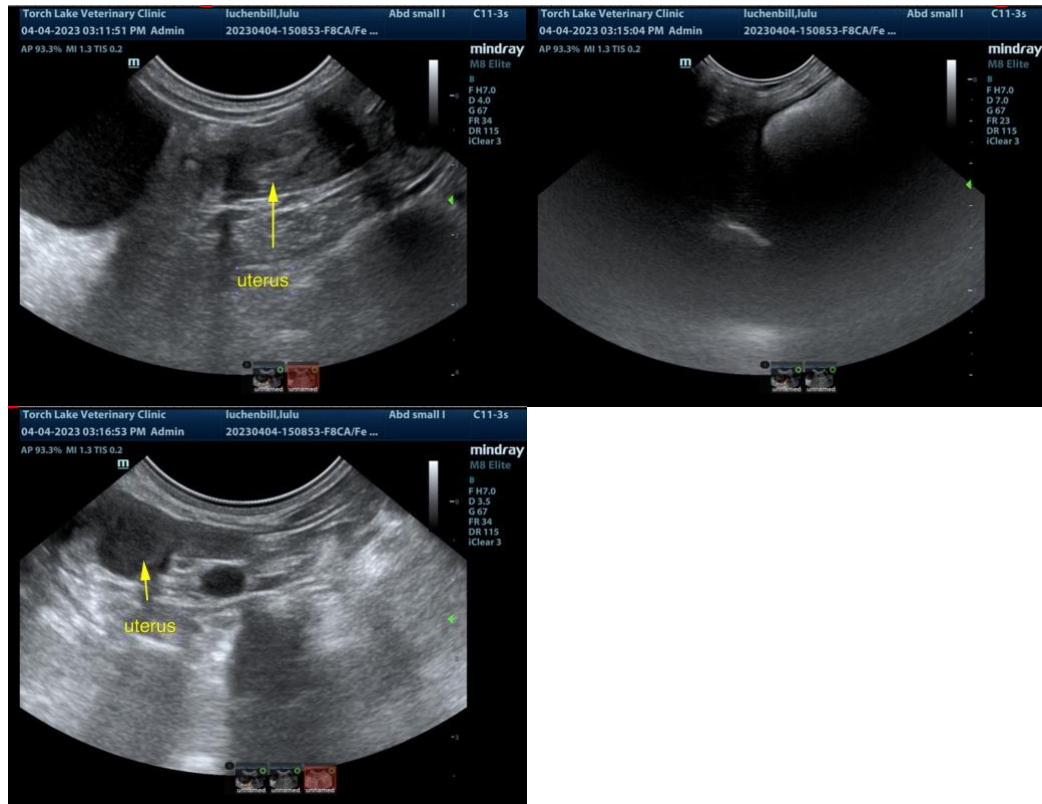
Female

AGE

15 Years 5 Months

WEIGHT

5.6 Pounds



INTERPRETED BY

Eric Lindquist, DMV
DABVP, Cert. IVUSS

IMAGING PERFORMED BY

Adrienne Waffle

HOSPITAL NAME

Torch Lake VC

REFERRING VET

Dr. Loretta Pattenburg-
Bellaire AH

INVOICE

21825

DATE

4/3/23

The information and recommendations provided are based on the images presented by the referring veterinarian. No evaluation can be communicated regarding pathology that was not visible in the image/video clips provided.

Thank you for this referral. If the clinical or image interpretation does not parallel your findings or if I can be of any further assistance please contact me.

Eric Lindquist, DMV, DABVP, Cert. IVUSS, CEO of SonoPath.com
info@SonoPath.com