



**PATIENT**

Gogo Hensley

**SPECIES**

Feline

**BREED**

Domestic Shorthair

**SEX**

Spayed female

**AGE**

8 years

**WEIGHT**

12 lbs

**INTERPRETED BY**

Eric Lindquist, DMV  
DABVP, Cert. IVUSS

**IMAGING PERFORMED BY**

Rachel Bunn

**HOSPITAL NAME**

Wellesley AH

**REFERRING VET**

Dr. Godwin

**INVOICE**

43685

**DATE**

4/3/23

**PRESENTING CLINICAL SIGNS**

History: Vomits several times monthly lifelong and has intermittent diarrhea; more recently not eating much but somewhat improved after cerenia dose

Abnormal PE/Chem/CBC/UA Results: None (CBC/Chem/UA/proBNP all normal)

**ULTRASONOGRAPHIC EXAMINATION OF THE ABDOMEN**

**Urinary System**

The **urinary bladder**, trigone, and pelvic urethra presented normal thicknesses and normal tone. The ureters were not visible which is normal. A trace amount of sand was noted. No evidence of inflammatory or neoplastic changes was noted. Ureteral papillae were normal.

The **kidneys** revealed largely normal size and structure, corticomedullary definition and ratio (cortex 1/3 of medulla) were essentially maintained with some age-related loss of curvilinear patterns regarding the capsule and C/M junction. The cortices presented largely uniform texture with some increased echogenicity expected for his age patient. Medullary structure differed distinctly from that of the cortex and no evidence of pelvic dilation was present. The left kidney measured 3.9 cm. The right kidney measured 3.76 cm.

**Adrenal Glands**

Both **adrenal glands** were visualized and recognized as having normal shape, size, position and echogenicity for this breed. The phrenic vasculature, glandular echogenicity and detail were unremarkable. Capsule, cortex, and medullary definition were normal for this age patient. The left adrenal gland measured 1.1 x 0.5 cm. The right adrenal gland measured 1.02 x 0.5 cm.

**Spleen**

The **spleen** presented a smooth homogeneous parenchyma hyperechoic to liver and renal cortical parenchyma. The capsule was smooth without noticeable expansion or deviation from within the spleen or adjacent pathology. The splenic vasculature demonstrated normal volume without signs of congestion or thrombosis. No sonographic evidence of acute or chronic inflammatory, neoplastic, or infarctual changes was noted.

**Liver**

The **liver** images submitted revealed subjectively normal liver size, contour, and structure. Parenchymal echogenicity was naturally coarse and hypoechoic to the spleen. Vascular and biliary tracts were of normal volume with no evidence of congestion. The gallbladder presented acceptably thin walls with primarily anechoic content. The cystic and common bile ducts were normal. No pathological hepatic lymphadenopathy was evident. No overt structural evidence of inflammatory, infiltrative or regenerative pathology was evident.



**PATIENT**

**Gastrointestinal**

Gogo Hensley

The **gastrointestinal** presentation revealed mild uniform prominence of the gastric mucosa as well as areas of "ropey" small intestinal wall with slight disruption of the normal 1:3 muscularis/mucosal ratio. The intestinal submucosa was slightly irregular, thickened and hyperechoic suggestive of low grade, chronic disease. No concerning lymphadenopathy was visible. No evidence of obstruction was present. Chronic inflammatory bowel disease is likely with a low possibility of an early neoplastic event such as lymphoma. Full thickness tissue biopsies via open laparotomy, ideally guided by intraoperative ultrasound in order to obtain the most representative mural sample, would be necessary to rule out this possibility.

**SPECIES**

Feline

**BREED**

Domestic Shorthair

**SEX**

Spayed female

**Pancreas**

The base and limbs of the **pancreas** were observed to be largely isoechoic to surrounding omental fat. Pancreatic duct and capsular contour were acceptably normal and parenchyma respected normal curvilinear patterns. No overt evidence of active inflammatory or neoplastic disease was noted.

**AGE**

8 years

**ULTRASONOGRAPHIC FINDINGS**

Structurally unremarkable abdomen with trace bladder sand.

**WEIGHT**

12 lbs

Non-obstructive renal nephrolithiasis and age related renal changes.

Minor intestinal thickening.

**INTERPRETED BY**

Eric Lindquist, DMV  
DABVP, Cert. IVUS

**INTERPRETATION OF THE FINDINGS & FURTHER RECOMMENDATIONS**

Management for inflammatory bowel is warranted. Hydrolyzed diet is recommended. Fecal exam is recommended as well as broad spectrum anti-parasitic protocol.

**IMAGING PERFORMED BY**

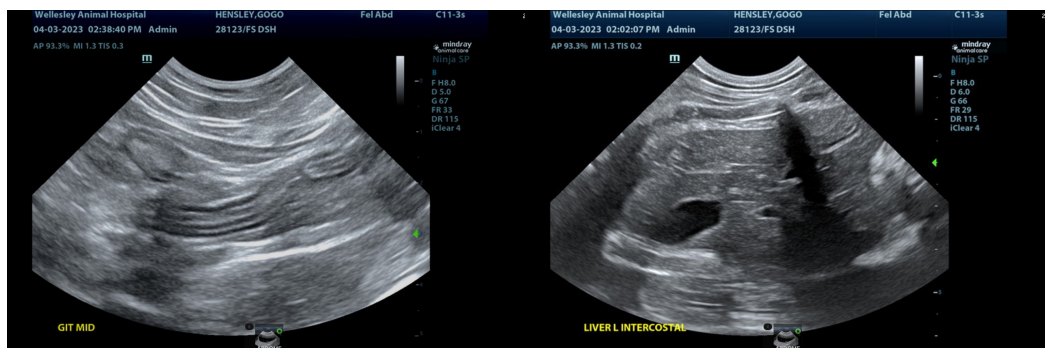
Rachel Bunn

**HOSPITAL NAME**

Wellesley AH

**REFERRING VET**

Dr. Godwin



**INVOICE**

43685

**DATE**

4/3/23



**PATIENT**

Gogo Hensley

**SPECIES**

Feline

**BREED**

Domestic Shorthair

**SEX**

Spayed female

**AGE**

8 years

**WEIGHT**

12 lbs

**INTERPRETED BY**

Eric Lindquist, DMV  
DABVP, Cert. IVUSS

**IMAGING PERFORMED BY**

Rachel Bunn

**HOSPITAL NAME**

Wellesley AH

**REFERRING VET**

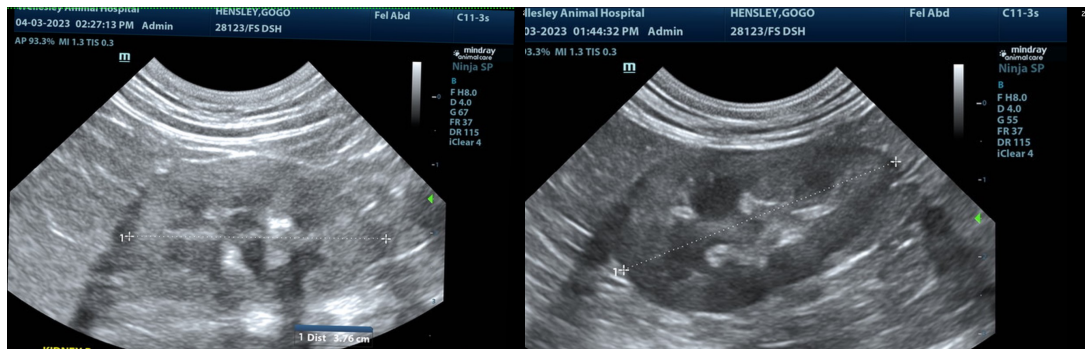
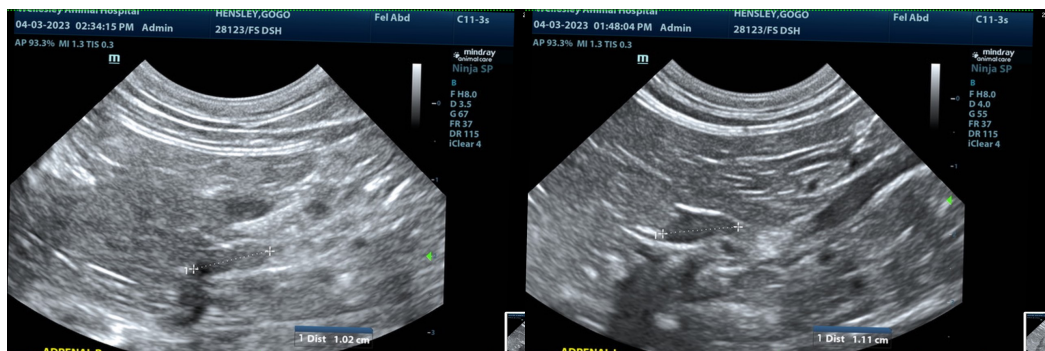
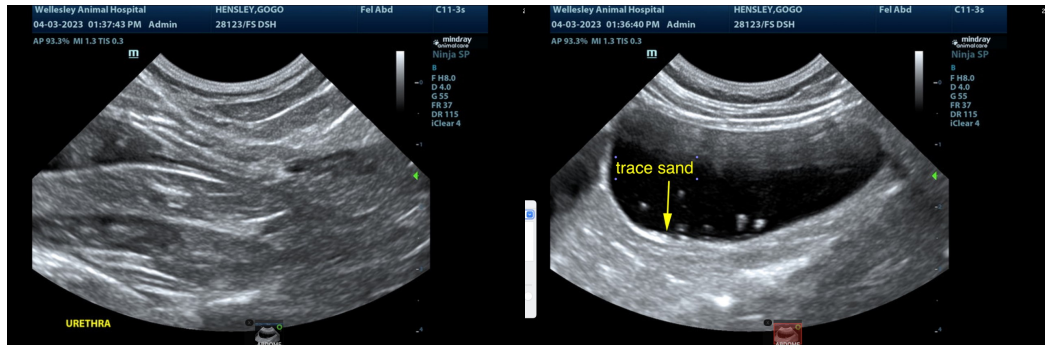
Dr. Godwin

**INVOICE**

43685

**DATE**

4/3/23



The information and recommendations provided are based on the images presented by the referring veterinarian/sonographer. No evaluation can be communicated regarding pathology that was not visible in the image/video clips provided.

Thank you for this referral. If the clinical or image interpretation does not parallel your findings or if I can be of any further assistance please contact me.

**Eric Lindquist, DMV, DABVP, Cert. IVUSS, CEO of SonoPath.com**  
info@SonoPath.com