



PATIENT

Tobi Taylor

SPECIES

Canine

BREED

Bichon Frise

SEX

Male

AGE

3

WEIGHT

5.5 kg

INTERPRETED BY

Eric Lindquist, DMV,
DABVP(CFM), Cert.
IVUSS

IMAGING PERFORMED BY

Shervin Akbarian

HOSPITAL NAME

Eagleson Veterinary
Clinic

REFERRING VET

Dr. Mohamed Zaid

INVOICE

15574

DATE

04/29/26

PRESENTING CLINICAL SIGNS

Decreased appetite and drinking, lethargy, regurgitation/gagging episodes, and suspected gastrointestinal discomfort.

ULTRASONOGRAPHIC EXAMINATION OF THE ABDOMEN

The image set provided revealed largely still images in video format. SDEP protocol is preferred.

Urinary System

The **urinary bladder**, trigone, and pelvic urethra presented normal thicknesses and normal tone. The ureters were not visible which is normal. No uroliths or sediment were visualized, and anechoic urine was present. No evidence of inflammatory or neoplastic changes were noted. Ureteral papillae were normal.

The **kidneys** revealed normal size and structure, corticomedullary definition and ratio for this age. The cortices presented largely uniform texture with normal echogenic relationship to liver and spleen. Medullary structure differed distinctly from the cortex and no evidence of pelvic dilation was present. The capsules were acceptably uniform without significant irregularities. The left kidney measured 3.6 cm in length. The right kidney measured 3.9 cm in length.

Adrenal Glands

The **right adrenal gland** was visualized and recognized as having normal shape, size, position and echogenicity for this breed. The phrenic vasculature, glandular echogenicity and detail were unremarkable. Capsule, cortex, and medullary definition were normal for this age patient. The right adrenal gland measured 0.50 cm width.

The **left adrenal gland** was not visualized.

Spleen

The **spleen** presented a smooth homogeneous parenchyma hyperechoic to liver and renal cortical parenchyma. The capsule was smooth without noticeable expansion or deviation from within the spleen or adjacent pathology. The splenic vasculature demonstrated normal volume without signs of congestion or thrombosis. No sonographic evidence of acute or chronic inflammatory, neoplastic, or infarctual changes were noted.

Liver

The **liver** images submitted revealed subjectively normal liver size, contour, and structure. Parenchymal echogenicity was naturally coarse and hypoechoic to the spleen. Vascular and biliary tracts were of normal volume with no evidence of congestion. The gallbladder presented acceptably thin walls with primarily anechoic content. The cystic and common bile ducts were normal. No pathological hepatic lymphadenopathy was evident. No overt structural evidence of inflammatory, infiltrative or regenerative pathology was evident.

Gastrointestinal

The **stomach** revealed gastric stasis/ileus without evidence of obstruction. The visible small intestine and colon were unremarkable.



PATIENT

Tobi Taylor

SPECIES

Canine

BREED

Bichon Frise

SEX

Male

AGE

3

WEIGHT

5.5 kg

INTERPRETED BY

Eric Lindquist, DMV,
DABVP(CFM), Cert.
IVUSS

IMAGING PERFORMED BY

Shervin Akbarian

HOSPITAL NAME

Eagleson Veterinary
Clinic

REFERRING VET

Dr. Mohamed Zaid

INVOICE

15574

DATE

04/29/26

Pancreas

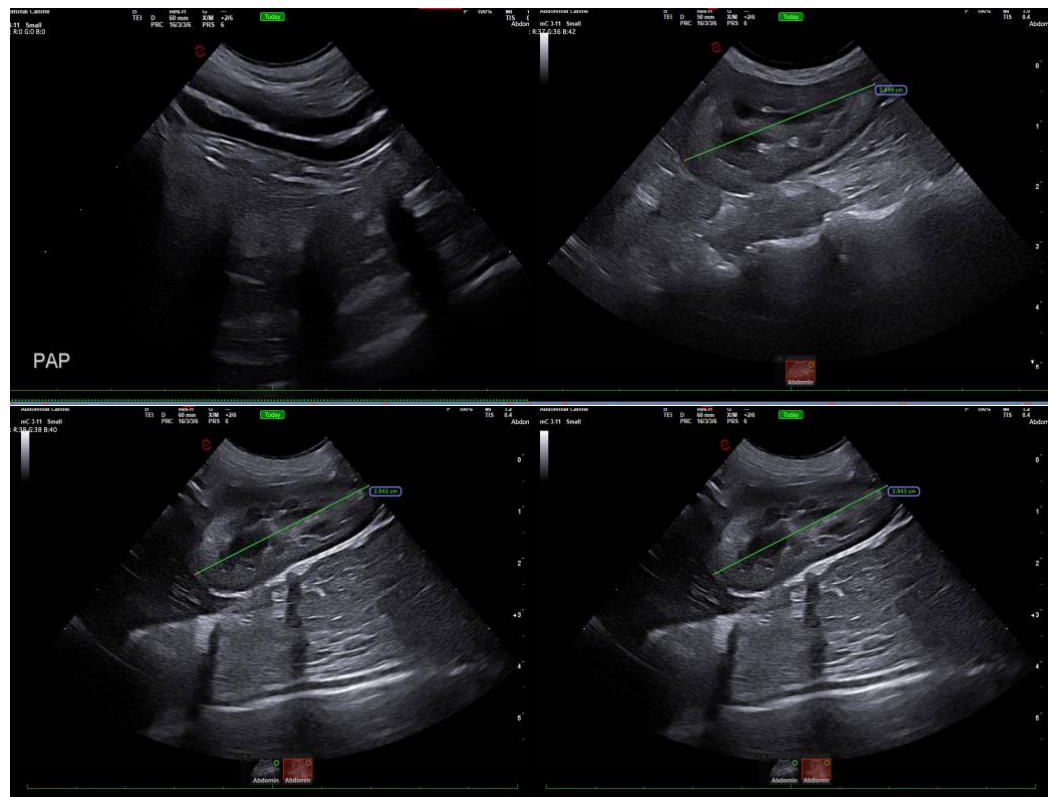
The base and limbs of the **pancreas** were observed to be largely isoechoic to surrounding omental fat. Pancreatic duct and capsular contour were acceptably normal and parenchyma respected normal curvilinear patterns. No overt evidence of active inflammatory or neoplastic disease was noted.

ULTRASONOGRAPHIC FINDINGS

- Gastric ileus.
- Unremarkable abdomen otherwise.

INTERPRETATION OF THE FINDINGS & FURTHER RECOMMENDATIONS

A foreign body is not suspected. GI protectant protocol is indicated.





PATIENT

Tobi Taylor

SPECIES

Canine

BREED

Bichon Frise

SEX

Male

AGE

3

WEIGHT

5.5 kg

INTERPRETED BY

Eric Lindquist, DMV,
DABVP(CFM), Cert.
IVUSS

IMAGING PERFORMED BY

Shervin Akbarian

HOSPITAL NAME

Eagleson Veterinary
Clinic

REFERRING VET

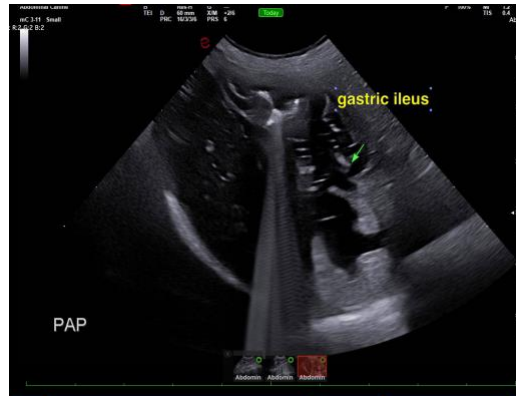
Dr. Mohamed Zaid

INVOICE

15574

DATE

04/29/26



The information and recommendations provided are based on the images presented by the referring veterinarian/sonographer. No evaluation can be communicated regarding pathology that was not visible in the image/video clips provided.

Thank you for this referral. If the clinical or image interpretation does not parallel your findings or if I can be of any further assistance, please contact me.

Eric Lindquist, DMV, DABVP(CFM), Cert. IVUSS,

CEO, Owner, Founder -- SonoPath.com

info@SonoPath.com