



PATIENT

Keegan Rose

SPECIES

Feline

BREED

DSH

SEX

Male

AGE

12 Years

WEIGHT

6.2 kg

INTERPRETED BY

Eric Lindquist, DMV,
DABVP(CFM), Cert.
IVUSS

IMAGING PERFORMED BY

Dr. Laura De Cordon

HOSPITAL NAME

Lakeview Animal
Hospital

REFERRING VET

Dr. Laura De Cordon

INVOICE

15560

DATE

04/29/26

PRESENTING CLINICAL SIGNS

P presented from chronic vomiting. E/D normal. BW - WNL

ULTRASONOGRAPHIC EXAMINATION OF THE ABDOMEN

Urinary System

The **urinary bladder**, trigone, and pelvic urethra to a depth of 1.0 cm presented normal thicknesses and normal tone. The ureters were not visible which is normal. No uroliths or sediment were visualized, and anechoic urine was present. No evidence of inflammatory or neoplastic changes were noted. Ureteral papillae were normal.

The **kidneys** revealed largely normal size and structure, corticomedullary definition and ratio (cortex 1/3 of medulla) were essentially maintained with some moderate age-related loss of curvilinear patterns regarding the capsule and C/M junction. The cortices presented largely uniform texture with some increased echogenicity expected for his age patient. Medullary structure differed distinctly from that of the cortex and no evidence of pelvic dilation was present. The left kidney measured 3.7 cm in length. The right kidney measured 3.9 cm in length.

Adrenal Glands

The regions of the **adrenal glands** were imaged with no evident pathology.

Spleen

The **spleen** presented a smooth homogeneous parenchyma hyperechoic to liver and renal cortical parenchyma. The capsule was smooth without noticeable expansion or deviation from within the spleen or adjacent pathology. The splenic vasculature demonstrated normal volume without signs of congestion or thrombosis. No sonographic evidence of acute or chronic inflammatory, neoplastic, or infarctual changes were noted.

Liver

The **liver** images submitted revealed subjectively normal liver size, contour, and structure. Parenchymal echogenicity was naturally coarse and hypoechoic to the spleen. Vascular and biliary tracts were of normal volume with no evidence of congestion. The gallbladder presented acceptably thin walls with primarily anechoic content. The cystic and common bile ducts were normal. No pathological hepatic lymphadenopathy was evident. No overt structural evidence of inflammatory, infiltrative or regenerative pathology was evident.

Gastrointestinal

The stomach revealed a minor amount of fundic fluid yet structurally unremarkable. NO evidence of foreign bodies with curvilinear patterns maintained. The small intestines and colon were unremarkable with normal curvilinear mural patterns and content.

Pancreas

The base and limbs of the **pancreas** were observed to be largely isoechoic to surrounding omental fat. Pancreatic duct and capsular contour were acceptably normal and parenchyma respected normal curvilinear patterns. No overt evidence of active inflammatory or neoplastic disease was noted.



PATIENT

Keegan Rose

SPECIES

Feline

BREED

DSH

SEX

Male

AGE

12 Years

WEIGHT

6.2 kg

INTERPRETED BY

Eric Lindquist, DMV,
DABVP(CFM), Cert.
IUUSS

IMAGING PERFORMED BY

Dr. Laura De Cordon

HOSPITAL NAME

Lakeview Animal
Hospital

REFERRING VET

Dr. Laura De Cordon

INVOICE

15560

DATE

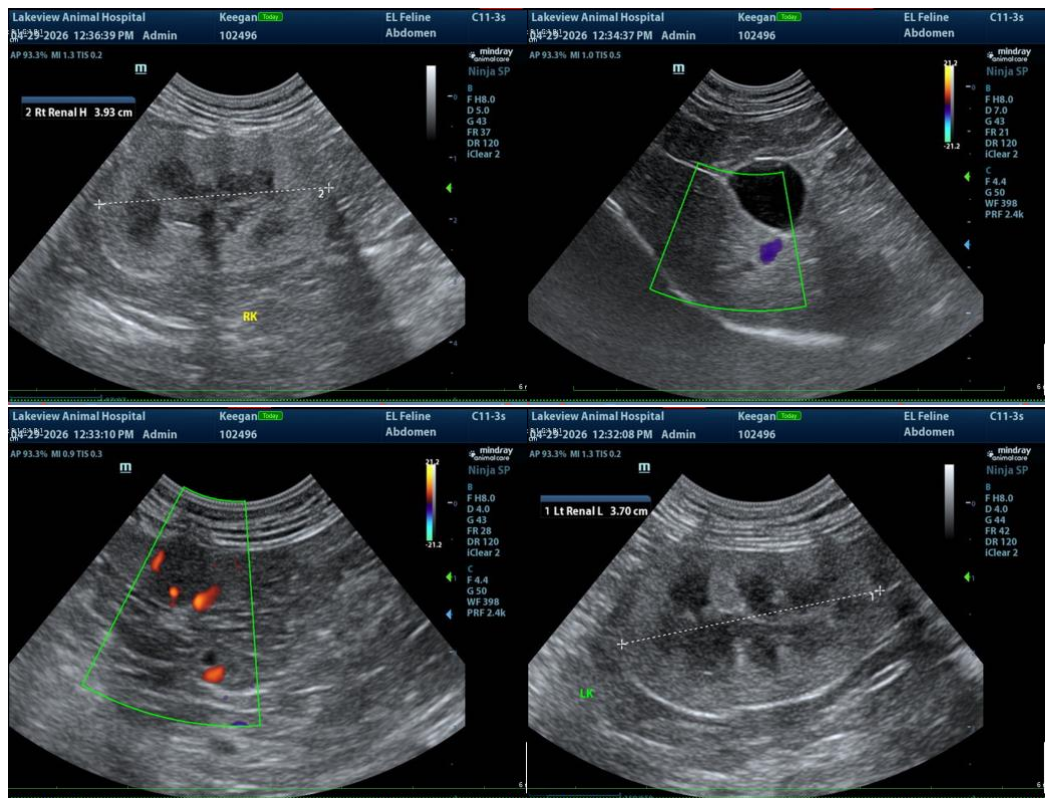
04/29/26

ULTRASONOGRAPHIC FINDINGS

- Structurally unremarkable abdomen with mild gastritis pattern.

INTERPRETATION OF THE FINDINGS & FURTHER RECOMMENDATIONS

Supportive care should prove effective. Dietary intolerance, occult parasitism, structurally insignificant inflammatory bowel are all potentials.





PATIENT

Keegan Rose

SPECIES

Feline

BREED

DSH

SEX

Male

AGE

12 Years

WEIGHT

6.2 kg

INTERPRETED BY

Eric Lindquist, DMV,
DABVP(CFM), Cert.
IVUSS

IMAGING PERFORMED BY

Dr. Laura De Cordon

HOSPITAL NAME

Lakeview Animal
Hospital

REFERRING VET

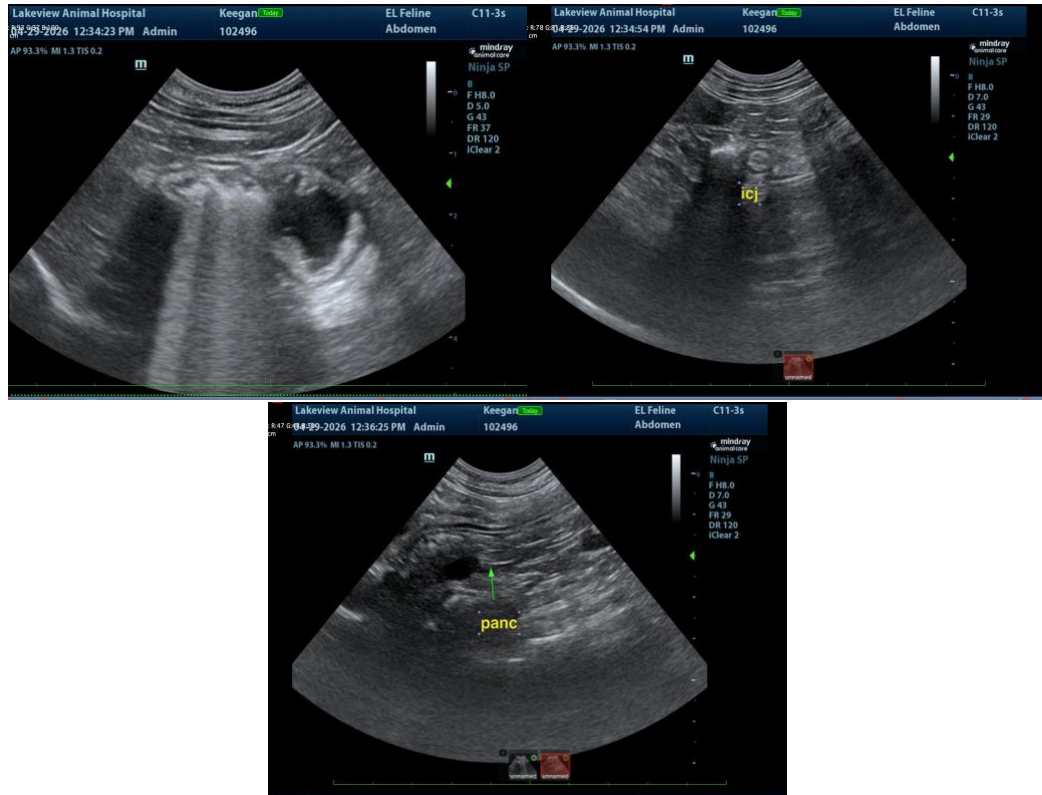
Dr. Laura De Cordon

INVOICE

15560

DATE

04/29/26



The information and recommendations provided are based on the images presented by the referring veterinarian/sonographer. No evaluation can be communicated regarding pathology that was not visible in the image/video clips provided.

Thank you for this referral. If the clinical or image interpretation does not parallel your findings or if I can be of any further assistance, please contact me.

Eric Lindquist, DMV, DABVP(CFM), Cert. IVUSS,

CEO, Owner, Founder -- SonoPath.com

info@SonoPath.com