



## PATIENT

Jasper Simonson

## SPECIES

Feline

## BREED

DLH

## SEX

Spayed Female

## AGE

4 Years 8 Month

## WEIGHT

5.3 pounds

## INTERPRETED BY

Eric Lindquist, DMV,  
DABVP(CFM), Cert.  
IVUSS

## IMAGING PERFORMED BY

Dr. Jessie Evoniuk

## HOSPITAL NAME

State Avenue Vet  
Clinic

## REFERRING VET

Dr. Jessie Evoniuk

## INVOICE

15555

## DATE

04/29/26

## PRESENTING CLINICAL SIGNS

Presents for abdominal ultrasound following mild vomiting after chewing on plastic bag, had a history of chewing plastic 24 hr fasted Meds: Pred TD Chronic intermittent inappetence for 3-4 months Owner adds water to wet food; patient rarely observed drinking from water source TLI, PLI, Cobalamin and Folate- WNL

Abnormal PE/Chem/CBC/UA Results: 4/17/26- ALT 151, Amylase 1180, Glucose 215

## ULTRASONOGRAPHIC EXAMINATION OF THE ABDOMEN

### Urinary System

The **urinary bladder**, trigone, and pelvic urethra to a depth of 2.0 cm presented normal thicknesses and normal tone. The ureters were not visible which is normal. No uroliths or sediment were visualized, and anechoic urine was present. No evidence of inflammatory or neoplastic changes were noted. Ureteral papillae were normal.

The **kidneys** revealed normal size and structure, corticomedullary definition and ratio for this age. The cortices presented largely uniform texture with normal echogenic relationship to liver and spleen. Medullary structure differed distinctly from the cortex and no evidence of pelvic dilation was present. The capsules were acceptably uniform without significant irregularities. The left kidney measured 3.0 cm in length. The right kidney measured 3.4 cm in length.

### Adrenal Glands

Both **adrenal glands** were visualized and recognized as having normal shape, size, position and echogenicity for this breed. The phrenic vasculature, glandular echogenicity and detail were unremarkable. Capsule, cortex, and medullary definition were normal for this age patient. The left adrenal gland measured 0.40 cm width. The right adrenal gland measured 0.40 cm width.

### Spleen

The **spleen** presented a smooth homogeneous parenchyma hyperechoic to liver and renal cortical parenchyma. The capsule was smooth without noticeable expansion or deviation from within the spleen or adjacent pathology. The splenic vasculature demonstrated normal volume without signs of congestion or thrombosis. No sonographic evidence of acute or chronic inflammatory, neoplastic, or infarctual changes were noted.

### Liver

The **liver** images submitted revealed subjectively normal liver size, contour, and structure. Parenchymal echogenicity was naturally coarse and hypoechoic to the spleen. Vascular and biliary tracts were of normal volume with no evidence of congestion. No pathological hepatic lymphadenopathy was evident. No overt structural evidence of inflammatory, infiltrative or regenerative pathology was evident.

The gallbladder was bi-lobed yet not pathological.

### Gastrointestinal

Examination of the **gastrointestinal tract** revealed a stomach and intestine free of stasis, of normal wall thickness, acceptable curvilinear mural detail, and peristaltic activity. Small and large intestine



**PATIENT**

Jasper Simonson

**SPECIES**

Feline

**BREED**

DLH

**SEX**

Spayed Female

**AGE**

4 Years 8 Month

**WEIGHT**

5.3 pounds

**INTERPRETED BY**

Eric Lindquist, DMV,  
DABVP(CFM), Cert.  
IVUSS

**IMAGING PERFORMED BY**

Dr. Jessie Evoniuk

**HOSPITAL NAME**

State Avenue Vet  
Clinic

**REFERRING VET**

Dr. Jessie Evoniuk

**INVOICE**

15555

**DATE**

04/29/26

demonstrated normal luminal chyme and stool consistency respectively. No obstructive or overt infiltrative disease was noted. No associated abnormal lymphatic activity was noted.

**Pancreas**

The base and limbs of the **pancreas** were observed to be largely isoechoic to surrounding omental fat. Pancreatic duct and capsular contour were acceptably normal and parenchyma respected normal curvilinear patterns. No overt evidence of active inflammatory or neoplastic disease was noted.

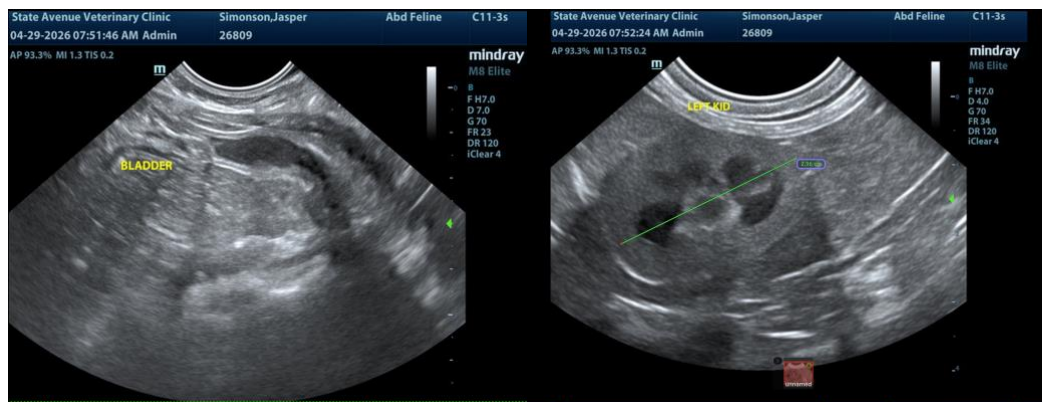
**ULTRASONOGRAPHIC FINDINGS**

- Structurally unremarkable abdomen.
- Bi-lobed gallbladder.

**INTERPRETATION OF THE FINDINGS & FURTHER RECOMMENDATIONS**

No evidence of significant visceral disease. No evidence of foreign bodies. The liver enzyme elevation is likely a reactive hepatopathy. Dietary indiscretion, food intolerance, structurally insignificant inflammatory bowel or occult parasitism are all potentials.

The hepatic clinical sonographic presentation is most consistent with Reactive Hepatopathy which is the most common cause of liver enzyme elevation in dogs and cats. The presumption is that gut and other organ antigen stimuli may be causing a low-grade immune response through portal system with which the liver is reacting to causing low-grade enzyme elevations. US-guided FNA could be performed to assess if low grade lymphoplasmacytic inflammation is present that would support this theory. If FNA is performed, please ask the cytologist to emphasize the primary inflammatory cell type. Empirical treatment measures to address this issue can include diet change to hydrolyzed diet, probiotics, deworming, nutraceuticals (SAME, Actigall...), dental exam and cleaning, and potentially antibiotics such as Clavamox. Metronidazole and Tylosin have traditionally been utilized for this purpose but new studies show that both these antibiotics can disrupt the normal intestinal bacterial flora (intestinal dysbiosis) for weeks and up to 4-6 months. Therefore, Metronidazole and Tylosin should be utilized as a last resort if other efforts have not been effective and sonographic organ appearance remains benign.





## PATIENT

Jasper Simonson

## SPECIES

Feline

## BREED

DLH

## SEX

Spayed Female

## AGE

4 Years 8 Month

## WEIGHT

5.3 pounds

## INTERPRETED BY

Eric Lindquist, DMV,  
DABVP(CFM), Cert.  
IVUSS

## IMAGING PERFORMED BY

Dr. Jessie Evoniuk

## HOSPITAL NAME

State Avenue Vet  
Clinic

## REFERRING VET

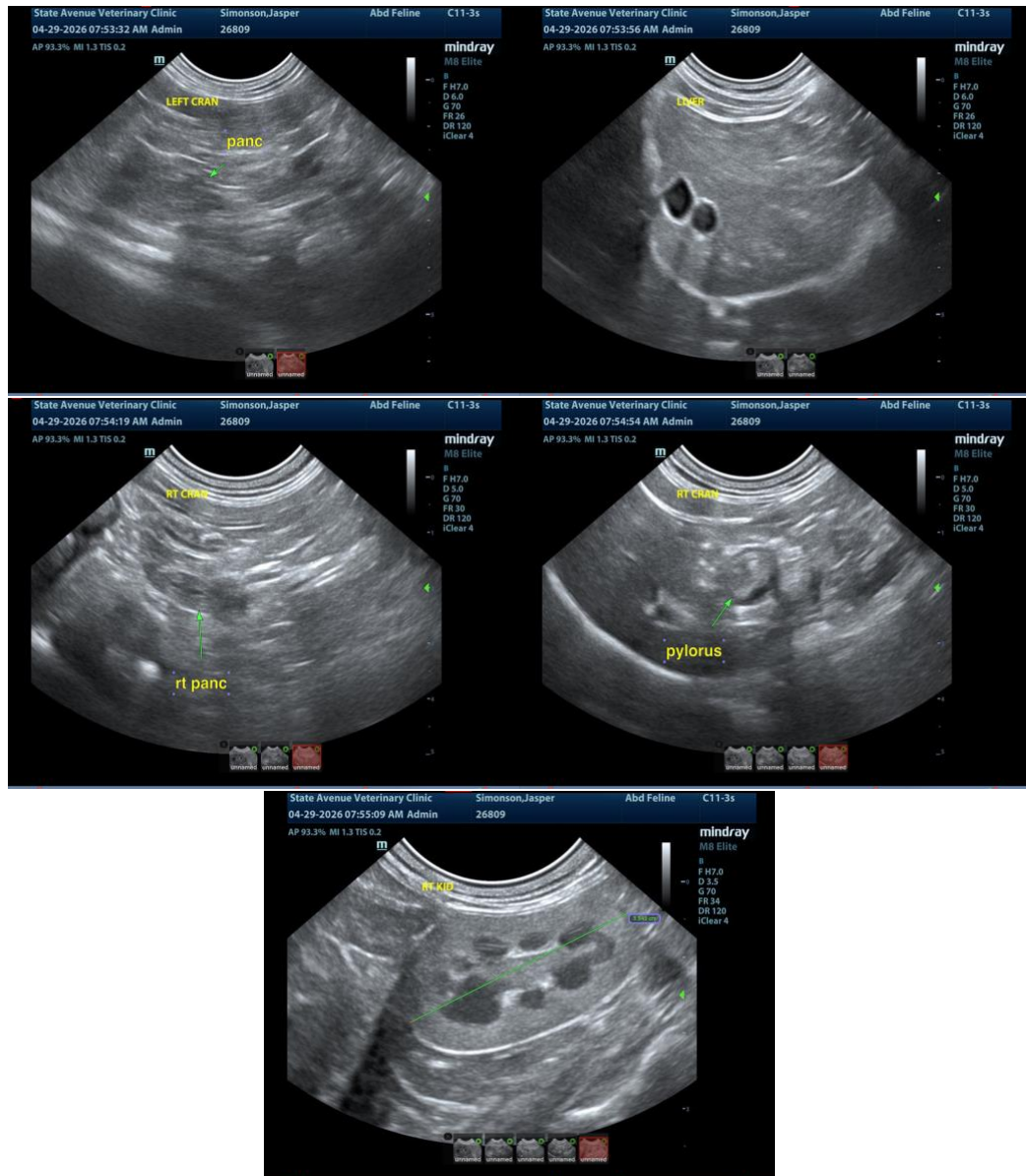
Dr. Jessie Evoniuk

## INVOICE

15555

## DATE

04/29/26



The information and recommendations provided are based on the images presented by the referring veterinarian/sonographer. No evaluation can be communicated regarding pathology that was not visible in the image/video clips provided.

Thank you for this referral. If the clinical or image interpretation does not parallel your findings or if I can be of any further assistance, please contact me.

Eric Lindquist, DMV, DABVP(CFM), Cert. IVUSS,

CEO, Owner, Founder -- SonoPath.com

[info@SonoPath.com](mailto:info@SonoPath.com)



## PATIENT

Jasper Simonson

## SPECIES

Feline

## BREED

DLH

## SEX

Spayed Female

## AGE

4 Years 8 Month

## WEIGHT

5.3 pounds

## INTERPRETED BY

Eric Lindquist, DMV,  
DABVP(CFM), Cert.  
IVUSS

## IMAGING PERFORMED BY

Dr. Jessie Evoniuk

## HOSPITAL NAME

State Avenue Vet  
Clinic

## REFERRING VET

Dr. Jessie Evoniuk

## INVOICE

15555

## DATE

04/29/26