



PATIENT

Ginger Cuthbertson

SPECIES

Feline

BREED

DSH

SEX

Spayed Female

AGE

13 Years

WEIGHT

10 pounds

INTERPRETED BY

Eric Lindquist, DMV,
DABVP(CFM), Cert.
IVUSS

IMAGING PERFORMED BY

Dr. Michael Schacher

HOSPITAL NAME

Emergency
Veterinarians of Idaho
LLC

REFERRING VET

Vineyard Vet

INVOICE

15578

DATE

04/29/26

PRESENTING CLINICAL SIGNS

Referred for ultrasound due to concerns of peritoneal effusion

ULTRASONOGRAPHIC EXAMINATION OF THE ABDOMEN

Urinary System

The **urinary bladder** and visible pelvic urethra to a depth of 2.0 cm were unremarkable for the level of repletion presented. The urine, however, did present some mildly echogenic debris consistent with mucous, exfoliated cells from renal or bladder origin, and/or blood clots as these echogenic changes can all present similarly. This is often related to urinary tract infection but may represent simple evidence of exfoliated debris or sterile inflammation. Cystocentesis, urinalysis, +/- culture would be recommended to rule out and define any UTI.

The **kidneys** revealed largely normal size and structure, corticomedullary definition and ratio (cortex 1/3 of medulla) were essentially maintained with some mild age-related loss of curvilinear patterns regarding the capsule and C/M junction. The cortices presented largely uniform texture with some increased echogenicity expected for his age patient. Medullary structure differed distinctly from that of the cortex and no evidence of pelvic dilation was present. The left kidney measured 3.6 cm in length. The right kidney measured 3.6 cm in length.

Adrenal Glands

Both **adrenal glands** were not visualized.

Spleen

The **spleen** presented enlarged, hypoechoic and irregular measuring up to 1.5 cm.

Liver

The **liver** presented swollen with irregular contour. Incidental gallbladder calculi were present with a grouping measuring 1.6 cm yet not clinically an issue at this time. The hepatic lymph nodes were enlarged, hypoechoic and irregular.

Gastrointestinal

Examination of the **gastrointestinal tract** revealed a stomach and intestine free of stasis, of normal wall thickness, acceptable curvilinear mural detail, and peristaltic activity. Small and large intestine demonstrated normal luminal chyme and stool consistency respectively. No obstructive or overt infiltrative disease was noted. No associated abnormal lymphatic activity was noted.

Pancreas

The **pancreas** presented hypoechoic, irregular and nodular measuring up to 1.5 cm in the left limb.

Free Abdomen

The mesenteric **lymph nodes** were enlarged, hypoechoic and irregular. Slight effusion was present.

ULTRASONOGRAPHIC FINDINGS

- Infiltrative splenohepatic pattern with pancreatic involvement.



PATIENT

Ginger Cuthbertson

- Incidental gallbladder calculi.
- Slight effusion.
- Age-related abdominal changes otherwise.

SPECIES

Feline

INTERPRETATION OF THE FINDINGS & FURTHER RECOMMENDATIONS

25-gauge FNA of the spleen, liver and pancreas should prove effective. Multicentric round cell neoplasia is suspected.

BREED

DSH

SEX

Spayed Female

AGE

13 Years

WEIGHT

10 pounds

INTERPRETED BY

Eric Lindquist, DMV,
DABVP(CFM), Cert.
IVUSS

IMAGING PERFORMED BY

Dr. Michael Schacher

HOSPITAL NAME

Emergency Veterinarians of Idaho LLC

REFERRING VET

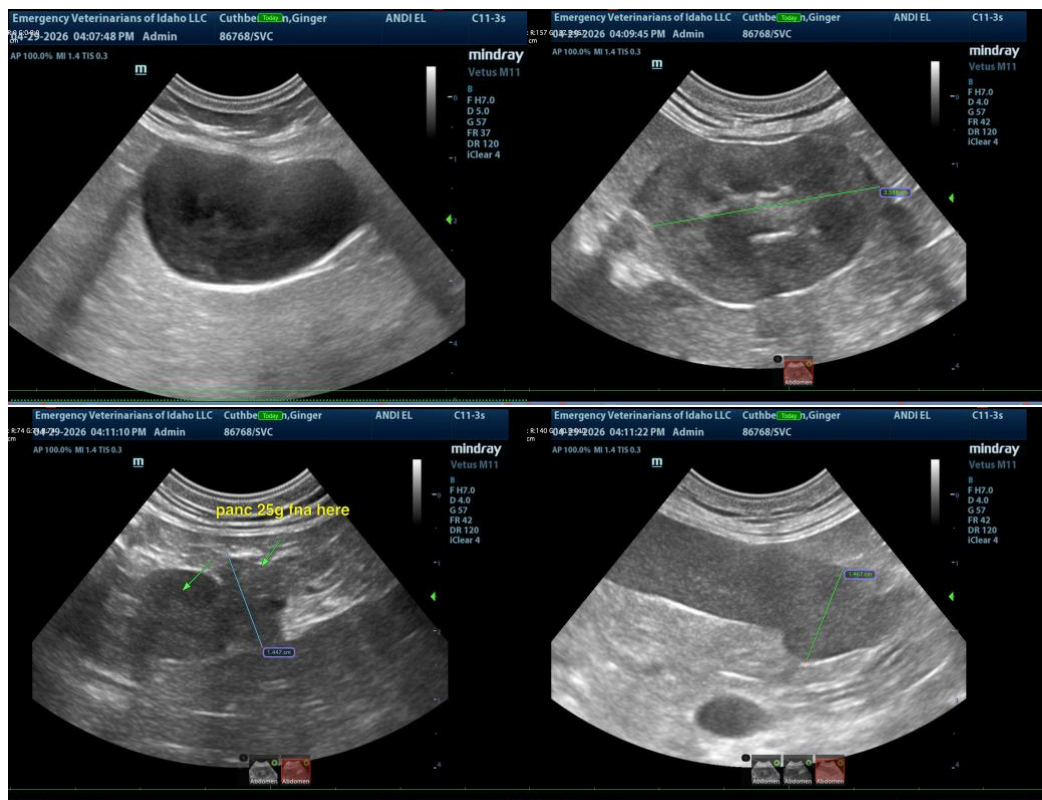
Vineyard Vet

INVOICE

15578

DATE

04/29/26





PATIENT

Ginger Cuthbertson

SPECIES

Feline

BREED

DSH

SEX

Spayed Female

AGE

13 Years

WEIGHT

10 pounds

INTERPRETED BY

Eric Lindquist, DMV,
DABVP(CFM), Cert.
IVUSS

IMAGING PERFORMED BY

Dr. Michael Schacher

HOSPITAL NAME

Emergency
Veterinarians of Idaho
LLC

REFERRING VET

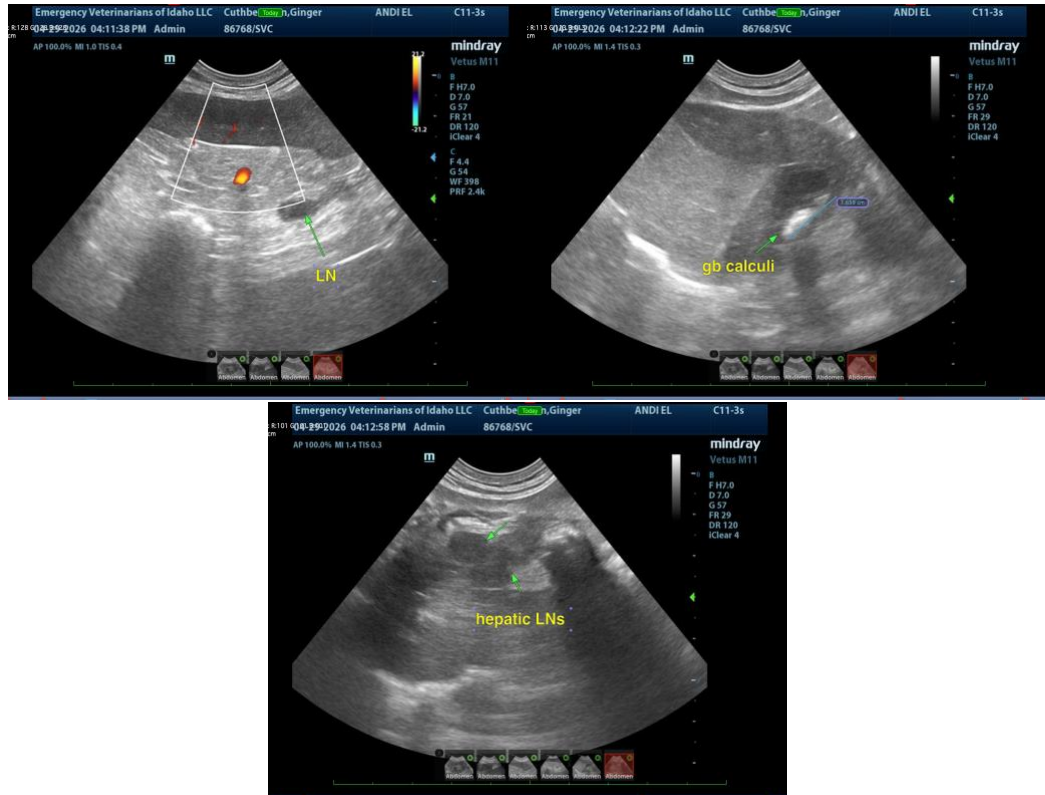
Vineyard Vet

INVOICE

15578

DATE

04/29/26



The information and recommendations provided are based on the images presented by the referring veterinarian/sonographer. No evaluation can be communicated regarding pathology that was not visible in the image/video clips provided.

Thank you for this referral. If the clinical or image interpretation does not parallel your findings or if I can be of any further assistance, please contact me.

Eric Lindquist, DMV, DABVP(CFM), Cert. IVUSS,

CEO, Owner, Founder -- SonoPath.com

info@SonoPath.com