



PATIENT

Dani Lambert

SPECIES

Canine

BREED

Australian Shepherd

SEX

Spayed Female

AGE

8

WEIGHT

51.6

INTERPRETED BY

Eric Lindquist, DMV,
DABVP (CFM), Cert.
IVUS

IMAGING PERFORMED BY

Dr. Susan Lincoski

HOSPITAL NAME

University Drive
Veterinary Hospital

REFERRING VET

Dr. Susan Lincoski

INVOICE

74816

DATE

4/29/26

PRESENTING CLINICAL SIGNS

Acute onset lethargy, discomfort in abdomen. Abdomen was dense/tense on palpation. Normal appetite and eliminations.

Abnormal PE/Chem/CBC/UA Results: Abdomen is tense, otherwise WNL. CBC: slightly low WBCs (4.9) CHEM: mildly elevated albumin (4.2), ALT (126), T bilirubin (1.7). Synergy xray results: Normal abdomen.

ULTRASONOGRAPHIC EXAMINATION OF THE ABDOMEN

Urinary System

The **urinary bladder**, trigone, and pelvic urethra presented normal thicknesses and normal tone. The ureters were not visible which is normal. No uroliths or sediment were visualized and anechoic urine was present. No evidence of inflammatory or neoplastic changes were noted. Ureteral papillae were normal. The pelvic urethra was imaged 2.0 cm beyond the cystourethral junction.

The **kidneys** revealed normal size and structure, corticomedullary definition and ratio for this age. The cortices presented largely uniform texture with normal echogenic relationship to liver and spleen. Medullary structure differed distinctly from the cortex and no evidence of pelvic dilation was present. The capsules were acceptably uniform without significant irregularities. Right kidney measured 4.64 cm. Left kidney measured 5.5 cm.

Adrenal Glands

Both **adrenal glands** were visualized and recognized as having normal shape, size, position and echogenicity for this breed. The phrenic vasculature, glandular echogenicity and detail were unremarkable. Capsule, cortex, and medullary definition were normal for this age patient. Left measured 2.3 cm x 0.61 cm. Right measured 0.46 cm x 2.0 cm.

Spleen

The **spleen** was largely smooth with subtle heterogeneous parenchymal changes while maintaining normal echogenic relationship to the liver and kidney. These changes are consistent with normal age-related alteration. The capsule was smooth without noticeable impingement from within the spleen or from pathology in the adjacent abdomen. The splenic vasculature demonstrated normal volume without signs of congestion or significant contraction. No evidence of active acute or chronic inflammatory, neoplastic, or infarctual changes were noted.

Liver

The **liver** images from right and left intercostal as well as subcostal views revealed subjectively normal liver size, contour, and structure. Some age-related parenchymal remodeling was noted but likely not clinically significant at this time. Vascular and biliary tracts were of normal volume and no evidence of congestion was noted. The gallbladder presented some dependent debris with essentially normal contour. The cystic and common bile ducts were normal. No overt evidence of active inflammatory, infiltrative or regenerative pathology was noted but should be paired with current or past LE elevations regarding any clinical significance to this presentation. The hepatic lymph nodes were unremarkable.



PATIENT

Dani Lambert

SPECIES

Canine

BREED

Australian Shepherd

SEX

Spayed Female

AGE

8

WEIGHT

51.6

INTERPRETED BY

Eric Lindquist, DMV,
DABVP (CFM), Cert.
IVUSS

IMAGING PERFORMED BY

Dr. Susan Lincoski

HOSPITAL NAME

University Drive
Veterinary Hospital

REFERRING VET

Dr. Susan Lincoski

INVOICE

74816

DATE

4/29/26

Gastrointestinal

Examination of the **gastrointestinal tract** revealed a stomach and intestine free of stasis, of normal wall thickness, acceptable curvilinear mural detail, and peristaltic activity. Small and large intestine demonstrated normal luminal chyme and stool consistency respectively. No obstructive or overt infiltrative disease was noted. No associated abnormal lymphatic activity was noted.

Pancreas

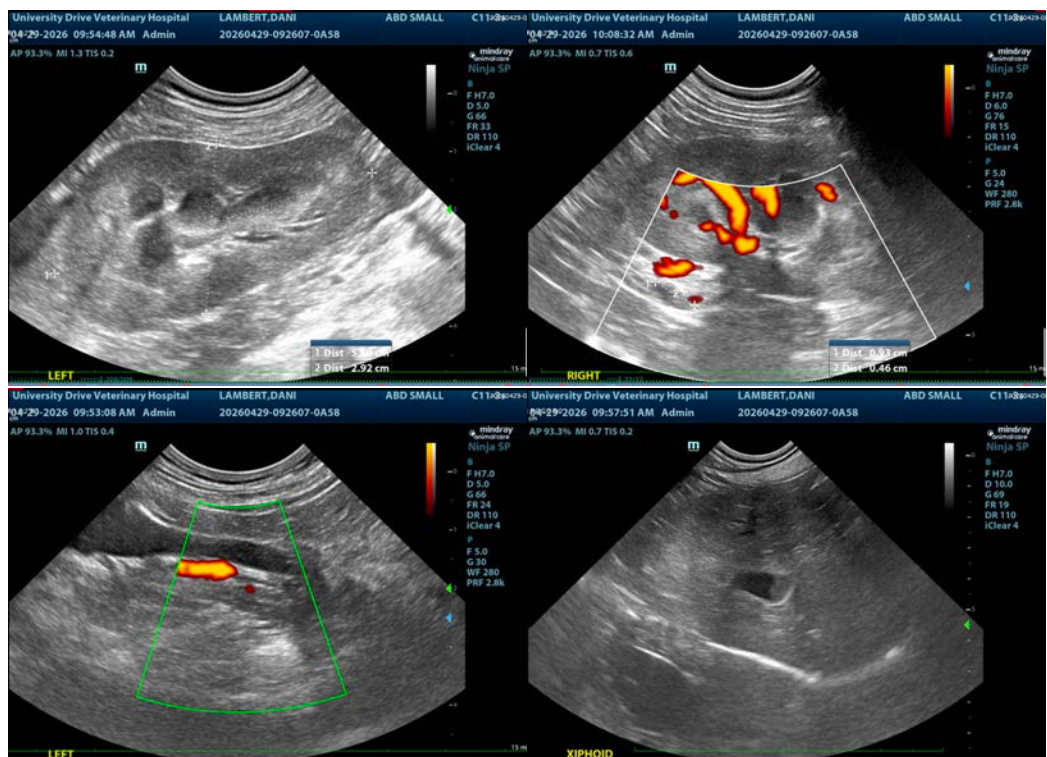
The base and limbs of the **pancreas** were observed to be largely isoechoic to surrounding omental fat. Pancreatic duct and capsular contour were acceptably normal and parenchyma respected normal curvilinear patterns. No overt evidence of active inflammatory or neoplastic disease was noted.

ULTRASONOGRAPHIC FINDINGS

- Age related hepatic changes, unremarkable abdomen otherwise.

INTERPRETATION OF THE FINDINGS & FURTHER RECOMMENDATIONS

Structurally unremarkable abdomen. Recommend reevaluating the bilirubin elevation, as it would not fit with the visceral presentation. Referred back pain is a strong potential in this patient, as there is no evidence of visceral disease to be responsible for the abdominal tension.





PATIENT

Dani Lambert

SPECIES

Canine

BREED

Australian Shepherd

SEX

Spayed Female

AGE

8

WEIGHT

51.6

INTERPRETED BY

Eric Lindquist, DMV,
DABVP (CFM), Cert.
IVUSS

IMAGING PERFORMED BY

Dr. Susan Lincoski

HOSPITAL NAME

University Drive
Veterinary Hospital

REFERRING VET

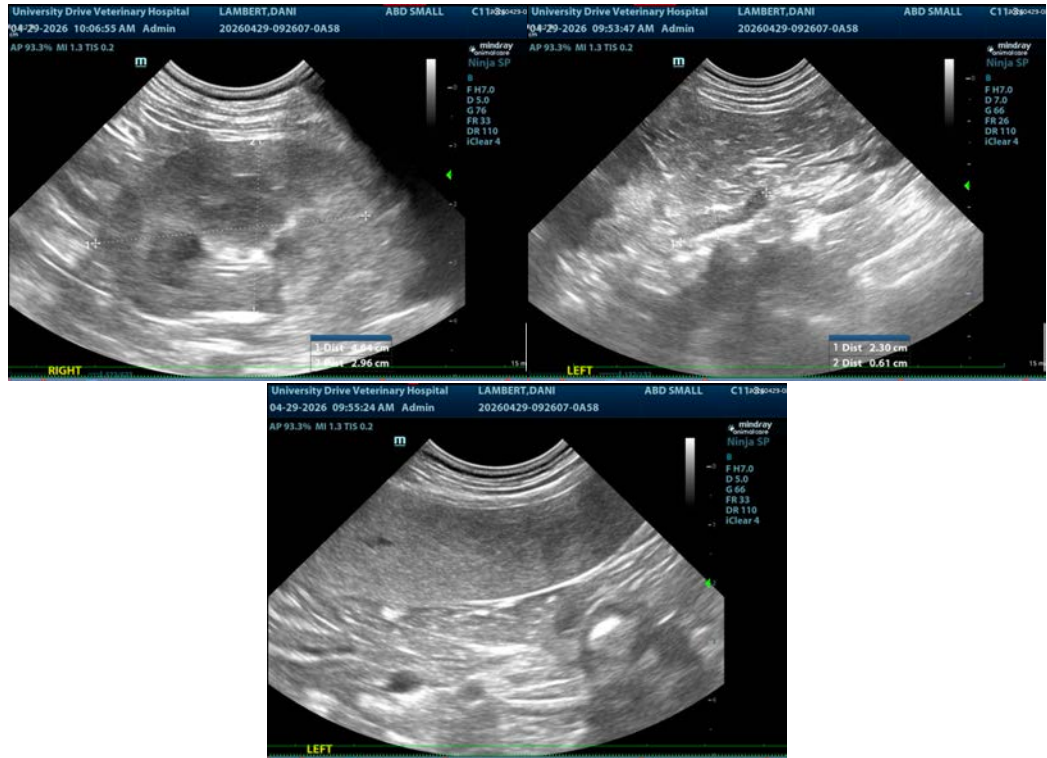
Dr. Susan Lincoski

INVOICE

74816

DATE

4/29/26



The information and recommendations provided are based on the images presented by the referring veterinarian/sonographer. No evaluation can be communicated regarding pathology that was not visible in the image/video clips provided.

Thank you for this referral. If the clinical or image interpretation does not parallel your findings or if I can be of any further assistance please contact me.

Eric Lindquist, DMV, DABVP(CFM), Cert. IVUSS,
CEO, Owner, Founder -- SonoPath.com
info@SonoPath.com