



**PATIENT**

Bruno Mohammed

**SPECIES**

Canine

**BREED**

Shih Tzu

**SEX**

Neutered Male

**AGE**

8 Years 6 Months

**WEIGHT**

21.4 lbs

**INTERPRETED BY**

Eric Lindquist, DMV,  
 DABVP (CFM), Cert.  
 IVUSS

**IMAGING PERFORMED BY**

Chloe Lowe, CVT

**HOSPITAL NAME**

Heart and Paw

**REFERRING VET**

Dr. Verhalen

**INVOICE**

74814

**DATE**

4/29/26

**PRESENTING CLINICAL SIGNS**

Elevated ALK PHOS and calcium. Last year's blood work was normal. No clinical signs. Abnormal PE/Chem/CBC/UA Results: Calcium 12.8, Alk Phos 483, Globulin 3.7

**ULTRASONOGRAPHIC EXAMINATION OF THE ABDOMEN**

**Urinary System**

The **bladder** in this patient was mildly thickened with slight echogenic mural changes. Minimal amount of urine present at the time of the sonogram. No calculi or masses were noted. Slight micropolypoid changes were noted. This is a frequent finding in older animals and may be linked to a history of chronic urinary tract infection or active urinary tract infection. Urinalysis would be recommended with culture if any evidence of inflammatory sediment is present. The region of the trigone and visible pelvic urethra were normal. The pelvic urethra was imaged 2.0 cm beyond the cystourethral junction.

The **kidneys** revealed largely normal size and structure, corticomedullary definition and ratio (cortex 1/3 of medulla) were essentially maintained with some age-related loss of curvilinear patterns regarding the capsule and C/M junction. The cortices presented largely uniform texture with some increased echogenicity expected for his age patient. Medullary structure differed distinctly from that of the cortex and no evidence of pelvic dilation was present. Right kidney measured 4.9 cm. Left kidney measured 4.6 cm.

**Adrenal Glands**

The **left adrenal gland** was visualized and recognized as having normal shape, size, position and echogenicity for this breed. The phrenic vasculature, glandular echogenicity and detail were unremarkable. Capsule, cortex, and medullary definition were normal for this age patient. Left measured 1.81 cm x 0.41 cm at the cranial pole and 0.72 cm at the caudal pole.

The **right adrenal gland** was slightly enlarged, measuring 1.65 cm x 1.51 cm at the cranial pole and 0.48 cm at the caudal pole.

**Spleen**

The **spleen** presented a smooth homogeneous parenchyma hyperechoic to liver and renal cortical parenchyma. The capsule was smooth without noticeable expansion or deviation from within the spleen or adjacent pathology. The splenic vasculature demonstrated normal volume without signs of congestion or thrombosis. No sonographic evidence of acute or chronic inflammatory, neoplastic, or infarctual changes were noted.

**Liver**

The **liver** images submitted revealed subjectively normal liver size, contour, and structure. Parenchymal echogenicity was naturally coarse and hypoechoic to the spleen. Vascular and biliary tracts were of normal volume with no evidence of congestion. The gallbladder presented acceptably thin walls with primarily anechoic content. The cystic and common bile ducts were normal. No pathological hepatic lymphadenopathy was evident. No overt structural evidence of inflammatory, infiltrative or regenerative pathology was evident.



**PATIENT**

Bruno Mohammed

**SPECIES**

Canine

**BREED**

Shih Tzu

**SEX**

Neutered Male

**AGE**

8 Years 6 Months

**WEIGHT**

21.4 lbs

**INTERPRETED BY**

Eric Lindquist, DMV,  
DABVP (CFM), Cert.  
IVUSS

**IMAGING PERFORMED BY**

Chloe Lowe, CVT

**HOSPITAL NAME**

Heart and Paw

**REFERRING VET**

Dr. Verhalen

**INVOICE**

74814

**DATE**

4/29/26

**Gastrointestinal**

Examination of the **gastrointestinal tract** revealed a stomach and intestine free of stasis, of normal wall thickness, acceptable curvilinear mural detail, and peristaltic activity. Small and large intestine demonstrated normal luminal chyme and stool consistency respectively. No obstructive or overt infiltrative disease was noted. No associated abnormal lymphatic activity was noted.

**Pancreas**

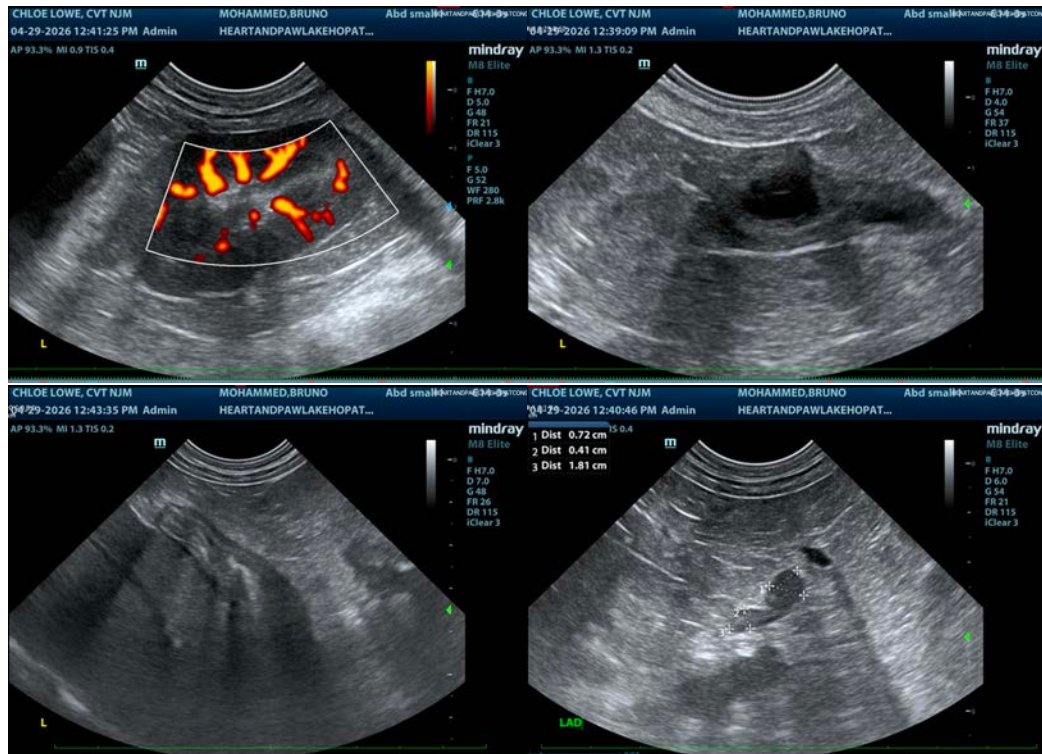
The base and limbs of the **pancreas** were observed to be largely isoechoic to surrounding omental fat. Some parenchymal remodeling, however, with mild deviation from curvilinear normalcy was observed. Pancreatic duct and capsular irregularities were present consistent with age related changes. If pain upon imaging (+ Murphy sign) was present or if the patient is focally painful in subxyphoid palpation then low-grade smoldering chronic pancreatitis should be suspected.

**ULTRASONOGRAPHIC FINDINGS**

- Age related abdominal changes.

**INTERPRETATION OF THE FINDINGS & FURTHER RECOMMENDATIONS**

Expected changes for this age and breed. No evidence of visceral disease. Anal gland palpation +/- ultrasound, spinal radiographs, chest radiographs +/- parathyroid ultrasound all indicated in this patient to assess for the cause of hypercalcemia depending upon results of Michigan State hypercalcemia panel.





**PATIENT**

Bruno Mohammed

**SPECIES**

Canine

**BREED**

Shih Tzu

**SEX**

Neutered Male

**AGE**

8 Years 6 Months

**WEIGHT**

21.4 lbs

**INTERPRETED BY**

Eric Lindquist, DMV,  
DABVP (CFM), Cert. IVUSS

**IMAGING PERFORMED BY**

Chloe Lowe, CVT

**HOSPITAL NAME**

Heart and Paw

**REFERRING VET**

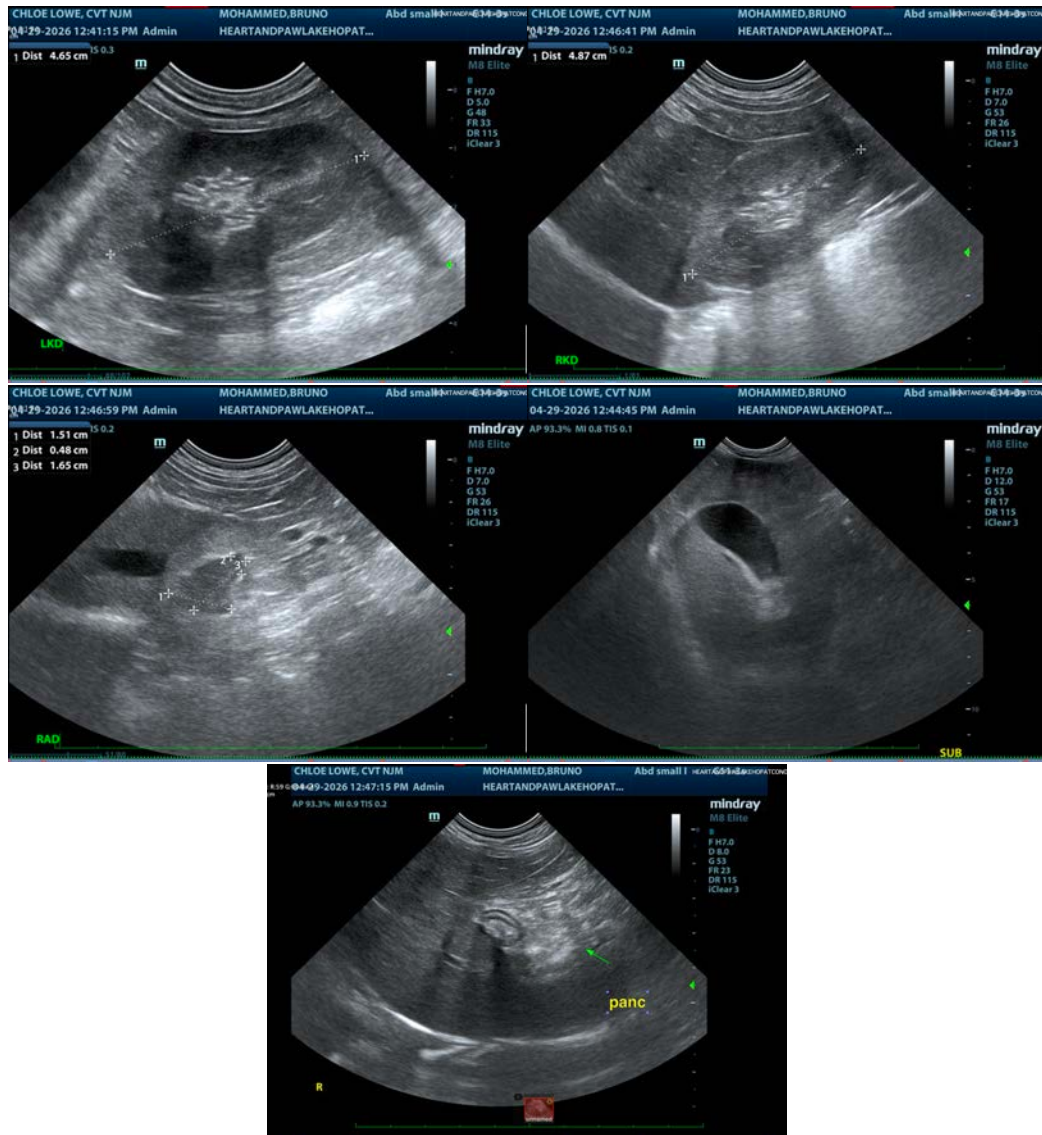
Dr. Verhalen

**INVOICE**

74814

**DATE**

4/29/26



The information and recommendations provided are based on the images presented by the referring veterinarian/sonographer. No evaluation can be communicated regarding pathology that was not visible in the image/video clips provided.

Thank you for this referral. If the clinical or image interpretation does not parallel your findings or if I can be of any further assistance please contact me.

**Eric Lindquist**, DMV, DABVP(CFM), Cert. IVUSS,  
CEO, Owner, Founder -- SonoPath.com  
[info@SonoPath.com](mailto:info@SonoPath.com)



**PATIENT**

Bruno Mohammed

**SPECIES**

Canine

**BREED**

Shih Tzu

**SEX**

Neutered Male

**AGE**

8 Years 6 Months

**WEIGHT**

21.4 lbs

**INTERPRETED BY**

Eric Lindquist, DMV,  
DABVP (CFM), Cert.  
IVUSS

**IMAGING PERFORMED BY**

Chloe Lowe, CVT

**HOSPITAL NAME**

Heart and Paw

**REFERRING VET**


Dr. Verhalen

**INVOICE**

74814

**DATE**

4/29/26



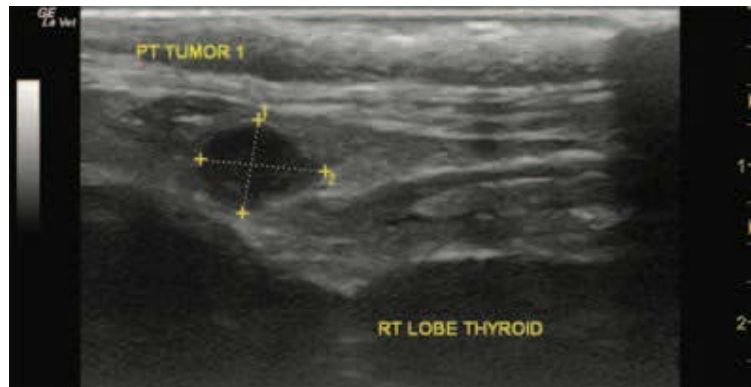The following is an applicable excerpt from the *Curbside Guide to Diagnosis & Treatment of Sonographic Disease* offered by [SonoPath.com](http://SonoPath.com) Lindquist, Frank, Lobetti, and Modler.

An essential quick guide for every general practitioner and sonographer.

<https://sonopath.com/products/curbside-guide-editing-due-release-12012015>

**CANINE HYPERCALCEMIA**

<http://www.sonopath.com/CanineHypercalcemia>



Long axis of the right thyroid lobe in a dog with a parathyroid adenoma. The right internal parathyroid gland (between calipers) shows severe uniform enlargement of more than 7mm.

**Description:** Hypercalcemia is defined as either a persistently elevated total calcium serum (> 12 mg/dl) or ionized calcium (> 1.45 mmol/l) concentration. Clinical signs are often absent with mild hypercalcemia (< 13 mg/dl). In fact, hypercalcemia is often only discovered when serum biochemistry is done for unrelated reasons. Clinical signs are usually mild when the serum calcium concentration is less than 14 mg/dl; however, signs become more readily apparent when the concentration exceeds 15 mg/dl. Life-threatening cardiac arrhythmias can develop when the serum calcium exceeds 18 mg/dl.

Common etiologies of hypercalcemia include humoral hypercalcemia of malignancy (HHM), hypoadrenocorticism, chronic kidney disease (CKD), hypervitaminosis D, and primary hyperparathyroidism. Less common etiologies include bone neoplasia, osteomyelitis, hypertrophic osteodystrophy, granulomatous disease, calcium supplementation, and oral phosphate binders.

**Clinical Signs:** Common clinical signs include polyuria, polydipsia, lethargy, inappetence, and weakness. With chronic hypercalcemia, calcium oxalate and calcium phosphate uroliths can form, resulting in clinical signs suggestive of lower urinary tract disease. Systemic signs of illness are suggestive of HHM.



## PATIENT

Bruno Mohammed

## SPECIES

Canine

## BREED

Shih Tzu

## SEX

Neutered Male

## AGE

8 Years 6 Months

## WEIGHT

21.4 lbs

## INTERPRETED BY

Eric Lindquist, DMV,  
DABVP (CFM), Cert.  
IVUSS

## IMAGING PERFORMED BY

Chloe Lowe, CVT

## HOSPITAL NAME

Heart and Paw

## REFERRING VET

Dr. Verhalen

## INVOICE

74814

## DATE

4/29/26

**Diagnosics:** One important etiology of hypercalcemia is laboratory error; therefore, hypercalcemia should always be confirmed before embarking on any further diagnostic evaluation. Results of a CBC, serum biochemistry panel, and urinalysis, in conjunction with a patient history and findings from a physical examination, can often provide enough information to arrive at a diagnosis. The appendicular skeleton, peripheral lymph nodes, abdominal cavity, and rectum should all be carefully palpated for masses, lymphadenopathy, hepatomegaly, splenomegaly, and/or pain in the long bones. The following diagnostic tests are helpful for identifying an underlying malignancy: thoracic and abdominal radiographs; abdominal ultrasound; cytological evaluation of aspirates of the liver, spleen, lymph nodes, and bone marrow; determination of serum ionized calcium, parathyroid hormone (PTH), and parathyroid hormone-related protein concentration (PTHrP); and ultrasound of the neck. Ascertaining the concentrations of serum ionized calcium, PTH, and PTHrP helps differentiate primary hyperparathyroidism from HHM. The finding of one or more enlarged parathyroid glands upon conducting an ultrasound of the neck supports a diagnosis of primary hyperparathyroidism.

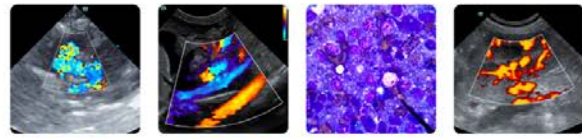
Hypoadrenocorticism-induced hypercalcemia usually occurs in conjunction with hyponatremia, hyperkalemia, and prerenal azotemia. With HHM and primary hyperparathyroidism, serum phosphorus concentration is often in the low to low-normal reference range. If the serum phosphorus concentration is high but kidney function is normal, hypervitaminosis D or osteolysis should be suspected.

It can be difficult to determine whether kidney failure is primary or secondary to hypercalcemia when hyperphosphatemia and hypercalcemia coexist with azotemia. Serum ionized calcium concentrations are typically normal or decreased in cases of renal failure and increased in cases of hypercalcemia caused by other disorders.

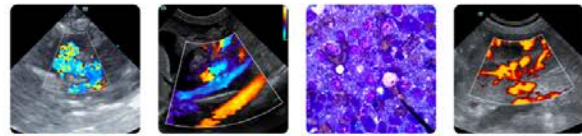
Sternal and hilar lymphadenopathy is common with lymphoma-induced hypercalcemia and can be readily identified on thoracic radiographs. In cases of multiple myeloma, discrete lytic lesions in the vertebrae or long bones, hyperproteinemia, proteinuria, and plasma cell infiltration in the bone marrow may be present. Cytological evaluation of the peripheral lymph nodes, bone marrow, and spleen can be helpful in identifying lymphoma.

Increased serum ionized calcium concentrations, detectable serum PTHrP concentrations, and non-detectable serum PTH concentrations are all diagnostic for HHM. Lymphoma is the most common etiology of HHM, but other tumors, such as apocrine gland adenocarcinoma and various carcinomas (e.g. mammary gland, squamous cell, bronchogenic), can all give rise to hypercalcemia. Increased serum ionized calcium, normal to increased serum PTH, and non-detectable PTHrP concentrations are diagnostic of primary hyperparathyroidism.

**Differentials for Hypercalcemia: "HARD IONS"**



<b>PATIENT</b>	<b>Hyperparathyroid</b>
Bruno Mohammed	<b>Addison's</b>
<b>SPECIES</b>	<b>Renal</b>
Canine	<b>D-toxicity</b>
<b>BREED</b>	<b>Idiopathic</b>
Shih Tzu	<b>Osteolytic</b>
<b>SEX</b>	<b>Neoplastic</b>
Neutered Male	<b>Spurious</b>
<b>AGE</b>	<b>PTH tumor:</b> Elevated total and ionized Ca, low PTHrP, and normal/high PTH. Keeshonds, German Shepherds, and Golden Retrievers are all predisposed.
8 Years 6 Months	<b>Addison's disease:</b> Elevated total and normal ionized Ca, elevated BUN, hypoalbuminemia and hyperkalemia.
<b>WEIGHT</b>	<b>Renal failure:</b> Elevated to normal total Ca, low ionized Ca, low PTHrP, elevated PTH, azotemia, and low urine specific gravity.
21.4 lbs	<b>Vitamin D toxicity:</b> Elevated total and ionized Ca, low PTHrP, and normal/low PTH.
<b>INTERPRETED BY</b>	<b>Hypercalcemia of malignancy (HHM):</b> Elevated total and ionized Ca, high PTHrP, and low PTH.
Eric Lindquist, DMV, DABVP (CFM), Cert. IVUSS	<b>Granulomatous disease:</b> Elevated total and ionized Ca, low PTHrP, and low PTH.
<b>IMAGING PERFORMED BY</b>	<b>Renal failure:</b> Elevated to normal total Ca, low ionized Ca, low PTHrP, elevated PTH, azotemia, and low urine specific gravity.
Chloe Lowe, CVT	<b>Treatment:</b> Therapies for hypercalcemia are aimed at correcting the underlying etiology; however, because prolonged hypercalcemia can result in kidney damage, the use of fluid therapy, furosemide, and possibly prednisone is indicated in all cases to reduce serum calcium levels. Suggested dosages include saline (0.9% 120-180 ml/kg day IV), furosemide (1-4 mg/kg PO TID), and prednisone (0.25 mg/kg PO Q24hr).
<b>HOSPITAL NAME</b>	
Heart and Paw	
<b>REFERRING VET</b>	
Dr. Verhalen	
<b>INVOICE</b>	
74814	
<b>DATE</b>	
4/29/26	



**PATIENT**

Bruno Mohammed

**SPECIES**

Canine

**BREED**

Shih Tzu

**SEX**

Neutered Male

**AGE**

8 Years 6 Months

**WEIGHT**

21.4 lbs

**INTERPRETED BY**

Eric Lindquist, DMV,  
DABVP (CFM), Cert.  
IVUSS

**IMAGING PERFORMED BY**

Chloe Lowe, CVT

**HOSPITAL NAME**

Heart and Paw

**REFERRING VET**

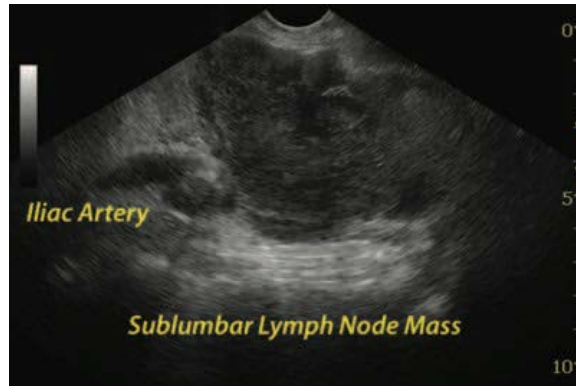
Dr. Verhalen

**INVOICE**

74814

**DATE**

4/29/26



Long axis of the left hypogastric lymph node in a hypercalcemic dog with lymphoma and hypercalcemia of malignancy. The lymph node is severely enlarged and rounded with a short-to-long-axis ratio > 0.5 indicating malignant infiltration. The regular echoarchitecture is lost, the hilus is not recognized, lymph node parenchyma is hypoechoic and heterogeneous. Also note the mass effect on the external iliac artery. In light of hypercalcemia, lymphadenopathy in this region could also be owing to anal gland adenocarcinoma which can also be imaged sonographically.

**References:**

Chew DJ, Schenck PA, Jaeger JQ. Clinical disorders of hypercalcemia and hypocalcemia in dogs and cats. Proceedings from the American College of Veterinary Internal Medicine, Charlotte, NC, June 4-7, 2003.

Feldman EC. Disorders of the parathyroid glands. In: Ettinger SJ, Feldman EC, ed. *Textbook of Veterinary Internal Medicine, 7th ed.* St. Louis, MO: Saunders Elsevier; 2010:1722-50.

Peterson ME. Hypercalcemia in dogs & cats: differential diagnosis & treatment. Proceedings from the Western Veterinary Conference, Las Vegas, NV, February 19-23, 2012.