



PATIENT

Bro Smith

SPECIES

Feline

BREED

Domestic Shorthair

SEX

Neutered male

AGE

9 years

WEIGHT

9.5 lbs

INTERPRETED BY

Eric Lindquist, DMV
DABVP, Cert. IVUSS

IMAGING PERFORMED BY

Jack Reese

HOSPITAL NAME

Willow Run VC

REFERRING VET

Dr. Wasik Arnold

INVOICE

75000

DATE

4/29/26

PRESENTING CLINICAL SIGNS

History: Stable diabetic - currently managed on Bexacat. Decreased appetite yesterday morning and mild lethargy noted today. Still taking bexacat well and is eating today.
Temp: 104.1 GGT 19 Ketones 0.7 Glucose 128 Remainder of testing is unremarkable.

ULTRASONOGRAPHIC EXAMINATION OF THE ABDOMEN

Urinary System

The **urinary bladder**, trigone, and pelvic urethra presented normal thicknesses and normal tone. The ureters were not visible which is normal. No uroliths or sediment were visualized and anechoic urine was present. No evidence of inflammatory or neoplastic changes was noted. Ureteral papillae were normal.

The **kidneys** revealed largely normal structure, corticomedullary definition and ratio (cortex 1/3 of medulla) were essentially maintained with some age-related loss of curvilinear patterns regarding the capsule and C/M junction. The cortices presented largely uniform texture with some increased echogenicity expected for this age patient. Medullary structure differed distinctly from that of the cortex and no evidence of pelvic dilation was present. Both kidneys are slightly swollen, which is typical for a diabetic state. The left kidney measured 4.5 cm. The right kidney measured 4.5 cm.

Adrenal Glands

Both **adrenal glands** were visualized and recognized as having normal shape, size, position and echogenicity for this breed. The phrenic vasculature, glandular echogenicity and detail were unremarkable. Capsule, cortex, and medullary definition were normal for this age patient. The right adrenal gland measured 0.44 cm.

Spleen

The **spleen** revealed subtle micronodular changes, yet there was no evidence of significant pathology.

Liver

The **liver** images from right and left intercostal as well as subcostal views revealed subjectively normal liver size, contour, and structure. Some age-related parenchymal remodeling was noted but likely not clinically significant at this time. Vascular and biliary tracts were of normal volume and no evidence of congestion was noted. The gallbladder presented some dependent debris with essentially normal contour. The cystic and common bile ducts were normal. No overt evidence of active inflammatory, infiltrative or regenerative pathology was noted but should be paired with current or past LE elevations regarding any clinical significance to this presentation. The hepatic lymph nodes were unremarkable.



PATIENT

Bro Smith

SPECIES

Feline

BREED

Domestic Shorthair

SEX

Neutered male

AGE

9 years

WEIGHT

9.5 lbs

INTERPRETED BY

Eric Lindquist, DMV
DABVP, Cert. IVUSS

IMAGING PERFORMED BY

Jack Reese

HOSPITAL NAME

Willow Run VC

REFERRING VET

Dr. Wasik Arnold

INVOICE

75000

DATE

4/29/26

Gastrointestinal

A minor amount of non-shadowing, non-obstructive ingesta was noted in the **stomach**. Transit of chyme into the small intestine was normal. Curvilinear patterns were maintained throughout the GI tract. No evidence of pathology. Small and large intestine demonstrated normal luminal chyme and stool consistency respectively. No obstructive or overt infiltrative disease was noted. No associated abnormal lymphatic activity was noted.

Pancreas

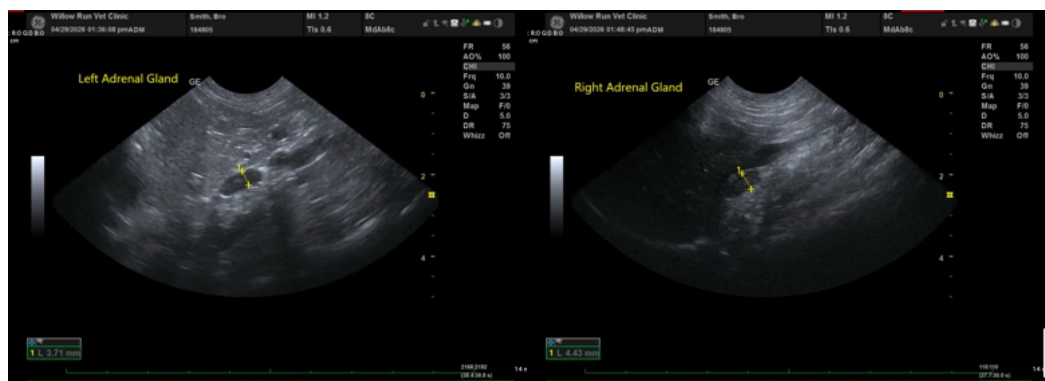The base and limbs of the **pancreas** were observed to be largely isoechoic to surrounding omental fat. Pancreatic duct and capsular contour were acceptably normal and parenchyma respected normal curvilinear patterns. No overt evidence of active inflammatory or neoplastic disease was noted.

ULTRASONOGRAPHIC FINDINGS

Micronodular splenic changes.

INTERPRETATION OF THE FINDINGS & FURTHER RECOMMENDATIONS

Given the fever FNA of the spleen with cytology and culture is indicated to ensure that splenitis is not an issue.





PATIENT

Bro Smith

SPECIES

Feline

BREED

Domestic Shorthair

SEX

Neutered male

AGE

9 years

WEIGHT

9.5 lbs

INTERPRETED BY

Eric Lindquist, DMV
DABVP, Cert. IVUSS

IMAGING PERFORMED BY

Jack Reese

HOSPITAL NAME

Willow Run VC

REFERRING VET

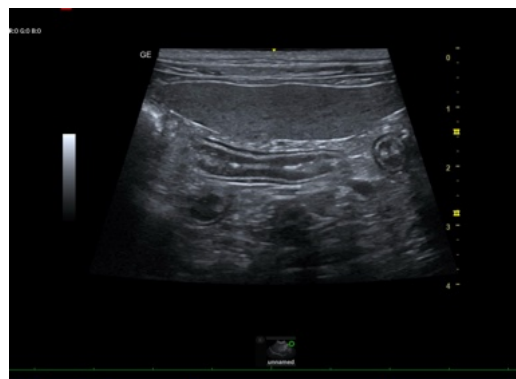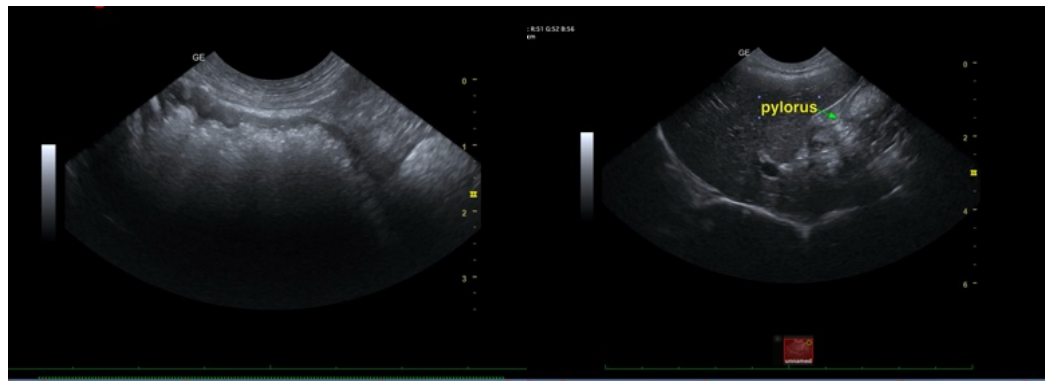
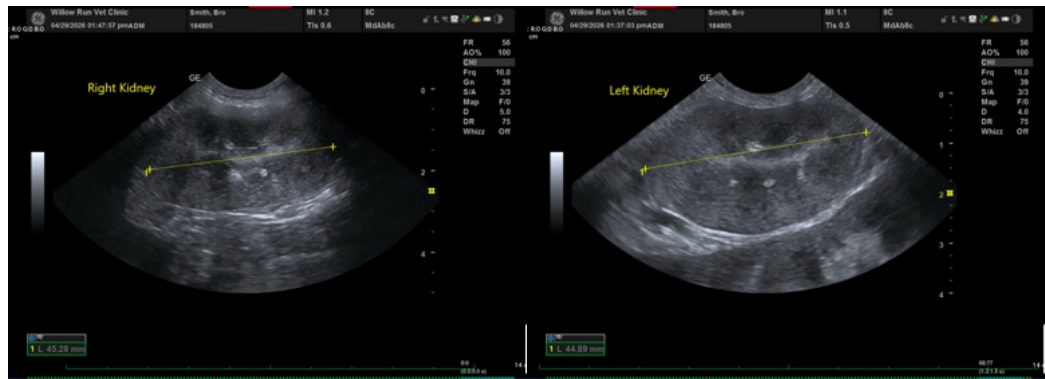
Dr. Wasik Arnold

INVOICE

75000

DATE

4/29/26



The information and recommendations provided are based on the images presented by the referring veterinarian/sonographer. No evaluation can be communicated regarding pathology that was not visible in the image/video clips provided.

Thank you for this referral. If the clinical or image interpretation does not parallel your findings or if I can be of any further assistance please contact me.

Eric Lindquist, DMV, DABVP (CFM), Cert. IVUSS, CEO of SonoPath.com

info@SonoPath.com