



PATIENT

Zoie Fedele

PRESENTING CLINICAL SIGNS

Murmur, had two syncopal episodes.

SPECIES

Canine

BREED

Maltese X

SEX

Spayed Female

AGE

15 Years

WEIGHT

10.7 Pounds

ULTRASONOGRAPHIC EXAMINATION OF THE HEART

CANINE CARDIAC PARAMETERS	MR VMAX (m/s)	TR VMAX (m/s)	LA/AO (Boon method)	LA/AO (Heart Base; Swe)	FS (%)	EF (%)	EPSS (cm)
NORMAL PARAMETER	4.5-5.5	<2.7	1.3	<1.6	28-40	40-100	<0.6
PATIENT	5.93	3.28	2.0	2.4	54	86	0.1
CANINE CARDIAC PARAMETERS	HR (BPM)	AV VMAX (m/s)	PV MAX (m/s)	BODY WEIGHT (kg)	LA 2D short axis Base view (cm)	LVIDd Avg; 2D and m-mode short axis (cm)	LVIDs Avg; 2D and m-mode short axis (cm)
NORMAL PARAMETER	50-100	0.7-1.7	0.7-1.6	BELOW	BELOW	BELOW	BELOW
PATIENT	196	1.51	1.29		4.36	3.45	

Cardiac Presentation

Severe **left atrial** enlargement noted in this patient with deviation of the atrial septum. Chamber volumes and echogenicity were normal. The cranial and caudal **mitral valve** leaflets presented vegetative thickening consistent with endocardiosis. Doppler indicated measurable insufficiency. Prolapse of the anterior mitral valve leaflet noted. The **left ventricle** presented thicknesses with linear contour and was not dilated nor restricted. The **myocardium** presented normal echogenicity without subjective evidence of significant fibrotic or ischemic disease. **Contractility** of the ventricular walls was adequate and in normal range for this patient evidenced by the fractional shortening measurement and subjective evaluation of the different regions of the myocardium. The **left ventricular outflow** tract demonstrated normal laminar flow and subjective structural integrity. Mild **right atrial** enlargement noted. **Tricuspid** insufficiency noted at 3.28 m/sec, consistent with mild pulmonary hypertension. The **right ventricle** was of normal size (1/3 diameter of LV), chordae structure, myocardial echogenicity and thickness. **Pulmonic** tract assessment revealed normal valve structure, laminar flow, and diameter (approx.1:1 pa/ao ratio). No visible **pericardial** or free pleura fluid was noted. No echographically detectable evidence of infiltrative disease was visible. The cranial **mediastinum** and **pericardial regions** were free of masses in the visible window. Periodic arrhythmia noted.

INTERPRETED BY

Eric Lindquist, DMV
DABVP, Cert. IVUSS

IMAGING PERFORMED BY

Eric Lindquist, DMV
DABVP, Cert. IVUSS

HOSPITAL NAME

Parsippany Troy Hills

REFERRING VET

Dr. Dulude

ULTRASONOGRAPHIC FINDINGS

- Stage C1 valvular disease

INVOICE

37290

DATE

4/29/22

INTERPRETATION OF THE FINDINGS & FURTHER RECOMMENDATIONS

Recommend the following protocol: Lasix 2-4 mg/kg BID, Spironolactone 1-2 mg/kg BID, ACE inhibitor 0.5 mg/kg SID progressing to BID, and Vetmedin at 0.3 mg/kg BID. Guarded prognosis. The patient is at risk for sudden death.



PATIENT

Zoie Fedele

The heart is in a somewhat precarious state with volume overload and a heart that is working to compensate for the valvular insufficiency. Target respiratory rate is < 20 resp/minute after therapy. After initiating therapy, I recommend recheck on the clinical exam, BUN, Creatinine, USG, Chest radiographs & Blood pressure in 5-7 days. Recheck echo in 1 month. Earlier if clinical decompensation is occurring. I do not recommend anesthesia at this time until stabilization has occurred on the recommended medications. Repeat preanesthetic echo is ideal if anesthesia is eventually necessary. There is severe anesthetic risk for this patient. Light dose opioids may be used to calm but I do not recommend anesthesia.

SPECIES

Canine

BREED

Maltese X

SEX

Spayed Female

AGE

15 Years

WEIGHT

10.7 Pounds

INTERPRETED BY

Eric Lindquist, DMV
DABVP, Cert. IVUSS

IMAGING PERFORMED BY

Eric Lindquist, DMV
DABVP, Cert. IVUSS

HOSPITAL NAME

Parsippany Troy Hills

REFERRING VET

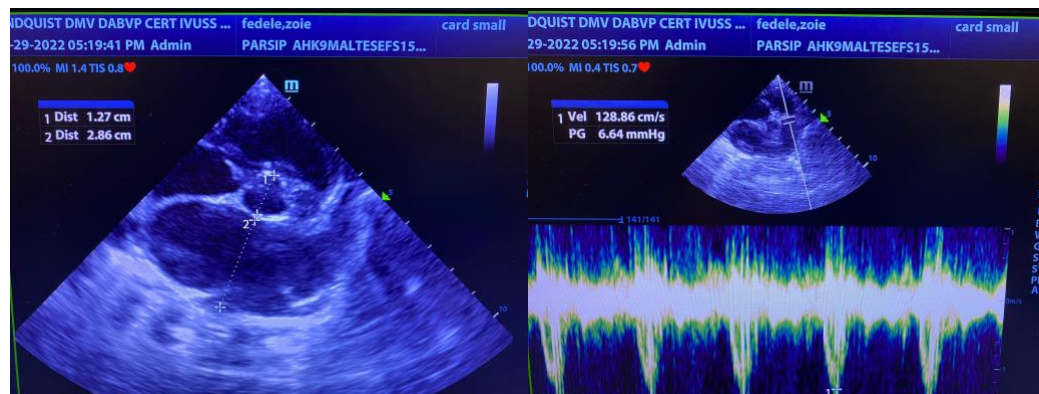
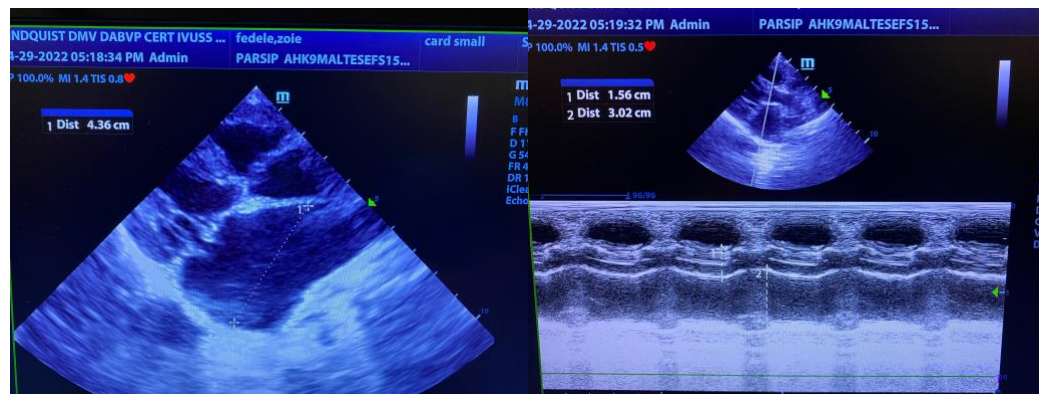
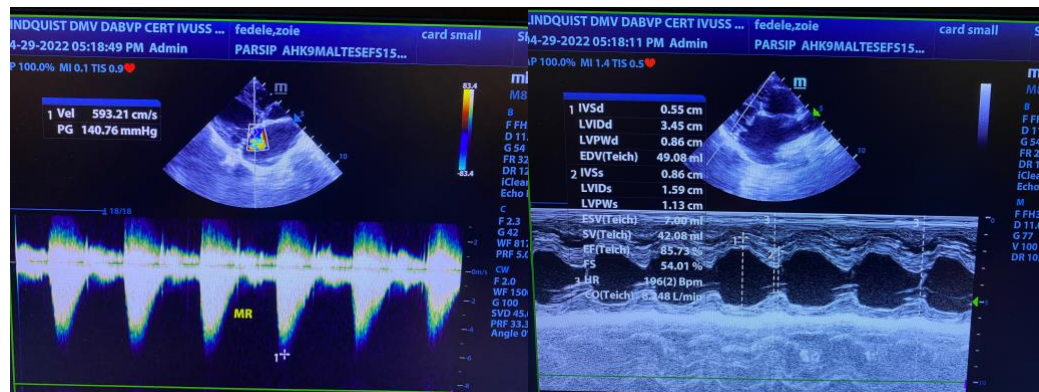Dr. Dulude

INVOICE

37290

DATE

4/29/22





PATIENT

Zoie Fedele

SPECIES

Canine

BREED

Maltese X

SEX

Spayed Female

AGE

15 Years

WEIGHT

10.7 Pounds

INTERPRETED BY

Eric Lindquist, DMV

DABVP, Cert. IVUSS

IMAGING PERFORMED BY

Eric Lindquist, DMV

DABVP, Cert. IVUSS

HOSPITAL NAME

Parsippany Troy Hills

REFERRING VET

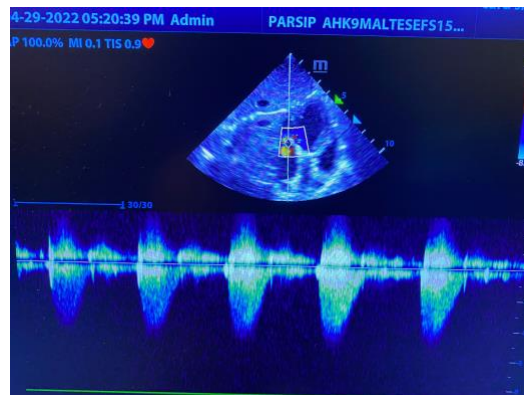
Dr. Dulude

INVOICE

37290

DATE

4/29/22



The information and recommendations provided are based on the images presented by the referring veterinarian/sonographer. No evaluation can be communicated regarding pathology that was not visible in the image/video clips provided.

Thank you for this referral. If the clinical or image interpretation does not parallel your findings or if I can be of any further assistance please contact me.

Eric Lindquist, DMV, DABVP, Cert. IVUSS, CEO of SonoPath.com

info@SonoPath.com