



**PATIENT PRESENTING CLINICAL SIGNS**

**PATIENT**  
Sam Stark  
Chronic vomiting. Laxatone once daily helps at decreasing frequency, but still vomits. Same diet lams hairball dry.

**SPECIES**  
Feline  
Abnormal PE/Chem/CBC/UA Results: April 22, 2022 Grade 2/6 parasternal systolic murmur. CBC normal. Chemistry mild hypocholesterolemia 61 (65-225), normal SDMA and TT4. Three view radiographs, thorax OK, Abdomen OK. Spleen not visible on lateral views, but on VD view spleen very small.

**BREED ULTRASONOGRAPHIC EXAMINATION OF THE ABDOMEN**

Domestic Shorthair

**Urinary System**

**SEX**

Neutered male

The **urinary bladder**, trigone, and pelvic urethra presented normal thicknesses and normal tone. The ureters were not visible which is normal. No uroliths or sediment were visualized and anechoic urine was present. No evidence of inflammatory or neoplastic changes was noted. Ureteral papillae were normal. The pelvic urethra was imaged 2.0 cm beyond the cystourethral junction.

**AGE**

11 years

The **kidneys** revealed largely normal size and structure, corticomedullary definition and ratio (cortex 1/3 of medulla) were essentially maintained with some minor age-related loss of curvilinear patterns regarding the capsule and C/M junction. The cortices presented largely uniform texture with some increased echogenicity expected for his age patient. Medullary structure differed distinctly from that of the cortex and no evidence of pelvic dilation was present. Mineralization was noted in the kidneys. The left kidney measured 4.17 cm. The right kidney measured 4.18 cm.

**WEIGHT**

1.05 lbs

**Adrenal Glands**

**INTERPRETED BY**

Eric Lindquist, DMV  
DABVP, Cert. IVUSS

Both **adrenal glands** were visualized and recognized as having normal shape, size, position and echogenicity for this breed. The phrenic vasculature, glandular echogenicity and detail were unremarkable. Capsule, cortex, and medullary definition were normal for this age patient. The right adrenal gland measured 0.31 cm. The left adrenal gland measured 0.36 cm.

**IMAGING PERFORMED BY**

Dr. Brenner

**Spleen**

**HOSPITAL NAME**

Riverside AC

The **spleen** presented a smooth homogeneous parenchyma hyperechoic to liver and renal cortical parenchyma. The capsule was smooth without noticeable expansion or deviation from within the spleen or adjacent pathology. The splenic vasculature demonstrated normal volume without signs of congestion or thrombosis. No sonographic evidence of acute or chronic inflammatory, neoplastic, or infarctual changes was noted.

**Liver**

**REFERRING VET**

Dr. Coe

The **liver** images submitted revealed subjectively normal liver size, contour, and structure. Parenchymal echogenicity was naturally coarse and hypoechoic to the spleen. Vascular and biliary tracts were of normal volume with no evidence of congestion. The gallbladder presented acceptably thin walls with primarily anechoic content. The cystic and common bile ducts were normal. No pathological hepatic lymphadenopathy was evident.

**INVOICE**

14966

**Gastrointestinal**

**DATE**

4/29/22

The **gastrointestinal** presentation revealed mild uniform prominence of the gastric mucosa as well as areas of "ropey" small intestinal wall with slight disruption of the normal 1:3 muscularis/mucosal ratio.



**PATIENT**

Sam Stark

**SPECIES**

Feline

**BREED**

Domestic Shorthair

**SEX**

Neutered male

**AGE**

11 years

**WEIGHT**

1.05 lbs

**INTERPRETED BY**

Eric Lindquist, DMV  
DABVP, Cert. IVUSS

**IMAGING PERFORMED BY**

Dr. Brenner

**HOSPITAL NAME**

Riverside AC

**REFERRING VET**

Dr. Coe

**INVOICE**

14966

**DATE**

4/29/22

The intestinal submucosa was slightly irregular, thickened and hyperechoic suggestive of low grade, chronic disease. No concerning lymphadenopathy was visible. No evidence of obstruction was present. Chronic inflammatory bowel disease is likely with a low possibility of an early neoplastic event such as lymphoma. Full thickness tissue biopsies via open laparotomy, ideally guided by intraoperative ultrasound in order to obtain the most representative mural sample, would be necessary to rule out this possibility. This is a mild change.

**Pancreas**

The base and limbs of the **pancreas** were observed to be largely isoechoic to surrounding omental fat. Pancreatic duct and capsular contour were acceptably normal, and parenchyma respected normal curvilinear patterns. No overt evidence of active inflammatory or neoplastic disease was noted.

**Free Abdomen**

Trace **free fluid** was noted between the liver lobes and gallbladder, the cause is unclear. Trace free fluid noted intestinal loops and urinary bladder as well.

Slight mesenteric lymphadenopathy noted, reactive, up to 5.0 mm in length.

**ULTRASONOGRAPHIC FINDINGS**

- Minor age-related renal changes with slight mineralization
- Trace free fluid
- Inflammatory bowel pattern with mesenteric lymphadenopathy, reactive
- Age-related renal changes with mineralization

**INTERPRETATION OF THE FINDINGS & FURTHER RECOMMENDATIONS**

Free fluid may be related to inflammatory events associated with the GI tract or lymphatic obstruction. Assuming no cortisones have been utilized in this patients protocol, there is no overt evidence of neoplastic criteria. However, full thickness lymph node and intestinal biopsies would be ideal in this patient. If sampling is not an option, a clinical trial of the following would be ideal. Hydrolyzed diet is likely best. No evidence of hairball accumulation.

**Triaditis/Pancreatitis protocol**

Part or all of this protocol may be considered based on your clinical impression of the patient:

Recommend pain management when anorexic with **Buprenorphine** (0.01-0.02 mg/kg IM or SC), clinical trial of **Zithromax** (50 mg sid/cat x 10 days, 3 weeks if bartonella +), **Prednisolone** (0.5-2 mg/kg tapering over 1 week to minimal effective dose), and **B12 injections** if weight loss (Cyanobalamine 250 mcg sub-q once-weekly x six weeks, then every other week for six weeks and then once-monthly, long-term if necessary), **novel-protein or hydrolyzed diet** (*Hydrolyzed diets have been shown to be more effective in dietary intolerance case management compared to hypoallergenic diets*) or the **magical Purina DM** (changing protein source is crucial and may need rotation every 6 months if clinical signs recur) Diet trials is a whatever works phenomenon. If vomiting becomes a persistent issue then endoscopy would be warranted and/or recheck sonogram to assess more emerging disease. One diet does not work for all patients so different trials may be necessary or protein source rotation every 6 months as new sensitivities develop.



**PATIENT**

Sam Stark

**SPECIES**

Feline

**BREED**

Domestic Shorthair

**SEX**

Neutered male

**AGE**

11 years

**WEIGHT**

1.05 lbs

**INTERPRETED BY**

Eric Lindquist, DMV  
DABVP, Cert. IVUSS

**IMAGING PERFORMED BY**

Dr. Brenner

**HOSPITAL NAME**

Riverside AC

**REFERRING VET**

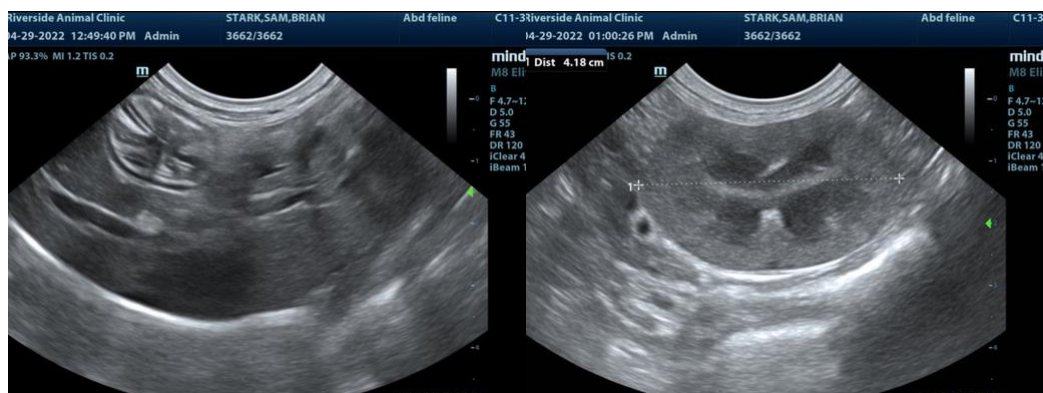
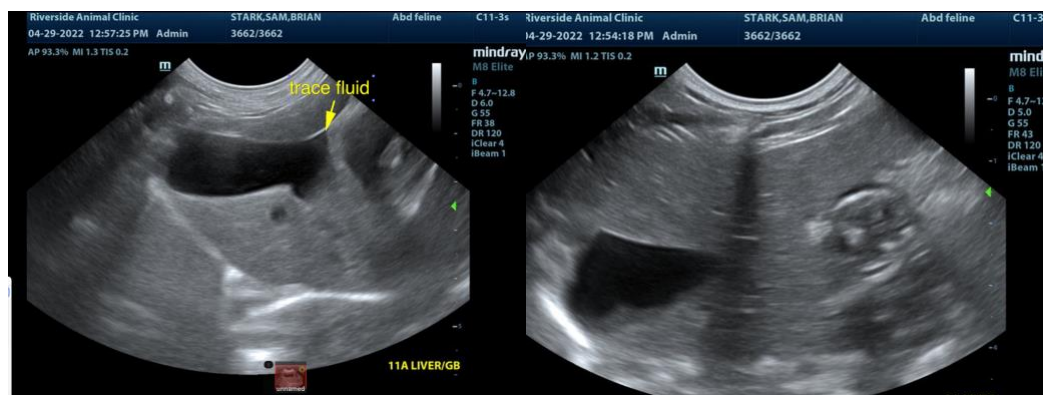
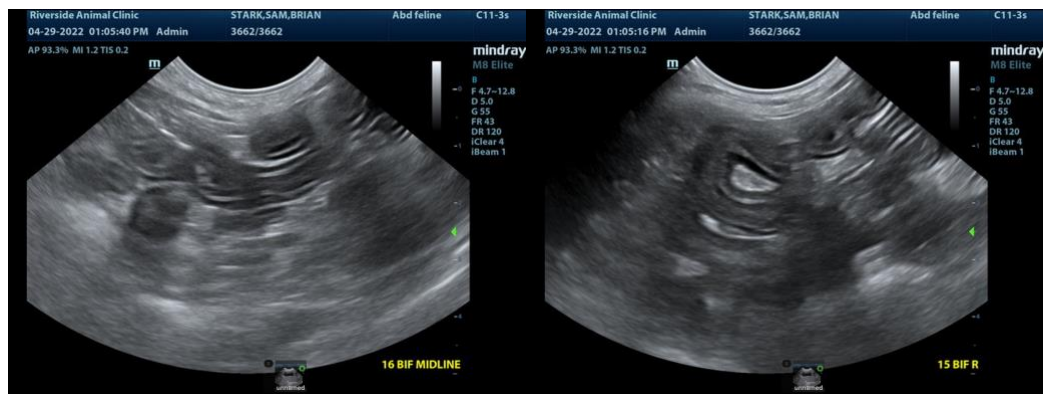
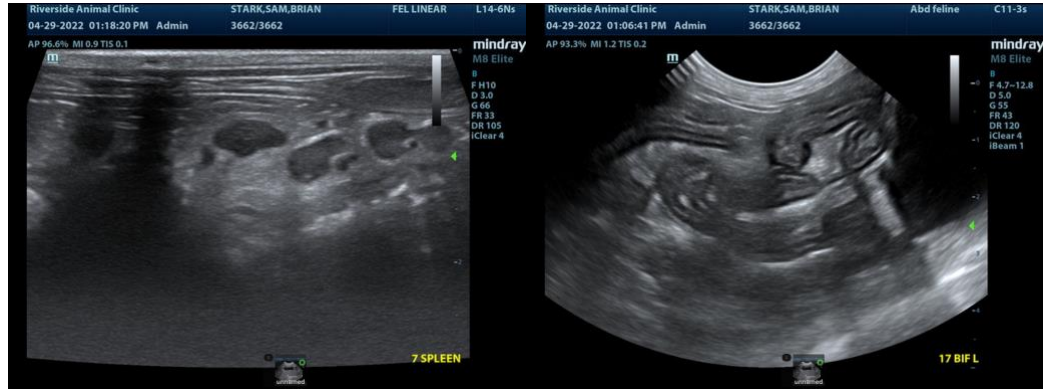
Dr. Coe

**INVOICE**

14966

**DATE**

4/29/22





**PATIENT**

Sam Stark

**SPECIES**

Feline

**BREED**

Domestic Shorthair

**SEX**

Neutered male

**AGE**

11 years

**WEIGHT**

1.05 lbs

**INTERPRETED BY**

Eric Lindquist, DMV  
DABVP, Cert. IVUSS

**IMAGING PERFORMED BY**

Dr. Brenner

**HOSPITAL NAME**

Riverside AC

**REFERRING VET**

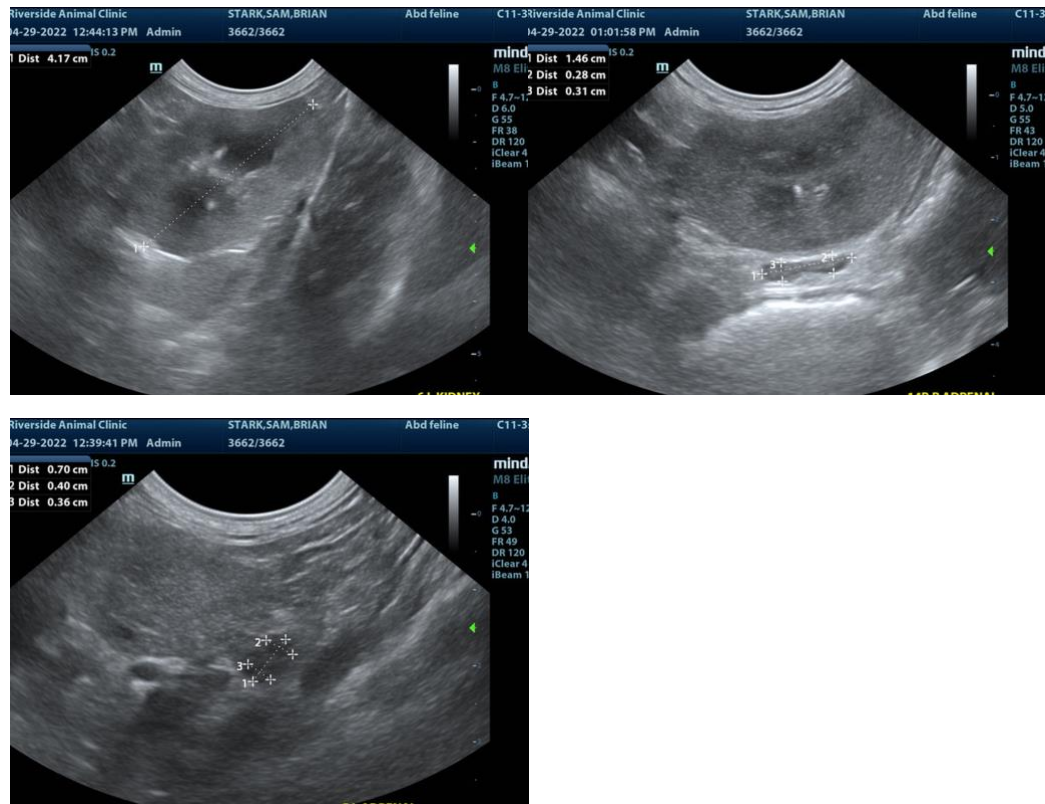
Dr. Coe

**INVOICE**

14966

**DATE**

4/29/22



The information and recommendations provided are based on the images presented by the referring veterinarian/sonographer. No evaluation can be communicated regarding pathology that was not visible in the image/video clips provided.

Thank you for this referral. If the clinical or image interpretation does not parallel your findings or if I can be of any further assistance please contact me.

**Eric Lindquist**, DMV, DABVP, Cert. IVUSS, CEO of SonoPath.com  
info@SonoPath.com