



PATIENT PRESENTING CLINICAL SIGNS

Percy Ball History: Elevated alt, 460. All else ok.

SPECIES ULTRASONOGRAPHIC EXAMINATION OF THE ABDOMEN

Canine

Urinary System

BREED

The **urinary bladder**, trigone, and pelvic urethra presented normal thicknesses and normal tone. The ureters were not visible which is normal. No uroliths or sediment were visualized, and anechoic urine was present. No evidence of inflammatory or neoplastic changes was noted. Ureteral papillae were normal.

Cavalier

SEX

The **kidneys** revealed normal size and structure, corticomedullary definition and ratio for this age. The cortices presented largely uniform texture with normal echogenic relationship to liver and spleen. Medullary structure differed distinctly from the cortex and no evidence of pelvic dilation was present. The capsules were acceptably uniform without significant irregularities. The left kidney measured 5.0 cm. The right kidney measured 4.0 cm.

Neutered male

AGE

10 years

Adrenal Glands

WEIGHT

25 lbs

The **left adrenal gland** was visualized and recognized as having normal shape, size, position and echogenicity for this breed. The phrenic vasculature, glandular echogenicity and detail were unremarkable. Capsule, cortex, and medullary definition were normal for this age patient. The left adrenal gland measured 0.4 cm.

INTERPRETED BY

The region of the **right adrenal gland** was imaged. No evidence of pathology.

Eric Lindquist, DMV
DABVP, Cert. IVUSS

Spleen

IMAGING PERFORMED BY

Dr. Hunt

The **spleen** presented a smooth homogeneous parenchyma hyperechoic to liver and renal cortical parenchyma. The capsule was smooth without noticeable expansion or deviation from within the spleen or adjacent pathology. The splenic vasculature demonstrated normal volume without signs of congestion or thrombosis. No sonographic evidence of acute or chronic inflammatory, neoplastic, or infarctual changes was noted.

HOSPITAL NAME

Bayshore VH

Liver

The **liver** in this patient revealed a 3.44 cm microcystic parenchymal expansive nodule/mass. The left cranial liver mass does appear resectable with full left lobectomy, however, subjectively appears low-grade or benign. Minor increased portal markings were noted elsewhere in the liver. The gallbladder and common bile duct were unremarkable.

REFERRING VET

Dr. Hunt

Gastrointestinal

INVOICE

14965

Some minor retention of ingesta was noted in the **stomach**. The stomach was otherwise normal. The small intestine and colon were unremarkable.

Pancreas

DATE

4/29/22



PATIENT

Percy Ball

The base and limbs of the **pancreas** were observed to be largely isoechoic to surrounding omental fat. Pancreatic duct and capsular contour were acceptably normal, and parenchyma respected normal curvilinear patterns. No overt evidence of active inflammatory or neoplastic disease was noted.

SPECIES

Canine

ULTRASONOGRAPHIC FINDINGS

- Left cranial liver nodule, granulomatous lesion, pronounced nodular hyperplasia with cystic component. Carcinoma is a minor potential. I recommend treatment based on FNA results.
- Stomach ingesta

BREED

Cavalier

INTERPRETATION OF THE FINDINGS & FURTHER RECOMMENDATIONS

A clinical trial of enrofloxacin/metronidazole combination over a 10-day period and reassessment of liver values could be considered or a more specific treatment based on cytology results.

SEX

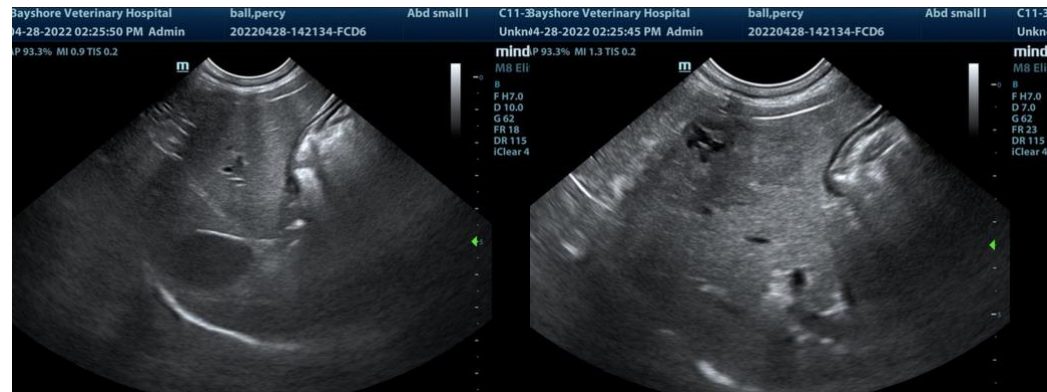Neutered male

AGE

10 years

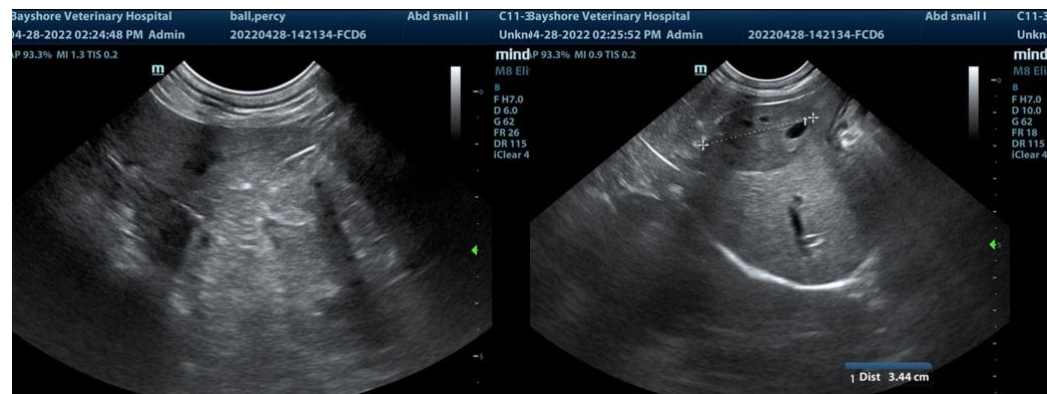
WEIGHT

25 lbs



INTERPRETED BY

Eric Lindquist, DMV
DABVP, Cert. IVUSS



IMAGING PERFORMED BY

Dr. Hunt

HOSPITAL NAME

Bayshore VH

REFERRING VET

Dr. Hunt

The information and recommendations provided are based on the images presented by the referring veterinarian/sonographer. No evaluation can be communicated regarding pathology that was not visible in the image/video clips provided.

Thank you for this referral. If the clinical or image interpretation does not parallel your findings or if I can be of any further assistance please contact me.

INVOICE

14965

Eric Lindquist, DMV, DABVP, Cert. IVUSS, CEO of SonoPath.com
info@SonoPath.com

DATE

4/29/22