

PATIENT

Logan Laboy

SPECIES

Canine

BREED

Lab

SEX

Male

AGE

13 Years

WEIGHT

72 Pounds

INTERPRETED BY

Eric Lindquist, DMV

DABVP, Cert. IVUSS

IMAGING PERFORMED BY

Eric Lindquist, DMV

DABVP, Cert. IVUSS

HOSPITAL NAME

Parsippany Troy Hills

REFERRING VET

Dr. Dulude

INVOICE

37289

DATE

4/29/22

PRESENTING CLINICAL SIGNS

Hx of mast cell tumors. Vomiting, weight loss, anorexic, icteric.

ULTRASONOGRAPHIC EXAMINATION OF THE ABDOMEN

Urinary System

The **urinary bladder**, trigone, and pelvic urethra presented normal thicknesses and normal tone. The ureters were not visible which is normal. No uroliths or sediment were visualized and anechoic urine was present. No evidence of inflammatory or neoplastic changes were noted. Ureteral papillae were normal.

The **prostate** was uniformly enlarged (5.0 cm) with lobar swelling appeared to impinge upon the urethra and mildly deviate the descending colon. The prostatic tissue was hyperechoic containing focal areas of decreased echogenicity. These changes are suggestive of either chronic inflammatory episodes, benign cystic pathology or both. Underlying neoplasia cannot be completely ruled-out but is lower on the differential list. This presentation is most consistent with benign prostatic hyperplasia with possible active prostatitis. Neutering or off-label Finasteride (Propecia) (0.1-0.5 mg/kg Sid) treatment is indicated +/- FNA or prostatic wash cytology and culture.

The **kidneys** were mildly enlarged and swollen. Slight hypoechoic 5.0 mm nodule noted in the caudal pole of the left kidney, may represent a metastatic lesion. The right kidney measured 6.0 cm. The left kidney measured 6.0 cm.

Adrenal Glands

Both **adrenal glands** were visualized and recognized as having normal shape, size, position and echogenicity for this breed. The phrenic vasculature, glandular echogenicity and detail were unremarkable. Capsule, cortex, and medullary definition were normal for this age patient. The left adrenal gland measured 2.33 cm x 0.49 cm. The right adrenal gland measured 2.59 cm x 1.42 cm at the cranial pole and 0.60 cm at the caudal pole.

Spleen

The **spleen** revealed an infiltrative pattern with coalescing micronodular changes and swollen, irregular contour.

Liver

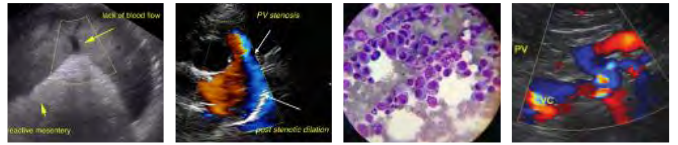
The **liver** revealed increased portal markings, coarse architecture, isoechoic nodular changes and irregular contour. Hepatic lymphadenopathy noted, rounded lymph nodes measured up to 2.0 cm. The gallbladder was unremarkable.

Gastrointestinal

Stasis noted in the **stomach**. The small intestine and colon were unremarkable.

Pancreas

The base and limbs of the **pancreas** were observed to be largely isoechoic to surrounding omental fat. Pancreatic duct and capsular contour were acceptably normal and parenchyma respected normal curvilinear patterns. No overt evidence of active inflammatory or neoplastic disease was noted.



PATIENT

Logan Laboy

SPECIES

Canine

BREED

Lab

SEX

Male

AGE

13 Years

WEIGHT

72 Pounds

INTERPRETED BY

Eric Lindquist, DMV
DABVP, Cert. IVUSS

IMAGING PERFORMED BY

Eric Lindquist, DMV
DABVP, Cert. IVUSS

HOSPITAL NAME

Parsippany Troy Hills

REFERRING VET

Dr. Dulude

INVOICE

37289

DATE

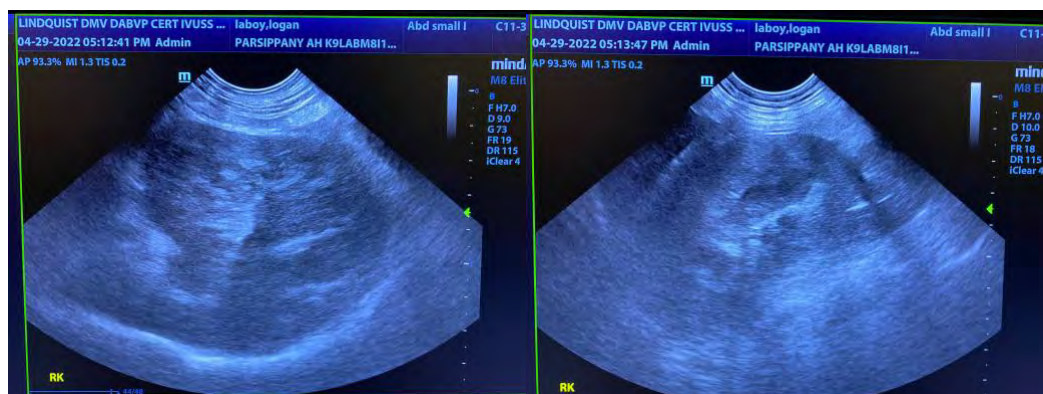
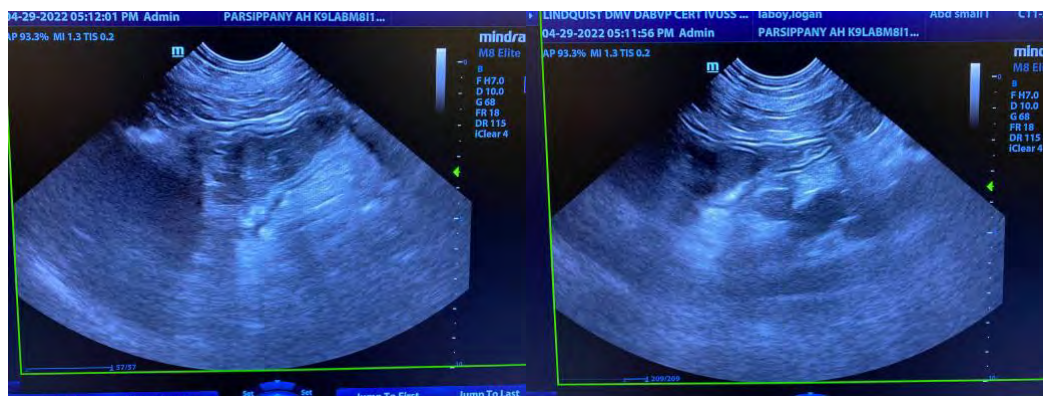
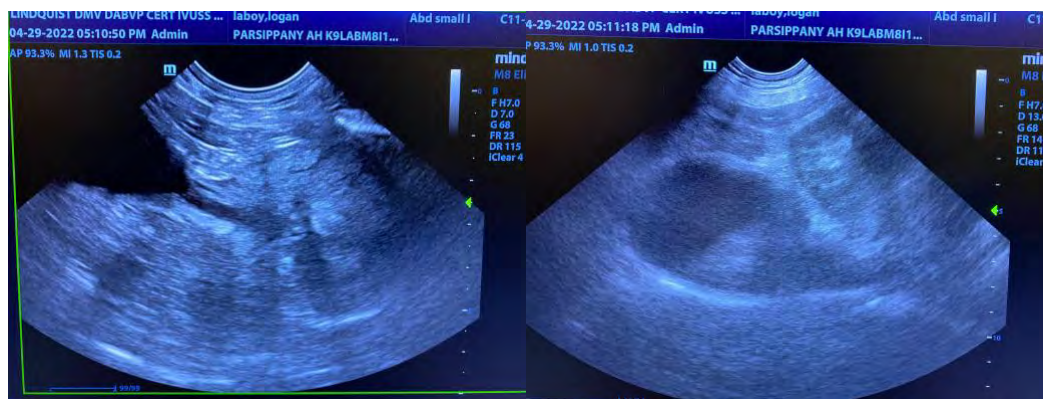
4/29/22

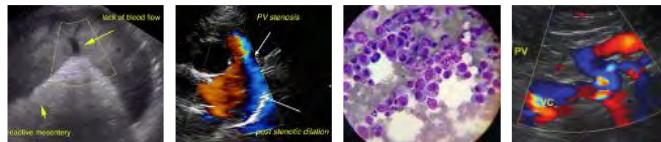
ULTRASONOGRAPHIC FINDINGS

- Infiltrative splenic and hepatic patterns with hepatic lymphadenopathy
- Gastric stasis
- BPH prostate

INTERPRETATION OF THE FINDINGS & FURTHER RECOMMENDATIONS

Strongly suggestive for infiltrative disease involving the spleen and liver. Coagulation panel, Benadryl injection and FNA spleen and liver recommended. Prognosis is guarded to poor depending upon cytology results. Mild potential for splenitis, cholangiohepatitis.





PATIENT

Logan Laboy

SPECIES

Canine

BREED

Lab

SEX

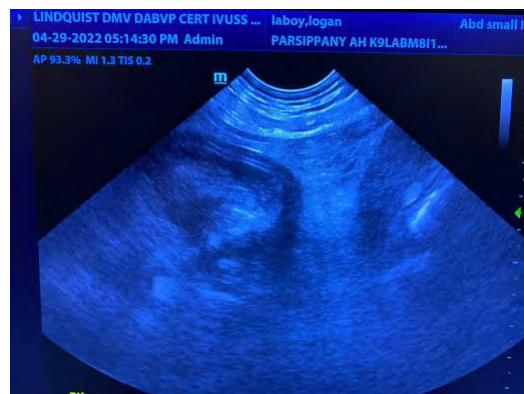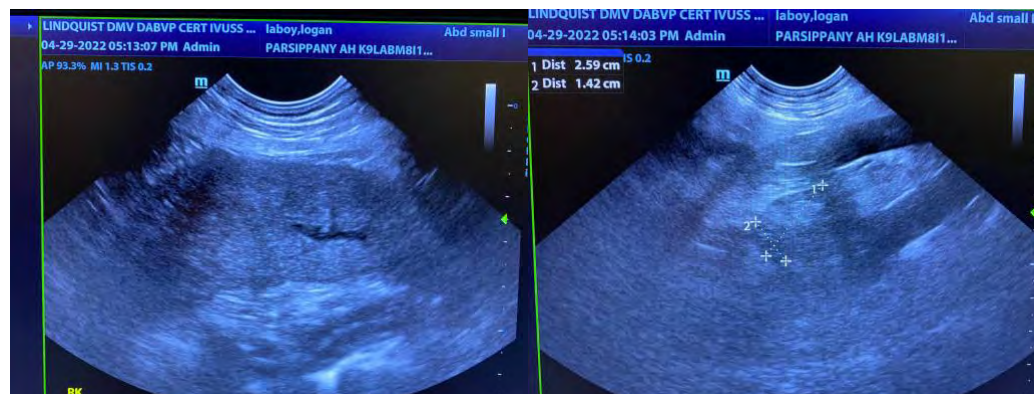
Male

AGE

13 Years

WEIGHT

72 Pounds



INTERPRETED BY

Eric Lindquist, DMV
DABVP, Cert. IVUSS

IMAGING PERFORMED BY

Eric Lindquist, DMV
DABVP, Cert. IVUSS

HOSPITAL NAME

Parsippany Troy Hills

REFERRING VET

Dr. Dulude

INVOICE

37289

DATE

4/29/22

The information and recommendations provided are based on the images presented by the referring veterinarian/sonographer. No evaluation can be communicated regarding pathology that was not visible in the image/video clips provided.

Thank you for this referral. If the clinical or image interpretation does not parallel your findings or if I can be of any further assistance please contact me.

Eric Lindquist, DMV, DABVP, Cert. IVUSS, CEO of SonoPath.com

info@SonoPath.com