



**PATIENT**

Jango Brewer

**SPECIES**

Canine

**BREED**

Great Dane

**SEX**

Male

**AGE**

5 months

**WEIGHT**

44 lbs

**INTERPRETED BY**

Eric Lindquist, DMV  
DABVP, Cert. IVUSS

**IMAGING PERFORMED BY**

Dr. Mengine

**HOSPITAL NAME**

Stoney Creek VH

**REFERRING VET**

Dr. Mengine

**INVOICE**

14961

**DATE**

4/29/22

**PRESENTING CLINICAL SIGNS**

History: Presented 4/23 for 24 hrs of diarrhea, including an episode of tenesmus that ended with dry heaving. Treated with metronidazole, bland diet and probiotic. Re-presented 4/25 for lethargy and elevated 3rd eyelids. CBC / Chem unremarkable except slightly low sodium. Had U/S with DACVR on 4/25, unremarkable - treated with IV fluids. On 4/26 became PU/PD, recheck 4/27 - Chem panel wnl (including sodium, Na:K+ = 37), urine SpGr 1.002, else unremarkable. Cortisol 2.0, Lepto PCR pending, empiric trx for possible leptospirosis started 4/27, and added pumpkin to diet to hopefully stimulate BM. Presented today because still lethargic and still no BM (but eating well, no vomiting, no straining).

**ULTRASONOGRAPHIC EXAMINATION OF THE ABDOMEN**

**Urinary System**

The **urinary bladder**, trigone, and pelvic urethra presented normal thicknesses and normal tone. The ureters were not visible which is normal. No uroliths or sediment were visualized, and anechoic urine was present. No evidence of inflammatory or neoplastic changes was noted. Ureteral papillae were normal.

The **kidneys** revealed normal size and structure, corticomedullary definition and ratio for this age. The cortices presented largely uniform texture with normal echogenic relationship to liver and spleen. Medullary structure differed distinctly from the cortex and no evidence of pelvic dilation was present. The capsules were acceptably uniform without significant irregularities. The left kidney measured 7.0 cm. The right kidney measured 6.86 cm.

**Adrenal Glands**

Both **adrenal glands** were subjectively flattened for this age and breed. The left adrenal gland measured 0.5 cm at the caudal pole and 0.51 cm at the cranial pole. The right adrenal gland measured 0.4 cm at the caudal pole and 0.46 cm at the cranial pole.

**Spleen**

Minor reticulated **splenic** pattern noted, likely reactive state.

**Liver**

The **liver** images submitted revealed subjectively normal liver size, contour, and structure. Parenchymal echogenicity was naturally coarse and hypoechoic to the spleen. Vascular and biliary tracts were of normal volume with no evidence of congestion. The gallbladder presented acceptably thin walls with primarily anechoic content. The cystic and common bile ducts were normal. No pathological hepatic lymphadenopathy was evident. No overt structural evidence of inflammatory, infiltrative or regenerative pathology was evident.

**Gastrointestinal**

Some retention of ingesta was noted in the **stomach**, post-prandial presentation. Intestinal wall thickness measured up to 0.54 cm.

**Pancreas**



## PATIENT

Jango Brewer

The base and limbs of the **pancreas** were observed to be largely isoechoic to surrounding omental fat. Pancreatic duct and capsular contour were acceptably normal and parenchyma respected normal curvilinear patterns. No overt evidence of active inflammatory or neoplastic disease was noted.

## SPECIES

Canine

### Free Abdomen

The mesenteric **lymph nodes** (an example measured 3.23 cm x 0.38 cm) presented normal length to width ratio with slight, swollen contour. There was no loss of parenchymal detail. This is most consistent with reactive lymphadenitis or lymphatic hyperplasia.

## BREED

Great Dane

## ULTRASONOGRAPHIC FINDINGS

- Juvenile reactive mesenteric lymph nodes
- Subjectively flattened adrenal glands
- Reticulated splenic pattern
- Stomach ingesta
- Unremarkable abdomen

## SEX

Male

## AGE

5 months

## INTERPRETATION OF THE FINDINGS & FURTHER RECOMMENDATIONS

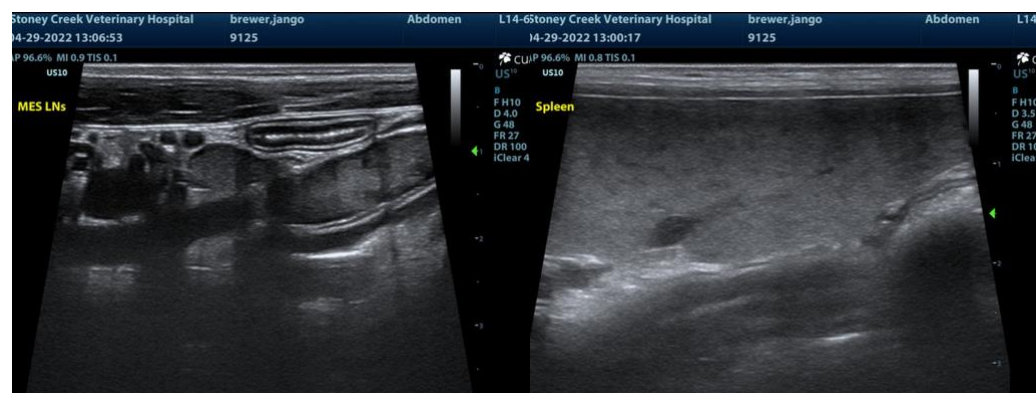
Given that urine baseline cortisol is borderline low, full ACTH stimulation warranted. Occult parasitism, dietary intolerance, occult Addison's all possible in this patient yet structurally the GI tract and abdomen are unremarkable, expected for this age and breed. If hyposthenuria is persistent, partial water deprivation test recommended to assess the ability to concentrate.

## WEIGHT

44 lbs

## INTERPRETED BY

Eric Lindquist, DMV  
DABVP, Cert. IVUSS

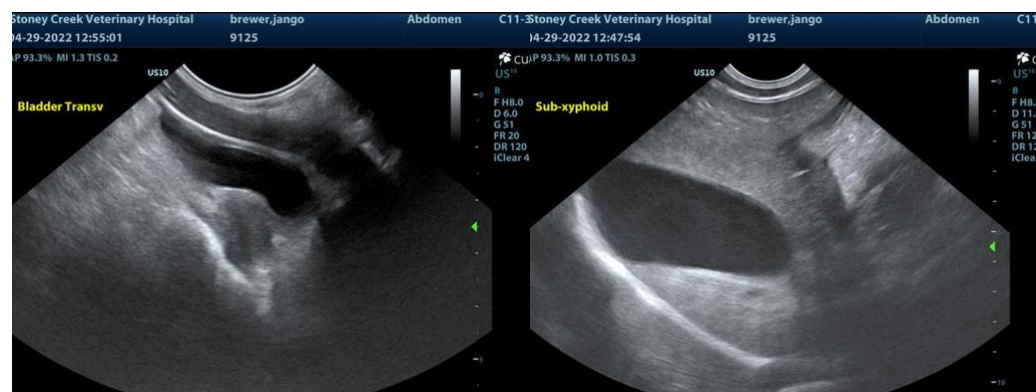


## IMAGING PERFORMED BY

Dr. Mengine

## HOSPITAL NAME

Stoney Creek VH



## REFERRING VET

Dr. Mengine

## INVOICE

14961

## DATE

4/29/22



**PATIENT**

Jango Brewer

**SPECIES**

Canine

**BREED**

Great Dane

**SEX**

Male

**AGE**

5 months

**WEIGHT**

44 lbs

**INTERPRETED BY**

Eric Lindquist, DMV  
DABVP, Cert. IVUSS

**IMAGING PERFORMED BY**

Dr. Mengine

**HOSPITAL NAME**

Stoney Creek VH

**REFERRING VET**

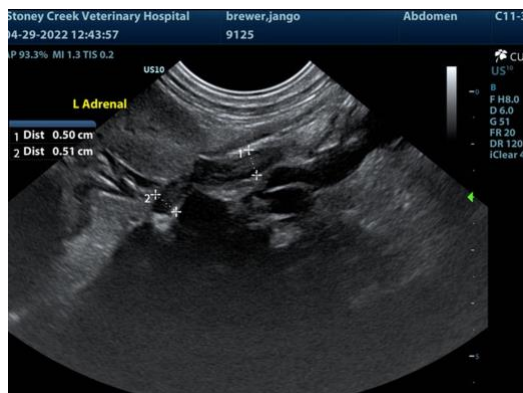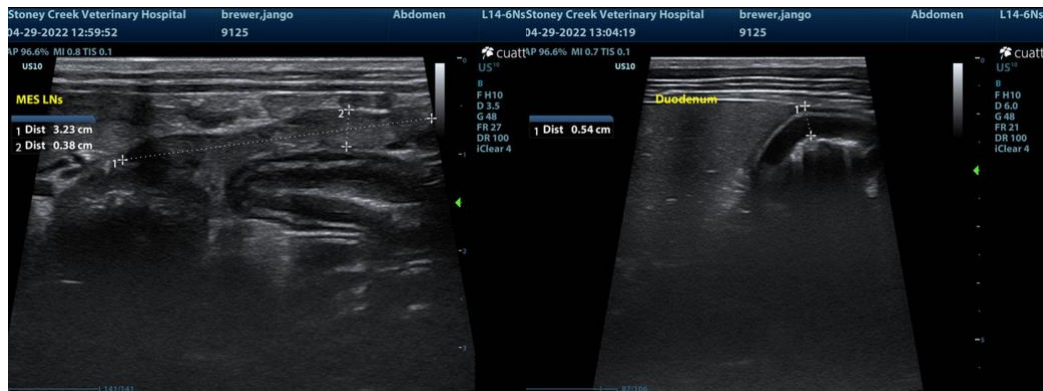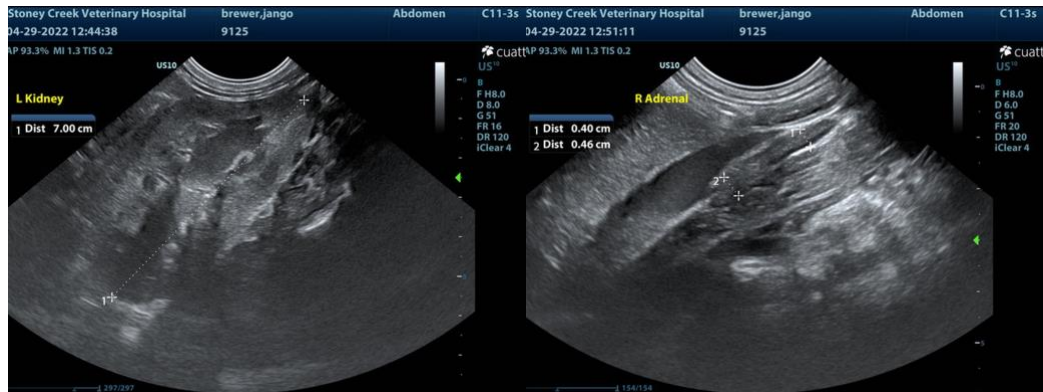
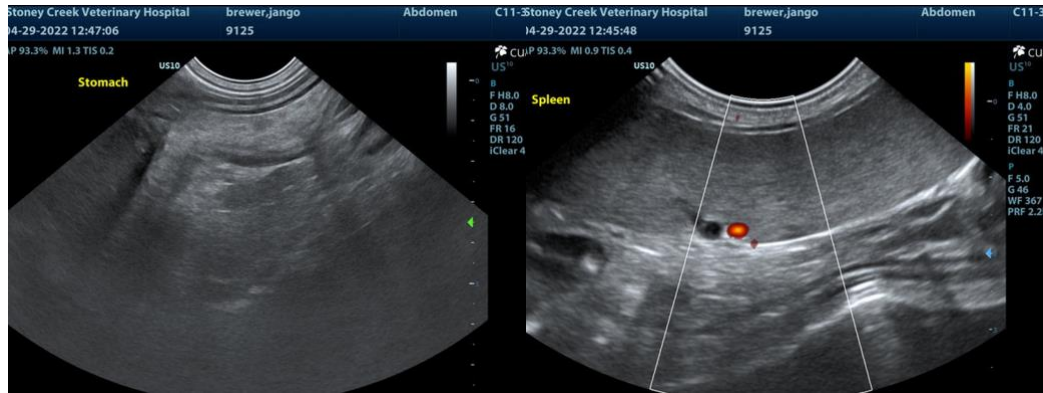
Dr. Mengine

**INVOICE**

14961

**DATE**

4/29/22





**PATIENT**

Jango Brewer

The information and recommendations provided are based on the images presented by the referring veterinarian/sonographer. No evaluation can be communicated regarding pathology that was not visible in the image/video clips provided.

**SPECIES**

Canine

Thank you for this referral. If the clinical or image interpretation does not parallel your findings or if I can be of any further assistance please contact me.

**BREED**

Great Dane

**Eric Lindquist**, DMV, DABVP, Cert. IVUSS, CEO of SonoPath.com  
info@SonoPath.com

**SEX**

Male

**AGE**

5 months

**WEIGHT**

44 lbs

**INTERPRETED BY**

Eric Lindquist, DMV  
DABVP, Cert. IVUSS

**IMAGING  
PERFORMED BY**

Dr. Mengine

**HOSPITAL NAME**

Stoney Creek VH

**REFERRING VET**

Dr. Mengine

**INVOICE**

14961

**DATE**

4/29/22