



**PATIENT**

Bebe Chen

**SPECIES**

Canine

**BREED**

Miniature Poodle

**SEX**

Neutered male

**AGE**

9 years

**WEIGHT**

12.1 lbs

**INTERPRETED BY**

Eric Lindquist, DMV  
DABVP, Cert. IVUSS

**IMAGING PERFORMED BY**

Evan Bell

**HOSPITAL NAME**

Cedarview AH

**REFERRING VET**

Kim Holzman

**INVOICE**

14964

**DATE**

4/29/22

**PRESENTING CLINICAL SIGNS**

Presented for annual health exam with no concerns. Noted abnormal appearance to umbilical hernia and distended abdomen. Initial FAST scan indicated suspect mass in cranial abdomen. Suspect mets noted on chest rads but cannot rule out superimposition/age related changes.

Abnormal PE/Chem/CBC/UA Results: Mod elevation in globulins and albumin. TBIL 34 H O - 15 µmol/L

**ULTRASONOGRAPHIC EXAMINATION OF THE ABDOMEN**

**Urinary System**

The **bladder** in this patient was mildly thickened with slight echogenic mural changes. No calculi or masses were noted. Slight micropolypoid changes were noted. This is a frequent finding in older animals and may be linked to a history of chronic urinary tract infection or active urinary tract infection. Urinalysis would be recommended with culture if any evidence of inflammatory sediment is present. The region of the trigone and visible pelvic urethra were normal. This is a mild change. The pelvic urethra was imaged 3.0 cm beyond the cystourethral junction.

The **kidneys** revealed largely normal size and structure, corticomedullary definition and ratio (cortex 1/3 of medulla) were essentially maintained with some minor age-related loss of curvilinear patterns regarding the capsule and C/M junction. The cortices presented largely uniform texture with some increased echogenicity expected for his age patient. Medullary structure differed distinctly from that of the cortex and no evidence of pelvic dilation was present. Slight pinpoint mineralization noted. The right kidney measured 5.0 cm. The left kidney measured 5.0 cm.

**Adrenal Glands**

Both **adrenal glands** were visualized and recognized as having normal shape, size, position and echogenicity for this breed. The phrenic vasculature, glandular echogenicity and detail were unremarkable. Capsule, cortex, and medullary definition were normal for this age patient. The left adrenal gland measured 0.4 cm.

**Spleen**

The **spleen** revealed a focal hypoechoic nodule, measuring 0.67 cm, with some disruption of architecture. The remainder of the spleen was unremarkable, other than minor remodeling.

**Liver**

The **liver** revealed multifocal hyperechoic nodules, consistent with lipogranulomas. Minor increased portal markings noted. The left medial liver revealed a complex mixed echogenic and necrotic/cystic mass, impinging upon the portal hilus and gallbladder. The mass is possibly resectable given its position; however, significant inflammation is noted around the mass. The mass measured approximately 4.5 cm. CT evaluation for surgical planning, as well as FNA of the parenchymal portion of the mass and drainage of the cystic portions with culture. Free fluid noted around the mass, which would suggest for rupture or leakage.

**Gastrointestinal**



**PATIENT**

Bebe Chen

Examination of the **gastrointestinal tract** revealed a stomach and intestine free of stasis, of normal wall thickness, acceptable curvilinear mural detail, and peristaltic activity. Small and large intestine demonstrated normal luminal chyme and stool consistency respectively. No obstructive or overt infiltrative disease was noted. No associated abnormal lymphatic activity was noted.

**SPECIES**

Canine

**Pancreas**

The base and limbs of the **pancreas** were observed to be largely isoechoic to surrounding omental fat. Pancreatic duct and capsular contour were acceptably normal and parenchyma respected normal curvilinear patterns. No overt evidence of active inflammatory or neoplastic disease was noted.

**BREED**

Miniature Poodle

**ULTRASONOGRAPHIC FINDINGS**

**SEX**

Neutered male

- Splenic nodule and remodeling
- Inflamed, possible ruptured hepatic mass, suspect carcinoma, possibility of nonneoplastic abscessation (less likely).
- Age-related urinary bladder changes
- Age-related renal changes with slight mineralization

**AGE**

9 years

**INTERPRETATION OF THE FINDINGS & FURTHER RECOMMENDATIONS**

Regarding the liver mass, CT evaluation for surgical planning, as well as FNA of the parenchymal portion of the mass and drainage of the cystic portions with culture. Abscessation granuloma possible yet less likely. Other nodular changes in the liver may be related to the primary mass. If CT is not available, direct exploratory surgery could be considered given the free fluid around the mass to attempt to resect, however, clean resection may be difficult or not possible given the impingement upon the portal hilus.

**WEIGHT**

12.1 lbs

**INTERPRETED BY**

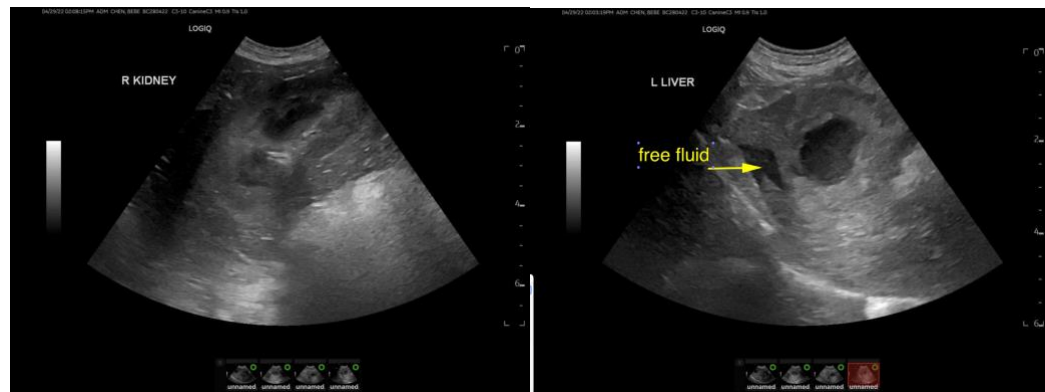Eric Lindquist, DMV  
DABVP, Cert. IVUSS

**IMAGING PERFORMED BY**

Evan Bell

**HOSPITAL NAME**

Cedarview AH



**REFERRING VET**

Kim Holzman

**INVOICE**

14964

**DATE**

4/29/22



**PATIENT**

Bebe Chen

**SPECIES**

Canine

**BREED**

Miniature Poodle

**SEX**

Neutered male

**AGE**

9 years

**WEIGHT**

12.1 lbs

**INTERPRETED BY**

Eric Lindquist, DMV  
DABVP, Cert. IVUSS

**IMAGING PERFORMED BY**

Evan Bell

**HOSPITAL NAME**

Cedarview AH

**REFERRING VET**

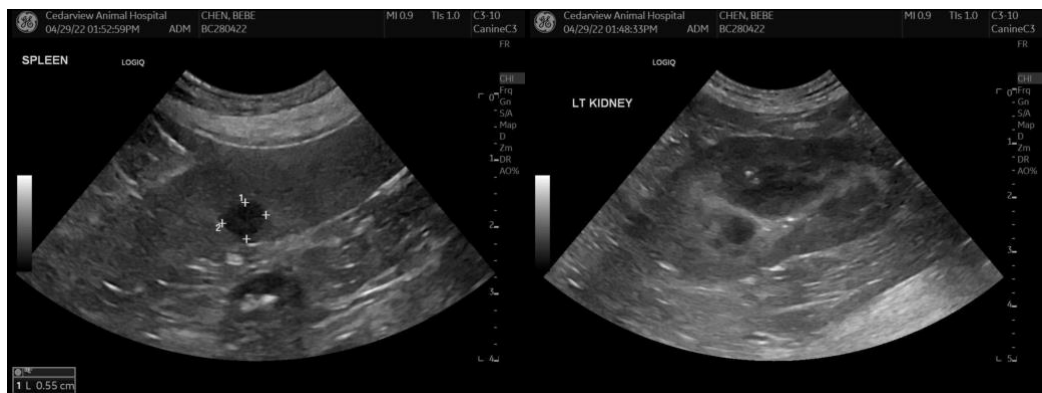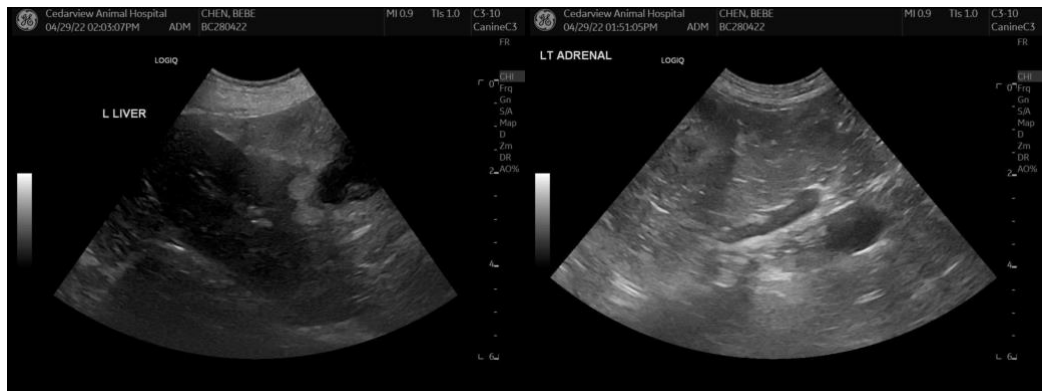
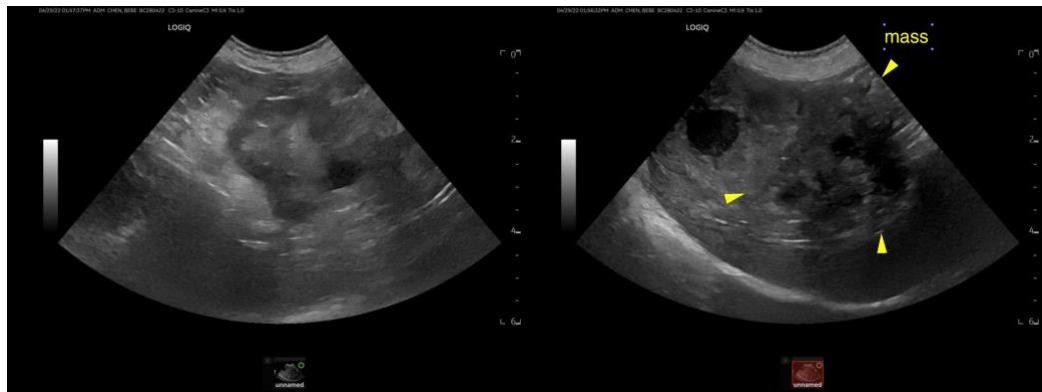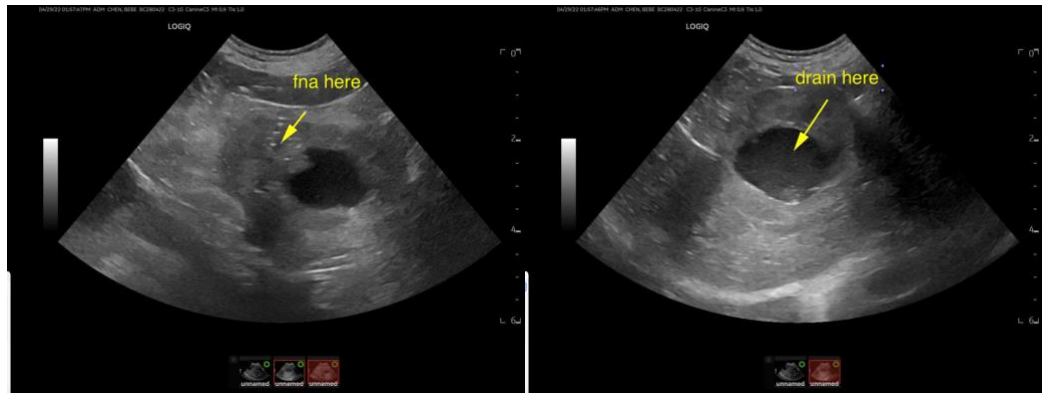
Kim Holzman

**INVOICE**

14964

**DATE**

4/29/22





**PATIENT**

Bebe Chen

The information and recommendations provided are based on the images presented by the referring veterinarian/sonographer. No evaluation can be communicated regarding pathology that was not visible in the image/video clips provided.

**SPECIES**

Canine

Thank you for this referral. If the clinical or image interpretation does not parallel your findings or if I can be of any further assistance please contact me.

**BREED**

Miniature Poodle

Eric Lindquist, DMV, DABVP, Cert. IVUSS, CEO of SonoPath.com

[info@SonoPath.com](mailto:info@SonoPath.com)

**SEX**

Neutered male

**Hepatic Masses, Biliary Adenoma, and Biliary Adenocarcinoma**

<http://www.sonopath.com/HepaticMasses>

**AGE**

9 years

**Description:** Hepatocellular carcinoma typically manifests in the liver's left lateral lobes, yet may cross over to the right lobes should it derive from the hilus. These masses often present cavitating, necrotic cores that are difficult to distinguish from hepatic abscesses. Vascular channels may also be involved, and bile duct obstruction is often present. Older felines often present solitary or multiple fluid-filled cysts within the hepatic parenchyma. The latter are typically benign cystadenomas and should be differentiated from: cystic adenocarcinoma; hepatic lymphoma (usually diffusely hyperechoic +/- FIV/FelV association); metastatic neoplasia (diffuse hyper- to hypoechoic nodules secondary to mammary adenocarcinoma, splenic hemangiosarcoma, or pancreatic or intestinal adenocarcinoma); benign nodular hyperplasia (accompanied by minimal to no symptoms); hepatic cirrhosis (regenerative nodules); or rare carcinoids, fibrosarcomas, leiomyosarcomas, and osteosarcomas.

**WEIGHT**

12.1 lbs

**INTERPRETED BY**

Eric Lindquist, DMV  
DABVP, Cert. IVUSS

**IMAGING PERFORMED BY**

Evan Bell

**Clinical Signs:** Possible clinical signs and physical exam findings include cranial abdominal organomegaly, sudden collapse associated with mass rupture, vomiting, ascites, jaundice (severe cases), and hypoglycemia secondary to a paraneoplastic syndrome. Sepsis and fever associated with secondary abscessation of the mass may also occur. Cats usually present with anorexia and lethargy.

**HOSPITAL NAME**

Cedarview AH

**Diagnostics:** Routine biochemical analysis primarily shows liver enzyme elevation (i.e., ALT for cellular necrosis; SAP for hepatic congestion; elevated bilirubin for stasis/obstruction; bile acids > 75-100uM/L for significant function impairment). Staging of the disease with 3-view thoracic radiographs is essential, as is conducting a CBC, serum biochemistry, urinalysis, as well as abdominal and possibly also thoracic ultrasounds in order to provide the owner with adequate and well-informed options. Surgical and oncological referral is recommended after a coagulation panel has been assessed and ultrasound-guided biopsies of both normal and pathological tissue have been performed such that the disease is adequately characterized. In cases where surgical resection is impossible, direct chemoembolization of the tumor blood supply could be considered; however, this procedure is only performed at specific tertiary referral locations. Placement of palliative stents into the caudal vena cava (CVC) can be considered as well if compression by an unresectable tumor causes excessive ascitic fluid accumulation. Serum alpha-fetoprotein (AFP) has

**REFERRING VET**

Kim Holzman

**INVOICE**

14964

**DATE**

4/29/22



**PATIENT**

Bebe Chen

**SPECIES**

Canine

**BREED**

Miniature Poodle

**SEX**

Neutered male

**AGE**

9 years

**WEIGHT**

12.1 lbs

**INTERPRETED BY**

Eric Lindquist, DMV  
DABVP, Cert. IVUSS

**IMAGING PERFORMED BY**

Evan Bell

**HOSPITAL NAME**

Cedarview AH

**REFERRING VET**

Kim Holzman

**INVOICE**

14964

**DATE**

4/29/22

been shown to reemerge in dogs with malignant hepatobiliary adenocarcinoma. Ultrasound is important to localize the mass in relation to the portal hilus and gallbladder. The portal vein, CVC, aorta, gallbladder, and bile duct should all be identified with respect to the location of the mass to determine resectability. Ultrasound also allows for an examination of possible metastatic sites in the abdomen and, to some degree, in the thorax.

**Treatment:** Hepatic adenoma, hepatoma, and adenocarcinoma are usually amenable to surgical resection via hepatic lobectomy should the pathology be isolated to single-lobe progression. Multi-lobar presentation may be amenable to lobectomy and debulking; this will be determined further during surgical consultation. These tumors tend to displace unaffected parenchyma, allowing for relatively straightforward surgical resection. Up to 80% of the liver can be removed without long-term functional deficits. Blood transfusions may be necessary during surgery. The development and implementation of the LDS™ stapler has helped to streamline the procedure. Most carcinomas have metastasized by the time of diagnosis yet tend to be slow-growing; thus, it may be possible for a certain quality of life to be attained via surgical resection. Hepatic hemangiosarcoma has usually metastasized at the time of diagnosis and carries a much poorer prognosis. Surgical resection and chemotherapy are recommended, but considered by many to be an “aggressive” approach.

Preliminary trials have shown that gemcitabine is well tolerated and yields good responses in cases of hepatic as well as pancreatic, colonic, and gastric carcinomas. Myelosuppression, however, remains the key issue. Doxorubicin, cyclophosphamide, and fluorouracil combinations have also proven fruitful.

Nonsteroidal anti-inflammatory drugs (NSAIDs) have been demonstrated to have an anti-neoplastic effect due to their inhibition of COX-2 in certain tumor cells. The end product of the cyclooxygenase cascade is prostaglandin E2, which, when expressed in tumor cell lines—and not expressed in normal cells of that particular cell line—results in inhibited apoptosis, immunosuppression, and increased angiogenesis, proliferation, and invasiveness. Inappropriate increases in COX-2 expression have been documented in certain neoplasias, including squamous cell carcinoma, mammary carcinomas, prostatic carcinoma, malignant melanoma, and transitional cell carcinoma.

Metronomic chemotherapy is currently being investigated and compared to traditional chemotherapy protocols; it is thought to be at least as effective as the latter with substantially less toxic side effects. Metronomic chemotherapy is the practice of uninterrupted administration of low-dose cytotoxic drugs at regular and frequent intervals, as opposed to high-dose, shorter-term protocols characteristic of traditional chemotherapeutic practices. The lower dose allows for long-term administration without toxic side effects, and has been postulated as providing longer remission intervals. Moreover, it has the benefit of minimizing the intervals between drug regimens—the period during which tumor cells may repopulate the area—as well as the chance of developing multi-drug resistant genes. Metronomic chemotherapy has been used successfully in human patients who have undergone previous chemotherapy administration. It is thought to destroy endothelial cells, thereby retarding angiogenesis and targeting regulatory T cells. To date, there have only been a few small clinical trials in veterinary patients, and these have focused on animals that have hemangiosarcoma and soft tissue sarcomas.



**PATIENT**

Bebe Chen

**Conclusion:** With respect to hepatic neoplasia, many surgical and chemotherapeutic options exist; however, it is best to consult with a local board certified oncologist who can help determine the best course of action.

**SPECIES**

Canine

**References:**

Biller BJ. Teaching T cells to target tumors: towards the design of more effective cancer vaccines. Proceedings from the American College of Veterinary Internal Medicine Forum, Denver, CO, June 15-18, 2011.

**BREED**

Miniature Poodle

**SEX**

Neutered male

Biller BJ, Guth A, Burton JH, Dow SW. Decreased ratio of CD8+ T cells to regulatory T cells associated with decreased survival in dogs with osteosarcoma. *J Vet Intern Med* 2010;24(5):1118-23.

**AGE**

9 years

Elmslie RE, Glawe P, Dow SW. Metronomic therapy with cyclophosphamide and piroxicam effectively delays tumor recurrence in dogs with incompletely resected soft tissue sarcomas. *J Vet Intern Med* 2008;22(6):1373-79.

**WEIGHT**

12.1 lbs

Lana S, U'Ren L, Plaza S, et al. Continuous low-dose oral chemotherapy for adjuvant therapy of splenic hemangiosarcoma in dogs. *J Vet Intern Med* 2007;21(4):764-69.

**INTERPRETED BY**

Eric Lindquist, DMV  
DABVP, Cert. IVUSS

Milner RJ. Do NSAIDs make a difference in cancer? Proceedings from the American College of Veterinary Internal Medicine Forum, Denver, CO, June 15-18, 2011.

**IMAGING PERFORMED BY**

Evan Bell

**HOSPITAL NAME**

Cedarview AH

**REFERRING VET**

Kim Holzman

**INVOICE**

14964

**DATE**

4/29/22