



PATIENT

Tatiana Tritto

SPECIES

Canine

BREED

Black Mouth Curr

SEX

Spayed female

AGE

7 years

WEIGHT

81.2 lbs

INTERPRETED BY

Eric Lindquist, DMV
DABVP, Cert. IVUSS

IMAGING PERFORMED BY

Dr. Cecelia Fisher

HOSPITAL NAME

Cape Coral Pet Vet

REFERRING VET

Dr. Vickers

INVOICE

74924

DATE

4/28/26

PRESENTING CLINICAL SIGNS

History: ALT and ALP remain elevated.

ULTRASONOGRAPHIC EXAMINATION OF THE ABDOMEN

Urinary System

The **urinary bladder**, trigone, and pelvic urethra presented normal thicknesses and normal tone. The ureters were not visible which is normal. A minor amount of sand accumulation was noted and measured up to 2.1 cm. No evidence of inflammatory or neoplastic changes was noted. Ureteral papillae were normal.

The **kidneys** revealed normal size and structure, corticomedullary definition and ratio for this age. The cortices presented largely uniform texture with normal echogenic relationship to liver and spleen. Medullary structure differed distinctly from the cortex and no evidence of pelvic dilation was present. The capsules were acceptably uniform without significant irregularities. The left kidney measured 7.6 cm. The right kidney measured 7.6 cm.

Adrenal Glands

The **adrenal glands** were not visualized.

Spleen

The **spleen** in this patient was mildly enlarged with uniform parenchyma and was folded upon itself cranially. This is a positional variant and is not pathological. There was no evidence of significant disease.

Liver

The **liver** images submitted revealed subjectively normal liver size, contour, and structure. Parenchymal echogenicity was naturally coarse and hypoechoic to the spleen. Vascular and biliary tracts were of normal volume with no evidence of congestion. The gallbladder presented acceptably thin walls with primarily anechoic content. The cystic and common bile ducts were normal. No pathological hepatic lymphadenopathy was evident. No overt structural evidence of inflammatory, infiltrative or regenerative pathology was evident.

Gastrointestinal

Examination of the **gastrointestinal tract** revealed a stomach and intestine free of stasis, of normal wall thickness, acceptable curvilinear mural detail, and peristaltic activity. Small and large intestine demonstrated normal luminal chyme and stool consistency respectively. No obstructive or overt infiltrative disease was noted. No associated abnormal lymphatic activity was noted.



PATIENT

Tatiana Tritto

SPECIES

Canine

BREED

Black Mouth Curr

SEX

Spayed female

AGE

7 years

WEIGHT

81.2 lbs

INTERPRETED BY

Eric Lindquist, DMV
DABVP, Cert. IVUSS

IMAGING PERFORMED BY

Dr. Cecelia Fisher

HOSPITAL NAME

Cape Coral Pet Vet

REFERRING VET

Dr. Vickers

INVOICE

74924

DATE

4/28/26

Pancreas

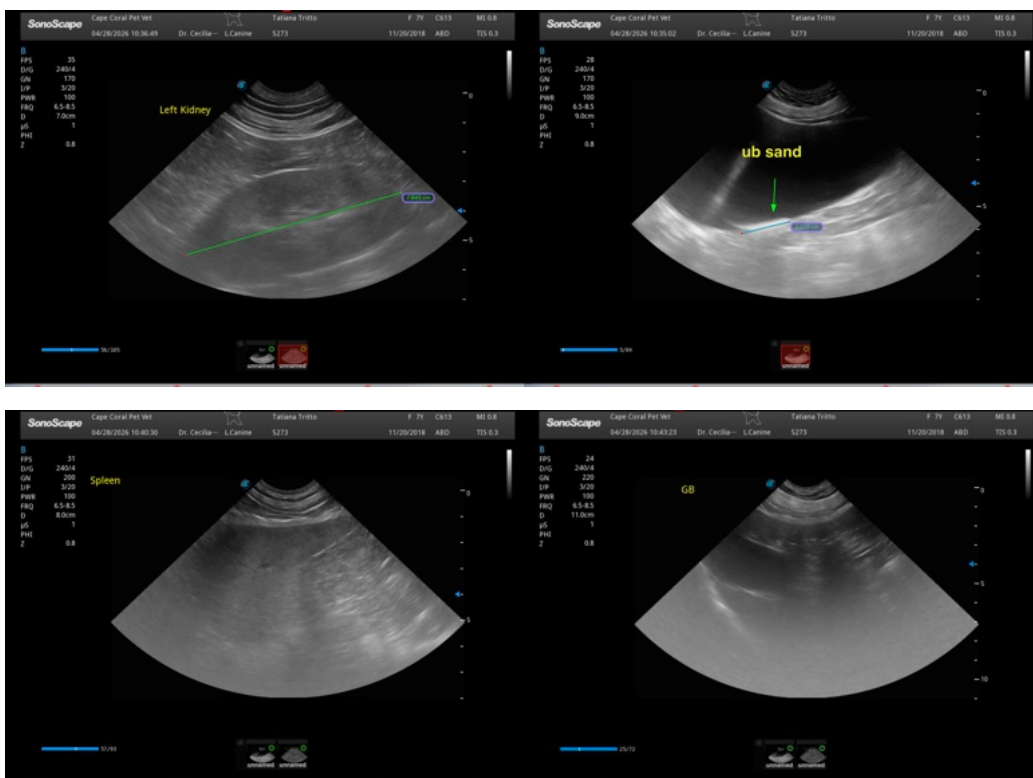
The base and limbs of the **pancreas** were observed to be largely isoechoic to surrounding omental fat. Pancreatic duct and capsular contour were acceptably normal and parenchyma respected normal curvilinear patterns. No overt evidence of active inflammatory or neoplastic disease was noted.

ULTRASONOGRAPHIC FINDINGS

Structurally unremarkable abdomen.

INTERPRETATION OF THE FINDINGS & FURTHER RECOMMENDATIONS

There was no gross pathology. FNA of the liver is warranted for further definition given the liver enzyme elevations even though there is no evidence of gross pathology associated with the liver or other organs.





PATIENT

Tatiana Tritto

SPECIES

Canine

BREED

Black Mouth Curr

SEX

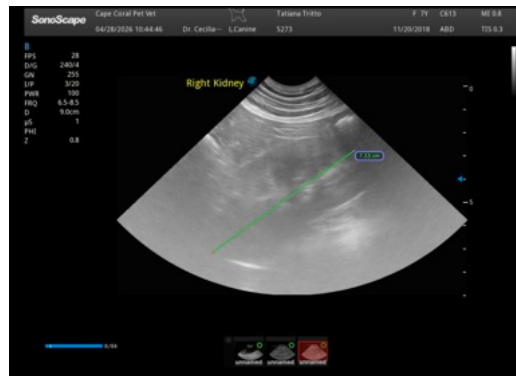
Spayed female

AGE

7 years

WEIGHT

81.2 lbs



The information and recommendations provided are based on the images presented by the referring veterinarian/sonographer. No evaluation can be communicated regarding pathology that was not visible in the image/video clips provided.

Thank you for this referral. If the clinical or image interpretation does not parallel your findings or if I can be of any further assistance please contact me.

Eric Lindquist, DMV, DABVP (CFM), Cert. IVUSS, CEO of SonoPath.com

info@SonoPath.com

INTERPRETED BY

Eric Lindquist, DMV
DABVP, Cert. IVUSS

IMAGING PERFORMED BY

Dr. Cecelia Fisher

HOSPITAL NAME

Cape Coral Pet Vet

REFERRING VET

Dr. Vickers

INVOICE

74924

DATE

4/28/26