

SonoPath www.carolinavetmobile.com
info@carolinavetmobile.com 800.808.5948

PATIENT

Stella James

SPECIES

Feline

BREED

DMH

SEX

Spayed Female

AGE

15.6 Years

WEIGHT

10.52

INTERPRETED BY

Eric Lindquist, DMV, DABVP (CFM), Cert. IVUSS

IMAGING PERFORMED BY

Ginny Dodd, DVM, D, ABVP-CFP

HOSPITAL NAME

Paws & Claws Mobile Vet

REFERRING VET

Dr. Lindy Marshall

INVOICE

74788

DATE

4/28/26

PRESENTING CLINICAL SIGNS

Normal appetite by chronic weight loss; periodontal disease- mild

Abnormal PE/Chem/CBC/UA Results: PE: Ht and lungs normal, abdomen appears swollen CBC- WBC- 25,670; N 18,730; mono 2,009 CHEM- SDMA 19; creat 1.9 N, BUN 51^

ULTRASONOGRAPHIC EXAMINATION OF THE ABDOMEN

Urinary System

The **urinary bladder**, trigone, and pelvic urethra presented normal thicknesses and normal tone. The ureters were not visible which is normal. No uroliths or sediment were visualized and anechoic urine was present. No evidence of inflammatory or neoplastic changes were noted. Ureteral papillae were normal.

The **kidneys** revealed largely normal size and structure, corticomedullary definition and ratio (cortex 1/3 of medulla) were essentially maintained with some age-related loss of curvilinear patterns regarding the capsule and C/M junction. The cortices presented largely uniform texture with some increased echogenicity expected for his age patient. Medullary structure differed distinctly from that of the cortex. The right kidney presented a 0.66 cm calculus with pyelectasia. The right kidney measured 3.5 cm. The left kidney measured 3.2 cm.

Adrenal Glands

Both **adrenal glands** were visualized and recognized as having normal shape, size, position and echogenicity for this breed. The phrenic vasculature, glandular echogenicity and detail were unremarkable. Capsule, cortex, and medullary definition were normal for this age patient. The adrenals measured 0.40 cm each.

Spleen

The **spleen** was mildly enlarged with slight scalloping contour.

Liver

The **liver** images from right and left intercostal as well as subcostal views revealed subjectively normal liver size, contour, and structure. Some age-related parenchymal remodeling was noted but likely not clinically significant at this time. Vascular and biliary tracts were of normal volume and no evidence of congestion was noted. The gallbladder presented some dependent debris with essentially normal contour. The cystic and common bile ducts were normal. No overt evidence of active inflammatory, infiltrative or regenerative pathology was noted but should be paired with current or past LE elevations regarding any clinical significance to this presentation. The hepatic lymph nodes were unremarkable.

Gastrointestinal

Examination of the **gastrointestinal tract** revealed a stomach and intestine free of stasis, of normal wall thickness, acceptable curvilinear mural detail, and peristaltic activity. Small and large intestine demonstrated normal luminal chyme and stool consistency respectively. No obstructive or overt infiltrative disease was noted. No associated abnormal lymphatic activity was noted.

PATIENT

Stella James

SPECIES

Feline

BREED

DMH

SEX

Spayed Female

AGE

15.6 Years

WEIGHT

10.52

INTERPRETED BY

Eric Lindquist, DMV, DABVP (CFM), Cert. IVUSS

IMAGING PERFORMED BY

Ginny Dodd, DVM, D, ABVP-CFP

HOSPITAL NAME

Paws & Claws Mobile Vet

REFERRING VET

Dr. Lindy Marshall

INVOICE

74788

DATE

4/28/26

Pancreas

The base and limbs of the **pancreas** were observed to be largely isoechoic to surrounding omental fat. Pancreatic duct and capsular contour were acceptably normal and parenchyma respected normal curvilinear patterns. No overt evidence of active inflammatory or neoplastic disease was noted.

Free Abdomen

The omentum presented coalescing hypoechoic nodular changes throughout the abdomen.

Moderate amount of ascites noted throughout the abdomen.

Pleural effusion also noted.

ULTRASONOGRAPHIC FINDINGS

- Mildly enlarged, scalloped spleen.
- Age related renal and hepatic changes.
- Nodular omentum.
- Abdominal ascites and pleural effusion.

INTERPRETATION OF THE FINDINGS & FURTHER RECOMMENDATIONS

Ultrasound guided FNA of the spleen, abdominocentesis and cytospin of the free fluid indicated. Recommend a rapid echocardiogram to ensure cardiac disease or cause of passive congestion are not an issue. Even though the hepatic veins do not appear grossly overdistended, I cannot completely rule out passive congestion pathology. Prognosis is guarded to poor depending upon cytology results and thoracic ultrasound. Carcinomatosis, lymphomatosis, mastocytosis or similar can all present in this fashion. Occasionally wet form FIP, yet given the age of this patient this is unlikely. Mild potential for thoracic disease with passive congestion.

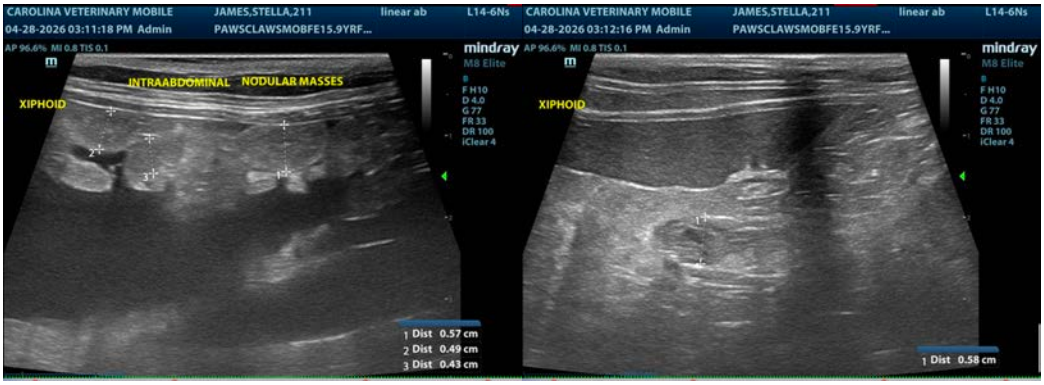

Carolina Veterinary Mobile
FUELED BY SONOPATH VETERINARY ULTRASOUND

SonoPath
www.carolinavetmobile.com
info@carolinavetmobile.com
800.808.5948



Clinical Sonography & Telecytology
Educational Teleconsultation Services™

PATIENT

Stella James

SPECIES

Feline

BREED

DMH

SEX

Spayed Female

AGE

15.6 Years

WEIGHT

10.52

INTERPRETED BY

Eric Lindquist, DMV, DABVP (CFM), Cert. IVUSS

IMAGING PERFORMED BY

Ginny Dodd, DVM, D, ABVP-CFP

HOSPITAL NAME

Paws & Claws Mobile Vet

REFERRING VET

Dr. Lindy Marshall

INVOICE

74788

DATE

4/28/26

The information and recommendations provided are based on the images presented by the referring veterinarian/sonographer. No evaluation can be communicated regarding pathology that was not visible in the image/video clips provided.

Thank you for this referral. If the clinical or image interpretation does not parallel your findings or if I can be of any further assistance please contact me.

Eric Lindquist, DMV, DABVP(CFM), Cert. IVUSS,
CEO, Owner, Founder -- SonoPath.com
info@SonoPath.com