



**DATE PRESENTING CLINICAL SIGNS**

4/28/26 Patient History: Patient had anesthetic procedure on Friday (a urinary catheter was placed to ensure patient was not blocked). Now not eating, urinating, or defecating. Hard abdomen and not very painful.

**PATIENT**

Rowan Bowers  
Current Medications: Apoquel 16 mg 1/2 tab po q12h  
Labwork Results: Labwork attached, reported as: elevated white count  
Date of Previous IntraPet Ultrasound: No previous.  
Sedation: Not required to complete full diagnostic ultrasound.  
Stat Report: STAT report & Echo declined.  
Imaging Performed by: Stephanie Warga RDCS, RVT.

**SPECIES**

Feline

**BREED**

DSH

**SEX**

Neutered Male

**AGE**

1/15/18

**WEIGHT**

22.3 Pounds

**INTERPRETED BY**

Eric Lindquist, DMV,  
DABVP (CFM), Cert.  
IVUSS

**HOSPITAL NAME**

Madonna VC

**REFERRING VET**

Dr. Brockett

**INVOICE**

36870

**ULTRASONOGRAPHIC EXAMINATION OF THE ABDOMEN**

**Urinary System**

The **urinary bladder**, trigone, and pelvic urethra presented normal thicknesses and normal tone. The ureters were not visible which is normal. No uroliths or sediment were visualized and anechoic urine was present. No evidence of inflammatory or neoplastic changes were noted. Ureteral papillae were normal. The bladder was minimally repleted.

The **kidneys** revealed largely normal size and structure, corticomedullary definition and ratio (cortex 1/3 of medulla) were essentially maintained with some mild age-related loss of curvilinear patterns regarding the capsule and C/M junction. The cortices presented largely uniform texture with some increased echogenicity expected for this age patient. Medullary structure differed distinctly from that of the cortex, and no evidence of pelvic dilation was present. The right kidney measured 4.82 cm. The left kidney measured 4.8 cm.

**Adrenal Glands**

The regions of the **adrenal glands** revealed no evident pathology.

**Spleen**

The **spleen** presented a smooth homogeneous parenchyma hyperechoic to liver and renal cortical parenchyma. The capsule was smooth without noticeable expansion or deviation from within the spleen or adjacent pathology. The splenic vasculature demonstrated normal volume without signs of congestion or thrombosis. No sonographic evidence of acute or chronic inflammatory, neoplastic, or infarctual changes were noted.

**Liver**

The **liver** images submitted revealed subjectively normal liver size, contour, and structure. Parenchymal echogenicity was naturally coarse and hypoechoic to the spleen. Vascular and biliary tracts were of normal volume with no evidence of congestion. The gallbladder and common bile duct were unremarkable. The hepatic veins were not dilated. No evidence of passive congestion

**Gastrointestinal**

Examination of the **gastrointestinal tract** revealed a stomach and intestine free of stasis, of normal wall thickness, acceptable curvilinear mural detail, and peristaltic activity. Small and large intestine demonstrated normal luminal chyme and stool consistency respectively. No obstructive or overt infiltrative disease was noted. No associated abnormal lymphatic activity was noted.

### ***Pancreas***

The base and limbs of the **pancreas** were observed to be largely isoechoic to surrounding omental fat. Pancreatic duct and capsular contour were acceptably normal and parenchyma respected normal curvilinear patterns. No overt evidence of active inflammatory or neoplastic disease was noted.

### ***Free Abdomen***

A large amount of anechoic **ascites** was noted in the abdomen in this patient. Mild heterogeneous omental changes were noted, but no overt mass was present.

### ***Other***

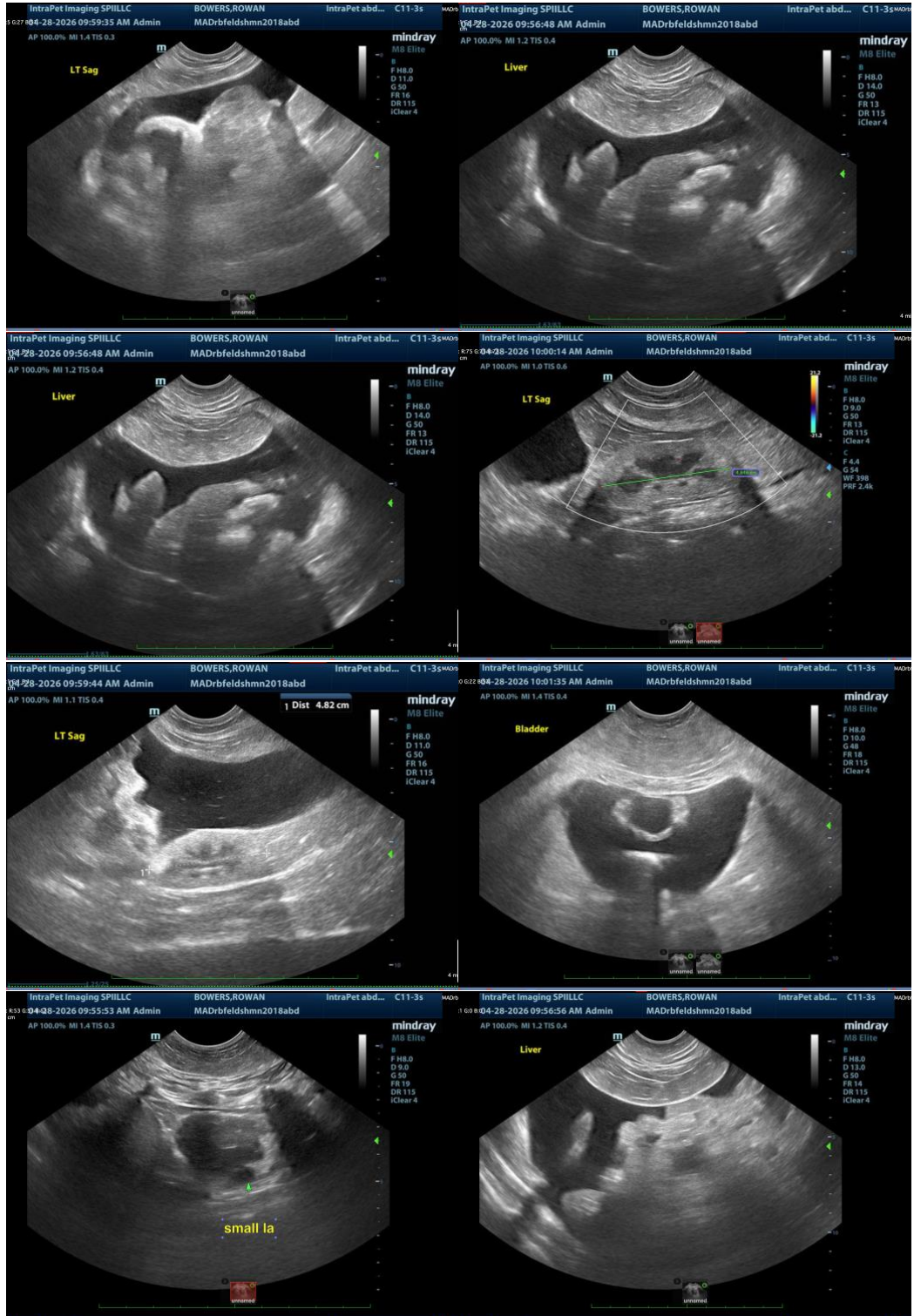A rapid view of the **heart** revealed no evident pathology, other than volume contraction. A large amount of thoracic fat was noted.

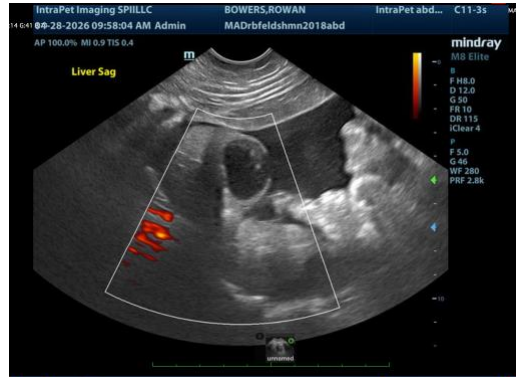
## **ULTRASONOGRAPHIC FINDINGS**

- Ascites of unknown origin
- Mild heterogeneous omental changes
- Volume contracted heart
- Mild age-related renal changes
- Large amount of thoracic fat

## **INTERPRETATION OF THE FINDINGS & FURTHER RECOMMENDATIONS**

The bladder was minimally repleted. Cannot rule out a rent in the bladder. If the bladder is not filling on a follow-up ultrasound, then saline infusion is recommended while performing the ultrasound to assess for any leakage. Carcinomatosis or lymphomatosis are entirely possible in this patient. Cytospin of the free fluid is recommended to assess for any exfoliating neoplasia versus an inflammatory event. FIP is a minor potential. Volume expansion is recommended in this patient as intravascularly the patient is volume depleted, as there is a large amount of third spacing of fluid into the abdomen.





**The information and recommendations provided are based on the images presented by the referring veterinarian/sonographer. No evaluation can be communicated regarding pathology that was not visible in the image/video clips provided.**

Thank you for this referral. If the clinical or image interpretation does not parallel your findings or if I can be of any further assistance please contact me.

**Eric Lindquist**, DMV, DABVP(CFM), Cert. IVUSS,  
CEO, Owner, Founder -- SonoPath.com  
[info@SonoPath.com](mailto:info@SonoPath.com)