



PATIENT

Montana Al Thani

SPECIES

Feline

BREED

British Longhair

SEX

Female

AGE

12 months

WEIGHT

2.7 lbs

INTERPRETED BY

Eric Lindquist, DMV
DABVP, Cert. IVUSS

IMAGING PERFORMED BY

Dr. Khan

HOSPITAL NAME

The Veterinary
Surgery- Street 805

REFERRING VET

Dr. Khan

INVOICE

74900

DATE

4/28/26

PRESENTING CLINICAL SIGNS

History: Pregnant 1 year old very tiny British short hair pure breed, came in for an ultrasound exam and got stressed and cam back salivating open mouth breathing, just want to rule out cardiac problems as there lot of cardiac problems in these pure inbred cats

ULTRASONOGRAPHIC EXAMINATION OF THE HEART

The cardiac presentation in this patient revealed normal septal and free wall thicknesses as well as normal internal diameter and contractility.

FELINE CARDIAC PARAMETERS	BODY WEIGHT	HR (BPM)	IVSd (cm)	LVIDd (cm)	LVWd (cm)	FS (%)	EF (%)
NORMAL PARAMETER	-----	150-240	0.3-0.6	1.0-2.1	0.25-0.6	35-67	80-100
PATIENT	2.7 lbs	220	0.35	1.1	0.38	50	90
FELINE CARDIAC PARAMETERS	LA/AO (M-mode)	LA/AO HEART BASE (Sisson)	LAD LA MAX 4 Chamber		LVOT VEL. (m/s)	RVOT VEL. (m/s)	IVRT (m/)
NORMAL PARAMETER	<1.5	1.6	0.7-1.7		<1.6	<1.3	40-60
PATIENT	1.1	1.1	1.3		NM	NM	NM
Adapted from June Boon, Veterinary Echocardiography, 1998 Sisson D et al. JVIM 1991; 5: 232, Jacobs et al. Am J Vet Res 1985; 46:1705							

ULTRASONOGRAPHIC FINDINGS

Normal echocardiogram, no evidence of primary cardiac disease responsible for the clinical signs.

INTERPRETATION OF THE FINDINGS & FURTHER RECOMMENDATIONS

No specific therapy is recommended at this time.



PATIENT

Montana Al Thani

SPECIES

Feline

BREED

British Longhair

SEX

Female

AGE

12 months

WEIGHT

2.7 lbs

INTERPRETED BY

Eric Lindquist, DMV
DABVP, Cert. IVUSS

IMAGING PERFORMED BY

Dr. Khan

HOSPITAL NAME

The Veterinary
Surgery- Street 805

REFERRING VET

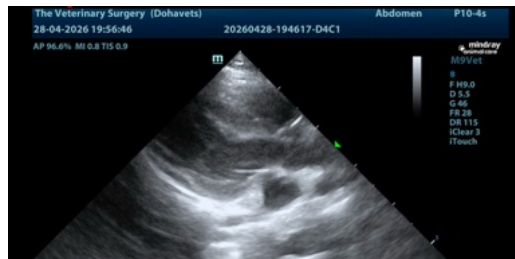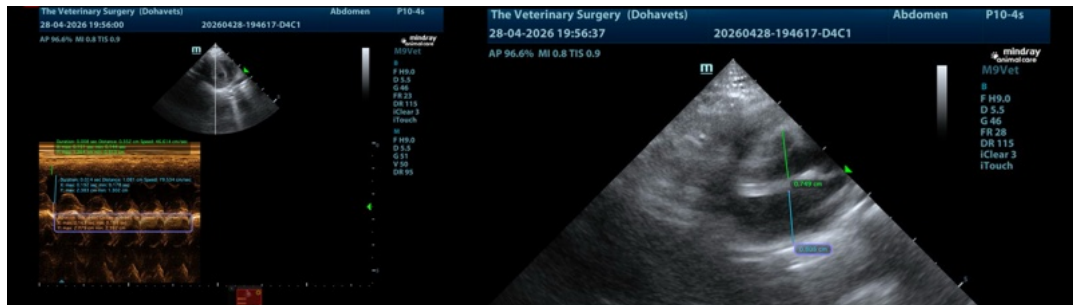
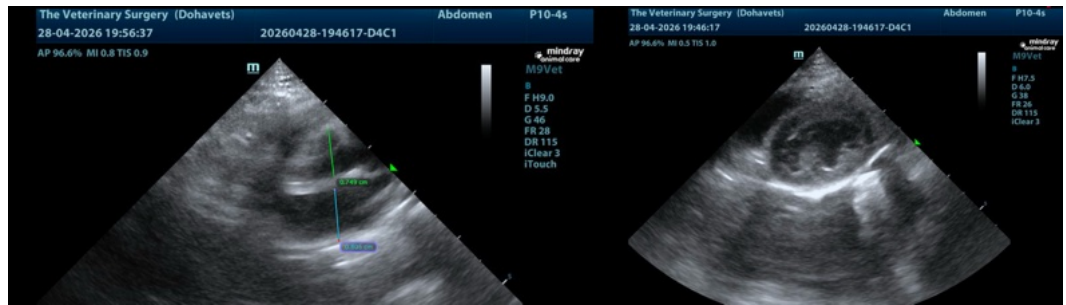Dr. Khan

INVOICE

74900

DATE

4/28/26



The information and recommendations provided are based on the images presented by the referring veterinarian/sonographer. No evaluation can be communicated regarding pathology that was not visible in the image/video clips provided.

Thank you for this referral. If the clinical or image interpretation does not parallel your findings or if I can be of any further assistance please contact me.

Eric Lindquist, DMV, DABVP (CFM), Cert. IVUSS, CEO of SonoPath.com

info@SonoPath.com