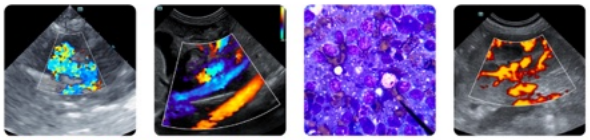

PATIENT
Lennon Petersen

SPECIES
Feline

BREED
Bengal

SEX
Spayed female

AGE
4 years

WEIGHT
7.1 lbs

INTERPRETED BY
Eric Lindquist, DMV
DABVP, Cert. IVUSS

IMAGING PERFORMED BY
Dr. Cochran

HOSPITAL NAME
Millis AH

REFERRING VET
Dr. Cochran

INVOICE
74955

DATE
4/28/26

PRESENTING CLINICAL SIGNS

History: Spayed female Bengal, history of lethargy for the past 12-14 months. She is on Fluoxetine for inappropriate urination, 5 mg PO SID. She is eating less, and is lethargic, owner reports decreased playfulness and grooming, excessive sleeping. She has lost weight (1.5 lb, approx 18% of body weight) in the past year.
Abnormal PE/Chem/CBC/UA Results: WBC 21 K TP 10.1 Albumin 2.3 Globulin 7.8 Urine protein 1+ All else normal, T4 normal, USG normal Negative bence jones protein in urine triple snap test (FeLV/FIV/HW) all negative

ULTRASONOGRAPHIC EXAMINATION OF THE ABDOMEN

Urinary System

The **urinary bladder**, trigone, and pelvic urethra presented normal thicknesses and normal tone. The ureters were not visible which is normal. No uroliths or sediment were visualized and anechoic urine was present. No evidence of inflammatory or neoplastic changes was noted. Ureteral papillae were normal.

The **kidneys** were irregular with loss of mural detail. Pericapsular fluid accumulation was noted. Thickened irregular cortices were noted with loss of corticomedullary definition. The left kidney was enlarged and measured 4.2 cm. The right kidney was normal in size and measured 3.2 cm.

Adrenal Glands

Both **adrenal glands** were visualized and recognized as having normal shape, size, position and echogenicity for this breed. The phrenic vasculature, glandular echogenicity and detail were unremarkable. Capsule, cortex, and medullary definition were normal for this age patient.

Spleen

The **spleen** was enlarged and measured 1.7 cm.

Liver

The **liver** images submitted revealed subjectively normal liver size, contour, and structure. Parenchymal echogenicity was naturally coarse and hypoechoic to the spleen. Vascular and biliary tracts were of normal volume with no evidence of congestion. The gallbladder presented acceptably thin walls with primarily anechoic content. The cystic and common bile ducts were normal. No pathological hepatic lymphadenopathy was evident. No overt structural evidence of inflammatory, infiltrative or regenerative pathology was evident.

PATIENT

Lennon Petersen

SPECIES

Feline

BREED

Bengal

SEX

Spayed female

AGE

4 years

WEIGHT

7.1 lbs

INTERPRETED BY

Eric Lindquist, DMV
DABVP, Cert. IVUSS

IMAGING PERFORMED BY

Dr. Cochran

HOSPITAL NAME

Millis AH

REFERRING VET

Dr. Cochran

INVOICE

74955

DATE

4/28/26

Gastrointestinal

Examination of the **gastrointestinal tract** revealed a stomach and intestine free of stasis, of normal wall thickness, acceptable curvilinear mural detail, and peristaltic activity. Small and large intestine demonstrated normal luminal chyme and stool consistency respectively. No obstructive or overt infiltrative disease was noted. No associated abnormal lymphatic activity was noted.

Pancreas

The base and limbs of the **pancreas** were observed to be largely isoechoic to surrounding omental fat. Pancreatic duct and capsular contour were acceptably normal and parenchyma respected normal curvilinear patterns. No overt evidence of active inflammatory or neoplastic disease was noted.

ULTRASONOGRAPHIC FINDINGS

Swollen, irregular left kidney and splenomegaly. Nephritis, emerging round cell neoplasia and FIP are all potentials.

INTERPRETATION OF THE FINDINGS & FURTHER RECOMMENDATIONS

**Severe excessive file size noted at 7 GB, please assess with tech support.

FNA of the left renal cortex and spleen is indicated. There is concern for emerging round cell neoplasia or FIP. Full urinary work-up is warranted as well as palpation of the left kidney. Prognosis is guarded.

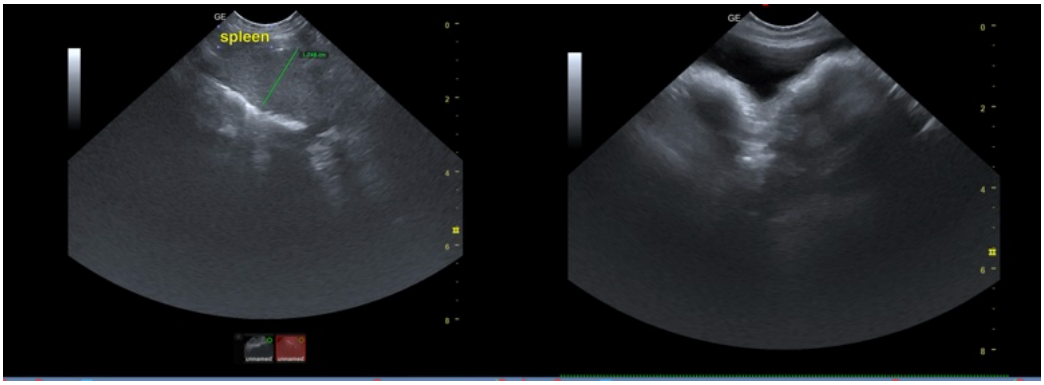

SonoPath
FOSTERING THE ART OF VETERINARY MEDICINE™

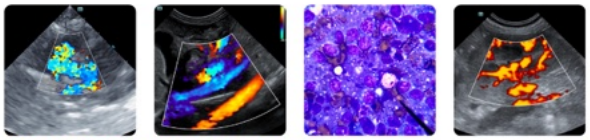

Clinical Sonography & Telecytology
Educational Teleconsultation Services™

SonoPath.com info@sonopath.com 1.800.838.4268

PATIENT

Lennon Petersen

SPECIES

Feline

BREED

Bengal

SEX

Spayed female

AGE

4 years

WEIGHT

7.1 lbs

INTERPRETED BY

Eric Lindquist, DMV
DABVP, Cert. IVUSS

IMAGING PERFORMED BY

Dr. Cochran

HOSPITAL NAME

Millis AH

REFERRING VET

Dr. Cochran

INVOICE

74955

DATE

4/28/26

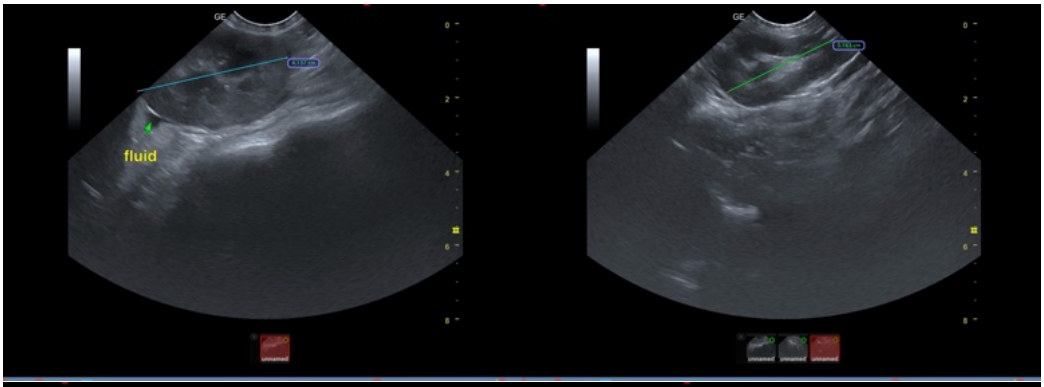

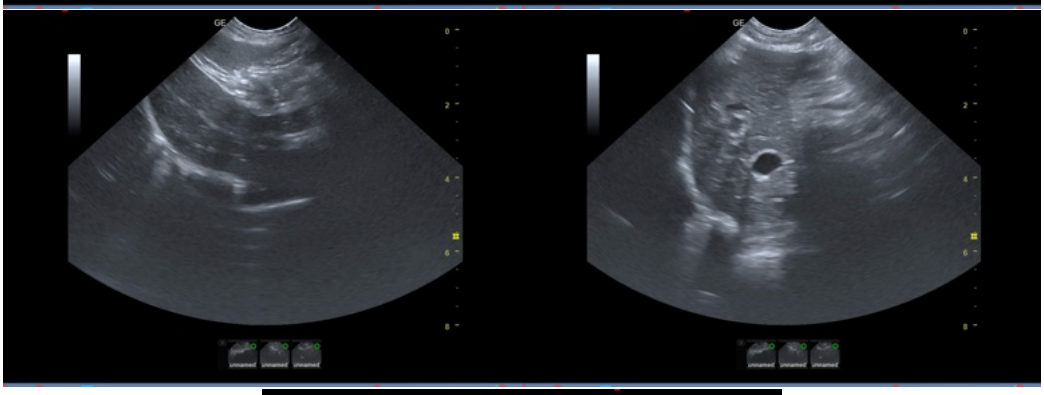

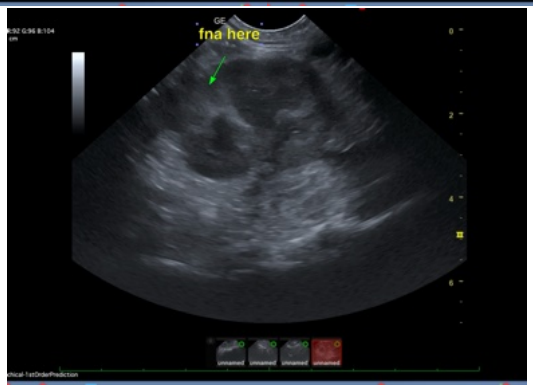

The information and recommendations provided are based on the images presented by the referring veterinarian/sonographer. No evaluation can be communicated regarding pathology that was not visible in the image/video clips provided.

Thank you for this referral. If the clinical or image interpretation does not parallel your findings or if I can be of any further assistance please contact me.

Eric Lindquist, DMV, DABVP (CFM), Cert. IVUSS, CEO of SonoPath.com

info@SonoPath.com